

Statins have been widely used because of their effect on lowering blood cholesterol and for having a well-established role in preventing cardiovascular and cerebrovascular events. They also has an immunomodulatory effect on the negative regulation of MHCII expression. There is a shift from Th1 (T helper cells) to Th2, which leads to the increase of B cells, activating the excessive production of antibodies, besides exerting an inhibitory effect on natural killer cells (NKs), which are crucial for natural immunity against intracellular pathogens, thus compromising immune vigilance against viral infections and predisposing to tumor cell proliferation.⁵

Hence, it is possible to infer that statins predispose to *Polyomaviridae* infection and the consequent proliferation of MCC tumor cells, a phenomenon similar as that occurring with the immunocompromised.

Because of the rarity of the tumor, there is currently no standard consensus for treatment. One recommendation is broad surgical excision with free margins of 2 cm and adjuvant or isolated radiotherapy.⁵

We report a case of MCC in an immunocompetent patient with a diagnosis below the average age of those diagnosed with MCC, with no history of other skin cancers, and a chronic statin user, thus strengthening the correlation between MCC and statin use.

Financial support

None declared.

Author's contributions

Isaura Azevedo Fasciani: Elaboration and writing of the manuscript.

Luisa Groba Bandeira: Obtaining, analyzing and interpreting the data; critical review of the manuscript.

Neusa Yuriko Sakai Valente: Approval of the final version of the manuscript; effective participation in research orientation; critical review of the literature; critical review of the manuscript.





Maria Fernanda Vieira Cunha Camargo: Conception and planning of the study; obtaining, analyzing and interpreting the data; critical review of the literature.

Conflicts of interest

None declared.

References

1. Albores-Saavedra J, Batich K, Chable-Montero F, Sagy N, Schwartz AM, Henson DE. Merkel cell carcinoma demographics, morphology, and survival based on 3870 cases: a population based study. *J Cutan Pathol.* 2010;37:20–7.
2. Dinh V, Feun L, Elgart G, Savaraj N. Merkel cell carcinomas. *Hematol Oncol Clin North Am.* 2007;21:527–44.
3. Czapiewski P, Biernat W. Merkel cell carcinoma – recent advances in the biology, diagnostics and treatment. *Int J Biochem Cell Biol.* 2014;53:536–46.
4. Sahi H, Koljonen V, Böhling T, Neuvonen PJ, Vainio H, Lamminpää A, et al. Increased incidence of Merkel cell carcinoma among younger statin users. *Cancer Epidemiol.* 2012;36:421–4.
5. Mascitelli L, Goldstein MR. Do the immunosuppressive effects of statins increase Merkel cell carcinoma risk? *Int J Dermatol.* 2014;53:e406–9.

Isaura Azevedo Fasciani ^{a,*}, Luisa Groba Bandeira ^a, Neusa Yuriko Sakai Valente ^{a,b}, Maria Fernanda Vieira Cunha Camargo ^a

^a *Department of Dermatology, Hospital do Servidor Público Estadual, Instituto de Assistência Médica ao Servidor Público Estadual, São Paulo, SP, Brazil*

^b *Department of Dermatopathology, Hospital do Servidor Público Estadual, Instituto de Assistência Médica ao Servidor Público Estadual, São Paulo, SP, Brazil*

* Corresponding author.

E-mail: isafasciani@hotmail.com (I.A. Fasciani).

Received 29 October 2018; accepted 14 January 2019; Available online 24 October 2019

<https://doi.org/10.1016/j.abd.2019.01.005>

0365-0596/ © 2019 Sociedade Brasileira de Dermatologia.

Published by Elsevier España, S.L.U. This is an open access article under the CC BY license (<http://creativecommons.org/licenses/by/4.0/>).

Millipede accident with unusual dermatological lesion^{☆,☆☆}

Dear Editor,

A 32-year-old male patient reported that, upon waking, he noticed injuries to his right leg, with local burning sensa-

tion and no other symptoms, and that he saw a millipede on the bed (Figs. 1–3). He went to the emergency room, where he was treated with antihistamines. Due to a lack of improvement, he sought a dermatologist. At the physical examination, the patient presented three spiral-shaped erythematous brownish spots, measuring approximately 3 cm each, located on the anterolateral surface of the right thigh. Clobetasol 0.05% ointment was prescribed, leading to an improvement of the burning sensation of the lesions.

Millipedes are animals of the phylum Arthropoda, the group with the largest number of invertebrate species. A member of the Diplopoda class, they have a cylindrical, segmented, rigid exoskeleton and two pairs of appendages or limbs (myriads) articulated in each segment, which move

[☆] How to cite this article: Pennini SN, Rebello PFB, Guerra MGVB, Talhari S. Millipede accident with unusual dermatological lesion. *Am Bras Dermatol.* 2019;94:765–7.

^{☆☆} Study conducted at the Fundação de Medicina Tropical Doutor Heitor Vieira Dourado, Universidade do Estado do Amazonas, Manaus, AM, Brazil.

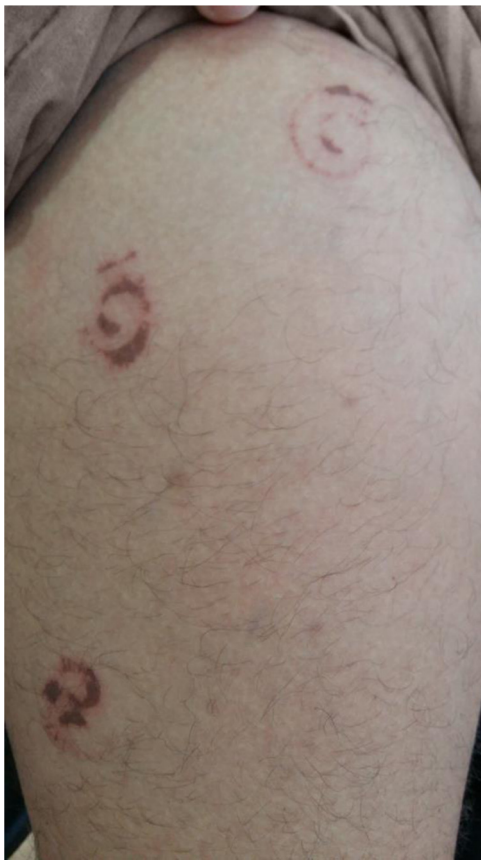

Figure 1 Spiral-shaped erythematous-brown spot on the right thigh.

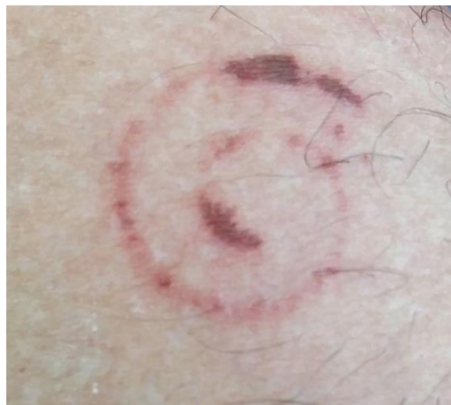

Figure 2 Detail of the lesion.



Figure 3 Millipede after curling.

symmetrically and slowly, unlike centipedes (Chilopoda), which have only one pair of limbs per segment for support and thrust, giving them faster movement.¹

Millipedes are nocturnal animals that inhabit dark and humid places, and have two defense mechanisms: spiral curling (with the head in the center), providing greater resistance to the exoskeleton, and the discharge of an irritating secretion, which flows from glands on the lateral portion of each body segment when the animal is under threat or being crushed. The secretion can also be ejected from a distance.^{2,3}

The species related to human accidents in Brazil, *Rhinocricus padbergi* (family Rhinocricidae), is a member of the Spirobolida order, whose secretion is mainly composed of benzoquinone (2-methyl-1,4-benzoquinone), a highly irritating compound.²

These are mostly harmless animals; however, when defending themselves, they can excrete toxins that cause irritating and pigmenting chemical reactions in the skin.^{3,4} Accidents with children and adults usually occur when they are unconscious, lying on the floor, or during contact with clothes and shoes, especially during the rainy season, when millipedes invade urban areas and houses in search of shelter in a dark place.⁵ Almost immediately after contact, there is numbness and a burning sensation on the skin.⁴ The affected site becomes erythematous, with initially brownish-yellow pigmentation, darkening after 24h and turning reddish-brown to black, with a cyanotic appearance, a coloration that may persist for several months.³ Depending on the amount of secretion and exposure time, the pigmented lesion may dry out and peel in approximately seven days, or there may be blistering that, upon rupture, leaves the surface eroded.²

Most case reports describe pigmented lesions without a definite shape resulting from crushing the millipede. The present case is particularly interesting because the lesions reproduced the body shape of the millipede, in the defensive position, as an impression of the animal on the skin, mirroring the position of the secretory glands.

Financial support

None declared.

Authors' contribution

Silmara Navarro Pennini: Conception and planning of the study; preparation and writing of the manuscript; intellectual participation in propaedeutic and/or therapeutic conduct of the studied case.

Paula Frassinetti Bessa Rebello: Preparation and writing of the manuscript; intellectual participation in propaedeutic and/or therapeutic conduct of studied cases; critical review of the literature.

Maria das Graças Vale Barbosa Guerra: Preparation and writing of the manuscript; critical review of the literature; critical revision of the manuscript.

Sinésio Talhari: Approval of the final version of the manuscript; participation in the study design and planning; critical revision of the manuscript.

Conflicts of interest

None declared.

References

1. De Capitani EM, Vieira RJ, Bucaretychi F, Fernandes LC, Toledo AS, Camargo AC. Human accidents involving *Rhinocricus* spp., a common millipede genus observed in urban areas of Brazil. *Clin Toxicol (Phila)*. 2011;49:187–90.
2. Haddad V Jr, Cardoso JLC, Rotta O, Eterovic A. Acidentes provocados por Millipede com manifestações dermatológicas: relato de dois casos. *An Bras Dermatol*. 2000;75:471–4.
3. Lima CA, Cardoso JL, Magela A, Oliveira FG, Talhari S, Haddad Junior V. Exogenous pigmentation in toes feigning ischemia of the extremities: a diagnostic challenge brought by arthropods of the Diplopoda Class (“millipedes”). *An Bras Dermatol*. 2010;85:391–2.
4. Radford AJ. Millipede burns in man. *Trop Geogr Med*. 1975;27:279–87.
5. Haddad V Jr, Cardoso JL, Lupi O, Tying SK. Tropical dermatology: venomous arthropods and human skin: Part II. Diplopoda Chilopoda, and Arachnida. *J Am Acad Dermatol*. 2012;67:347, e1–e9.

Silmara Navarro Pennini ^{ID a,b,*},
Paula Frassinetti Bessa Rebello ^{ID b},
Maria das Graças Vale Barbosa Guerra ^{ID a},
Sinésio Talhari ^{ID a}

^a Post-graduate Program in Tropical Medicine, Fundação de Medicina Tropical Dr. Heitor Vieira Dourado e Universidade do Estado do Amazonas, Manaus, AM, Brazil

^b Fundação de Dermatologia Tropical e Venereologia Alfredo da Matta, Manaus, AM, Brazil

*Corresponding author.

E-mail: pennini.sn@gmail.com (S.N. Pennini).

Received 7 March 2019; accepted 24 May 2019;

Available online 6 November 2019

<https://doi.org/10.1016/j.abd.2019.10.003>

0365-0596/ © 2019 Sociedade Brasileira de Dermatologia.

Published by Elsevier España, S.L.U. This is an open access article under the CC BY license (<http://creativecommons.org/licenses/by/4.0/>).

Primary diffuse cutaneous plasmacytoma: when a correct clinico-pathologic approach is mandatory for the patient's health ☆☆☆

Dear Editor,

A 76-year-old woman presented with multiple purplish plaques located on the arms (Fig. 1), deltoid region, elbows, wrist, mammary region, and legs. Lesions were painful at the touch without itching. Clinically, a diagnosis of eczema was suspected and a skin biopsy of the left arm was conducted.

Histological examination of hematoxylin & eosin-stained sections showed the presence of diffuse clusters of atypical oval-shaped cells with abundant cytoplasm, eccentric nuclei, “clock face” chromatin, and sometimes prominent nucleoli, infiltrating the medium and deep dermis (Fig. 2). Mitotic figures were seen. Neoplastic cells were morphologically similar to mature plasma cells, so a specific immunohistochemical panel was performed: they were diffusely positive for CD79a, CD138, CD56, MUM-1, and EMA, and totally negative for CD20. Immunohistochemical studies

for kappa and lambda light chains revealed a monoclonal expression of immunoglobulin kappa lights chains (Fig. 3).

To complete the diagnostic process, a bone marrow biopsy was performed; it was negative for multiple myeloma (MM) localization (less than 10% plasma cells; no clonal restriction). There were no Bence-Jones proteins in the urine. Hemogram and biochemical blood analysis revealed a normal value of hemoglobin and normal serum creatinine and calcium. Serum protein electrophoresis highlighted a lambda light chain spike.

Once the absence of other sites of disease was confirmed, a clinico-pathologic diagnosis of primary diffuse cutaneous plasmacytoma (PDCP) was rendered. Considering the extensive dissemination of the cutaneous involvement, the patient received systemic therapy. It consisted of bortezomib at the dosage of 1.3 mg/m² subcutaneously at day 1, 8, 15, and 22, melphalan given orally at the dosage of 14 mg at day 1, 2, 3, and 4, and dexamethasone at the dosage of 20 mg at day 1–2–8–9–15–16–22–23 (regimen). After nine cycles, fluorodeoxyglucose positron emission tomography-computed tomography showed complete disappearance of the skin lesions and absence of the lambda immunoglobulin G spike at the serum protein electrophoresis.

The patient completed therapy without adverse effects and, to date, after one year and eight months of follow-up, no recurrence of disease has been detected.

PDCP is a rare disease¹ that arises primarily in the skin, so it can be considered as a localized cutaneous extramedullary plasmacytoma (EMP) and should not be confused with secondary cutaneous plasmacytoma (SCP) in the context of MM.² According to a recent systematic review, only 68 cases of primary cutaneous plasmacytomas (PCPs) have been

☆ How to cite this article: Broggi G, Martino E, Calafiore V, Caltabiano R. Primary diffuse cutaneous plasmacytoma: when a correct clinico-pathologic approach is mandatory for the patient's health. *An Bras Dermatol*. 2019;94:767–9.

☆☆ Study conducted at the Azienda Ospedaliero-Universitaria Policlinico-Vittorio Emanuele, Catania, Italy.