

Expression of OPN3 in fibroblasts, melanocytes, and keratinocytes of skin with facial melasma in comparison with unaffected adjacent skin ^{☆,☆☆}



Dear Editor,

Melasma is a frequent acquired chronic dyschromia that affects photoexposed areas, especially in women of child-bearing age. Ultraviolet radiation (UVR) is the main environmental stimulus that induces melasma pigmentation; however, the role of visible light (VL: 400–700 nm) in its pathogenesis remains uncertain. VL comprises about 44% of solar radiation and promotes longer-lasting pigmentation (> 2 weeks) than UVA; however, only in higher phototypes (IV to VI).¹

Opsin-3, also known as encephalopsin or panopsin (OPN3), is a G-protein-coupled photoreceptor which promotes blue light-induced melanogenesis (420–490 nm). Opsins 1 to 5 have been described in the retina; however, OPN3 is the most often expressed form in the skin, which induces the phosphorylation of the microphthalmia-associated transcription factor (MITF) in melanocytes, resulting in tyrosinase activation.² To date, the differential expression of OPN3 in melasma skin compared to adjacent skin has not been investigated.

In the present study, after the Ethics Committee approval, 20 women with facial melasma (diagnosed clinically by an experienced dermatologist), without treatment for more than 30 days (except sunscreen) were submitted to two biopsies (3 mm): skin with melasma and unaffected adjacent skin (< 2 cm of distance).

The 40 specimens were submitted to triple-labeling immunofluorescence using primary antibodies and standardized dilutions: rabbit anti-OPN3 antibody (ab228748-Abcam, Cambridge-MA, USA) 1: 150; mouse anti-vimentin antibody (ab8978-Abcam, Cambridge-MA, USA) 1: 100, which is expressed in melanocytes and fibroblast intermediate filaments; and DAPI (4',6-Diamidino-2-Phenylindole), for cell nucleus labeling. Secondary antibodies (chromophores) and dilutions for OPN3: AlexaFluor 594 - 1: 500 (red); and, for vimentin: AlexaFluor 488 - 1: 500 (green). All reactions were tested against positive and negative controls.

Three areas showing greater immunolabeling in the microscopic slides in each topography (melasma and unaffected skin) were photographed using LEICA TCS-SP8 laser confocal microscopy. Using the red laser channel (OPN3 chromophore), guided by the colocalization of cytoplasmic green dots, and outside the nuclear blue colocalization, the average intensities of the image histograms (range 0 to 255)

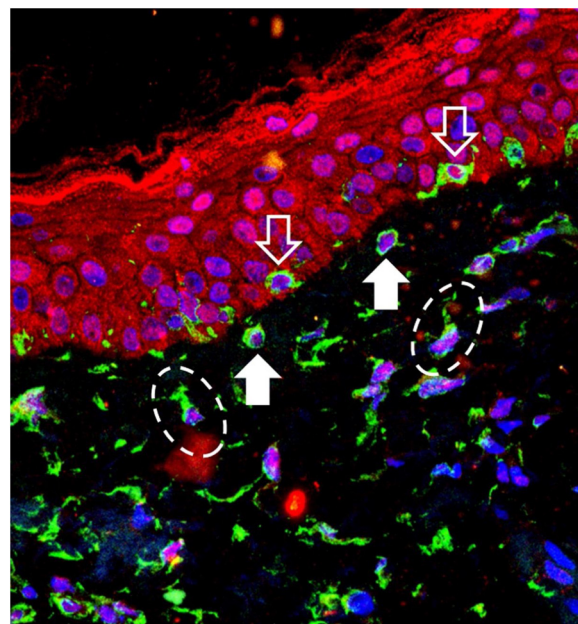


Figure 1 Overlapping image of triple-labeling immunofluorescence on skin with melasma. Labeling in green (vimentin), red (Opsin-3), blue (cell nuclei). White outline arrow: melanocytes in the basal layer. Full white arrow: pendulous melanocytes. Dashed ellipses: upper dermis fibroblasts.

Table 1 Evaluation of the mean expression (standard deviation) of OPN3 in the 20 participants, according to the topography and cell types evaluated.

	Melasma	Unaffected skin	p-value ^a
Suprabasal epidermis	30.4 (10.3)	33.9 (9.3)	0.170
Basal layer melanocytes	23.3 (9.6)	26.0 (7.9)	0.364
Pendulous melanocytes	23.7 (11.8)	22.3 (8.8)	0.652
Upper dermis fibroblasts	16.6 (10.2)	17.3 (6.7)	0.763

^a Bivariate comparison between topographies.

were estimated using the ImageJ software for the different cell types, blinded to the topography. The mean fluorescence intensity in each cell group was compared between the topographies by Student's *t*-test (dependent data). Cell counts between topographies were also estimated. A two-tailed p-value < 0.05 was considered significant.

OPN3 receptors were identified in all studied cells: keratinocytes, basal layer melanocytes, pendulous melanocytes, and upper dermis fibroblasts (Fig. 1). There was no differential expression in any cell group when comparing skin with melasma with the healthy adjacent skin (Table 1).

There was no difference in melanocyte and fibroblast count in the upper dermis using a high magnification field ($\times 400$) between the two topographies. However, the skin with melasma showed a higher density of pendulous melanocytes (Table 2).

[☆] How to cite this article: Espósito ACC, de Souza NP, Miot LDB, Miot HA. Expression of OPN3 in fibroblasts, melanocytes, and keratinocytes of skin with facial melasma in comparison with unaffected adjacent skin. An Bras Dermatol. 2021;96:367–9.

^{☆☆} Study conducted at the Departments of Dermatology and Pathology, Faculdade de Medicina de Botucatu, Universidade Estadual Paulista, Botucatu, SP, Brazil.

Table 2 Mean (standard deviation) cell counts (melanocytes, pendulous melanocytes, and fibroblasts) per high magnification field ($\times 400$).

	Melasma	Unaffected skin	p-value ^a
Basal layer melanocytes	3.2 (1.3)	3.6 (1.5)	0.451
Pendulous melanocytes	2.3 (0.9)	1.8 (0.7)	0.031
Fibroblasts of the upper dermis	4.5 (2.0)	4.4 (1.4)	0.915

^a Bivariate comparison between topographies.

The results of this study suggest that the expression of OPN3 does not justify the difference in skin pigmentation in melasma in comparison with the unaffected adjacent skin. If the VL plays an important role in its pathogenesis, it does not play it in relation to OPN3 expression. In fact, patients with facial melasma did not show any worsening of the lesions after exposure to the computer screen (8 h/day, 5 consecutive days), at a distance of 20 cm.³ Moreover, the expression of opsins (OPN 1 to 5) in the skin is known to differ according to the phototype.²

There is a synergistic effect between VL and UVR type A1 (UVA1: 340–400 nm). When individuals with phototype IV to V are irradiated with isolated VL, pigmentation occurs non-linearly with the irradiated dose. When UVA1 is associated with VL, there is more intense pigmentation and the response is directly proportional to the utilized dose.⁴ The synergism of VL and UVA1 in the differential pigmentation of melasma needs to be explored using specific experimental designs. The occurrence of OPN3 in human tissues outside the retina is called “non-visual” expression, whose functions are not yet fully understood. In the skin, in addition to the modulation of melanogenesis, it promotes differentiation of keratinocytes and the activation of metalloproteinases (MMP-1, -2, -3, and -9) by fibroblasts.² OPN3 can also be induced on the skin after blue light irradiation in scar tissue repair models, suggesting that it plays a role in skin healing.⁵

Pendulous melanocytes are basal layer melanocytes that protrude towards the upper dermis and are characteristic of skin with melasma, although they are found to a lesser extent in the adjacent photodamaged skin.⁶ Their pathophysiological importance is not clear, but their occurrence seems to be related to the increase in Metalloproteinase-2 and basement membrane fragmentation. Their greater numbers in the skin with melasma reinforces the role of UVR in the pathophysiology of the disease, since UVA promotes an inflammatory microenvironment in the upper dermis, with increased metalloproteinase activity (especially of MMP-2 and -9) and basement membrane degradation, which facilitates the protrusion of melanocytes towards the dermis.^{7,8}

This study has limitations related to the semi-quantitative *in situ* investigation technique, which does not identify different isoforms (splicing) of the photoreceptors or detects functional alterations of its pathway. There are other spindle cells in the upper dermis in addition to fibroblasts (e.g., CD4 + undifferentiated mesenchymal dendritic

cells) which, although less numerous, are not distinguishable by morphology or vimentin labeling. Also, the other opsins (OPN-1, -2, -4, and -5) were not assessed, although less expressed in normal skin.

In conclusion, there is no differential expression of OPN3 in keratinocytes, melanocytes, or fibroblasts in facial melasma when compared to the unaffected adjacent skin.

Financial support

FUNADERSP – *Fundo de Apoio à Dermatologia de São Paulo*.

Authors' contributions

Ana Cláudia Cavalcante Espósito: Participation in the design and planning of the study; collection, analysis, and interpretation of data; drafting of the manuscript; approval of the final version.

Nathália Pereira de Souza: Collection, analysis, and interpretation of data; critical review of the manuscript; approval of the final version.

Luciane Donida Bartoli Miot: Design and planning of the study; interpretation of data; critical review of the manuscript; approval of the final version.

Hélio Amante Miot: Participation in the design and planning of the study; analysis and interpretation of data; drafting of the manuscript; approval of the final version.

Conflicts of interest

None declared.

References

- Narla S, Kohli I, Hamzavi IH, Lim HW. Visible light in photodermatology. *Photochem Photobiol Sci*. 2020;19:99–104.
- Olinski LE, Lin EM, Oancea E. Illuminating insights into opsin 3 function in the skin. *Adv Biol Regul*. 2020;75:100668.
- Duteil L, Queille-Roussel C, Lacour JP, Montaudié H, Passeron T. Short-term exposure to blue light emitted by electronic devices does not worsen melasma. *J Am Acad Dermatol*. 2020;83:913–4.
- Kohli I, Chaowattanapanit S, Mohammad TF, Nicholson CL, Fatima S, Jacobsen G, et al. Synergistic effects of long-wavelength ultraviolet A1 and visible light on pigmentation and erythema. *Br J Dermatol*. 2018;178:1173–80.
- Castellano-Pellicena I, Uzunbajakava NE, Mignon C, Raafs B, Botchkarev VA, Thornton MJ. Does blue light restore human epidermal barrier function via activation of Opsin during cutaneous wound healing? *Lasers Surg Med*. 2019;51:370–82.
- Espósito ACC, Brianezi G, Souza NP, Santos DC, Miot LDB, Miot HA. Ultrastructural characterization of damage in the basement membrane of facial melasma. *Arch Dermatol Res*. 2020;312:223–7.
- Espósito ACC, Brianezi G, Souza NP, Miot LDB, Miot HA. Exploratory study of epidermis, basement membrane zone, upper dermis alterations and wnt pathway activation in melasma compared to adjacent and retroauricular skin. *Ann Dermatol*. 2020;32:101–8.

8. Espósito ACC, Brianezi G, de Souza NP, Miot LDB, Marques MEA, Miot HA. Exploring pathways for sustained melanogenesis in facial melasma: an immunofluorescence study. *Int J Cosmet Sci*. 2018;40:420–4.

Ana Cláudia Cavalcante Espósito *,
Nathália Pereira de Souza ,
Luciane Donida Bartoli Miot , Hélio Amante Miot 
Departments of Dermatology and Pathology, Faculty of
Medicine, Universidade Estadual Paulista, Botucatu, SP,
Brazil

* Corresponding author.

E-mail address: anaclaudiaesposito@gmail.com (A.C. Espósito).

Received 10 April 2020; accepted 15 May 2020
Available online 15 March 2021

<https://doi.org/10.1016/j.abd.2020.05.016>
0365-0596/ © 2021 Sociedade Brasileira de Dermatologia.
Published by Elsevier España, S.L.U. This is an open access article
under the CC BY license (<http://creativecommons.org/licenses/by/4.0/>).

Profile of pediatric patients with myiasis treated at a tertiary hospital in Rio de Janeiro^{☆,☆☆}



Dear Editor,

Myiasis is a dermatozoonosis, defined by the infestation of living animal tissues (mammals, birds, reptiles, and amphibians) by fly larvae, which can deposit their eggs in the natural orifices of their hosts, in skin continuity solutions or healthy skin, in furuncular myiasis. The larvae grow and feed on the host's tissue, causing severe pain and tissue destruction. This is a neglected disease, resulting from low socioeconomic conditions and the delay in seeking assistance.^{1,2} Surveys on the epidemiological profile of pediatric patients with myiasis are scarce in the literature.

This is an observational study carried out at Hospital Federal do Andaraí (HFA), in the city of Rio de Janeiro, State of Rio de Janeiro, Brazil, where patients aged up to 12 years with myiasis were selected and treated from 2007 to 2015. Socioeconomic and clinical data were collected from the patients' medical record, the larvae were extracted and identified according to taxonomic keys, in the Diptera Study Laboratory of the Federal University of the State of Rio de Janeiro – UNIRIO, as well as the adult insects preserved for around 10 days in sterile material.^{3,4} The study was approved by the UNIRIO Ethics Committee and the HFA Study Center.

A total of 69 patients were evaluated, aged less than or up to 12 years, in the studied period, representing about 19% of the 368 cases treated in all age groups. Most patients were females, 58 (84%), and 47 (68%) were dark-skinned. The family income was mostly up to 2 minimum wages and no head of the family had finished higher education. Only 48 (70%) had access to running water at home, 37 (54%) had access to regular garbage collection services and 41 (62%) had sanitary sewage collection system at the household, of which 18 (44%) had no access to a public sewage system and

disposed of the sewage into a nearby pit. Seven (10%) were in a situation of vulnerability (Table 1 and Fig. 1) and only 21 (30%) of the treated children were enrolled in school or day-care centers during the treatment period. The distribution by age group was balanced, with a mean age of 5.89 ± 3.38 years, with a lower prevalence in children under 1 year.

The cases originated mainly in the North region of the city of Rio de Janeiro, with 42 (61%) of the cases, with emphasis on the regions of great Tijuca and great Méier, which accounted for 22 (52%) of all cases in the North region of the city, the geographical area where the Andaraí Federal Hospital is located. In this same region, 4 (6%) lived in shelters or orphanages and 3 (4%) were homeless in neighborhoods adjacent to the hospital; one of these patient's entire family had lived for years in an abandoned milk factory. Two (3%) lived in the downtown region and 18 (26%) lived in Baixada Fluminense.

The scalp was the preferred site in 63 (91%) of the children. Among the predisposing factors and associated diseases, other dermatozoonoses represented by pediculosis and scabies, allergic dermatitis, and pyoderma were observed as the most prevalent ones (Table 1). The maximum number of larvae removed from a patient was 36 and the minimum was only one, with an average of 11.5 larvae per patient.

Cavitary or necrobiontophagous myiasis, those associated with pre-existing wounds and low socioeconomic status and poor hygiene conditions, were observed in 58 patients (91%), with *Cochliomyia hominivorax* being the most prevalent species, present in 56 (87%) patients, *Cochliomyia macel-*

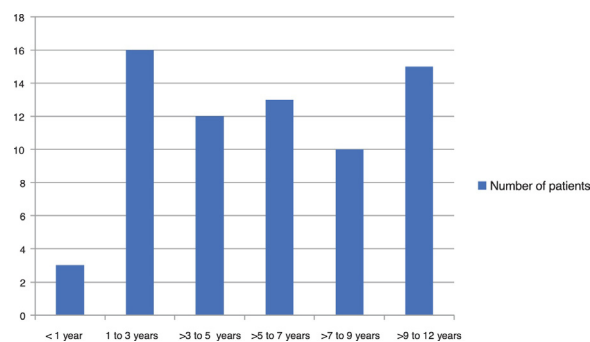


Figure 1 Distribution of myiasis cases in the pediatric population by age group, treated at Hospital Federal do Andaraí between 2007 and 2015.

[☆] How to cite this article: Rodrigues FT, D'Acari AM, Lessa CSS, Aguiar VM. Profile of pediatric patients with myiasis treated at a tertiary hospital in Rio de Janeiro. *An Bras Dermatol*. 2021;69:369–72.

^{☆☆} Study conducted at the Hospital Federal do Andaraí and Laboratório de Estudo de Dípteros da Universidade Federal do Estado do Rio de Janeiro, Rio de Janeiro, RJ, Brazil.