

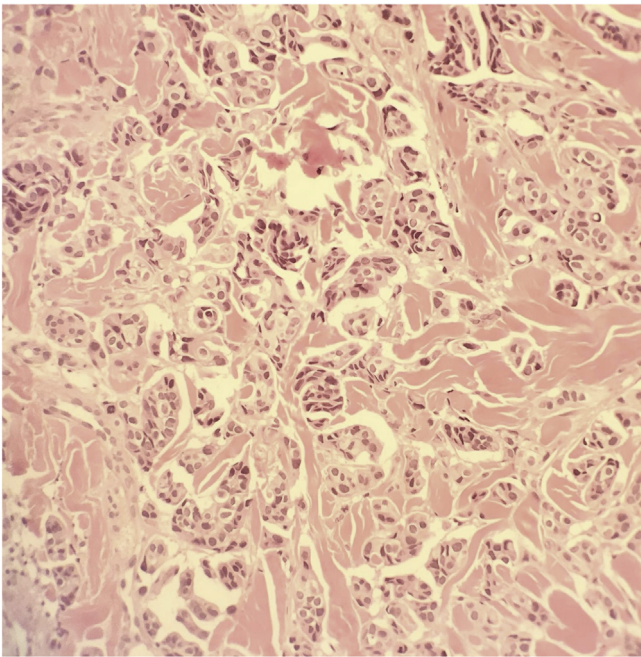Figure 2 Medium-sized tumor cells arranged in nests (Hematoxylin & eosin, $\times 400$).

Authors' contributions

Elisabeth Gómez-Moyano: Data curation; formal analysis; investigation; methodology; project administration; software; supervision; validation; visualization; roles/writing – original draft; writing – review.

Silvestre Martínez García: Formal analysis; investigation; methodology; project administration; software; supervision; validation; visualization; roles/writing – original draft; writing – review.

David Hernandez Alcaraz: Formal analysis; investigation; methodology; project administration; supervision validation; visualization; roles/writing – original draft; writing – review.





Maria Ayala-Blanca: Investigation; methodology; project administration; supervision; validation; visualization; roles/writing – original draft; writing – review.

Conflicts of interest

None declared.

References

1. Raghavan D. Cutaneous manifestations of genitourinary malignancy. *Semin Oncol.* 2016;43:347–52.
2. Giunchi F, Vasuri F, Valerio V, Montagnani I, Nelli F, Fiorentino M, et al. Unusual asymptomatic presentation of bladder cancer metastatic to the penis. *Pathol Res Pract.* 2017;213:717–20.
3. Kerkeni W, Ayari Y, Charfi L, Bouzouita A, Ayed H, Cherif M, et al. Transitional bladder cell carcinoma spreading to the skin. *Urol Case Rep.* 2017;11:17–8.
4. Abufaraj M, Foerster B, Schernhammer E, Moschini M, Kimura S, Hassler M, et al. Micropapillary urothelial carcinoma of the bladder: a systematic review and meta-analysis of disease characteristics and treatment outcomes. *Eur Urol.* 2019;75:649–58.
5. Thomaidou E, Armoni G, Klapholz L, Hadayer N, Maly A, Ramot R. Zosteriform cutaneous metastases. *Clin Exp Dermatol.* 2018;43:718–37.

Elisabeth Gómez-Moyano *,
Silvestre Martínez García , David Hernandez Alcaraz ,
Maria Ayala-Blanca 
Hospital Regional Universitario de Málaga, Málaga, Spain

* Corresponding author.

E-mail: elisabeth.gomez.moyano@gmail.com,
eligm80@hotmail.com (E. Gómez-Moyano).

Received 3 June 2020; accepted 23 June 2020

Available online 24 May 2021

<https://doi.org/10.1016/j.abd.2020.06.028>

0365-0596/ © 2021 Sociedade Brasileira de Dermatologia.

Published by Elsevier España, S.L.U. This is an open access article under the CC BY license

(<http://creativecommons.org/licenses/by/4.0/>).

Pemphigus vegetans developing after Mohs micrographic surgery and cryotherapy^{☆,☆☆}



Dear Editor,

Pemphigus vegetans (Pveg) is a subtype of pemphigus vulgaris (PV), characterized by flaccid blisters which become erosions and vegetating plaques, typically in the intertrig-

inous areas, face, and scalp.¹ Histologically it presents as pseudoepitheliomatous hyperplasia (PEH) associated with suprabasal acantholysis.

Trauma-induced pemphigus is rare following surgical procedures, with only a few reports occurring after Mohs micrographic surgery (MMS).^{2–5} Herein, a patient who developed Pveg after MMS for squamous cell carcinoma (SCC) of his chest and after cryosurgery for actinic keratosis (AKs) at his temple and forehead is presented. To the authors' knowledge, this is the first report of Pveg arising within either an MMS site or site treated by cryosurgery.

An 81-year-old caucasian male presented with several months of an erythematous hyperkeratotic nodule on the right anterior chest. Biopsy confirmed well-differentiated SCC and the patient underwent MMS for tumor removal. Concomitantly he was submitted to cryosurgery on his left temple and forehead for AKs. The postoperative course, initially unremarkable, was complicated by poor wound

[☆] How to cite this article: Jetter N, Cerci FB, Pandher K, Kronic AL. Pemphigus vegetans developing after Mohs micrographic surgery and cryotherapy. *An Bras Dermatol.* 2021;96:520–3.

^{☆☆} Study conducted at the Department of Dermatology, School of Medicine, Northwestern University Feinberg, Chicago, USA.

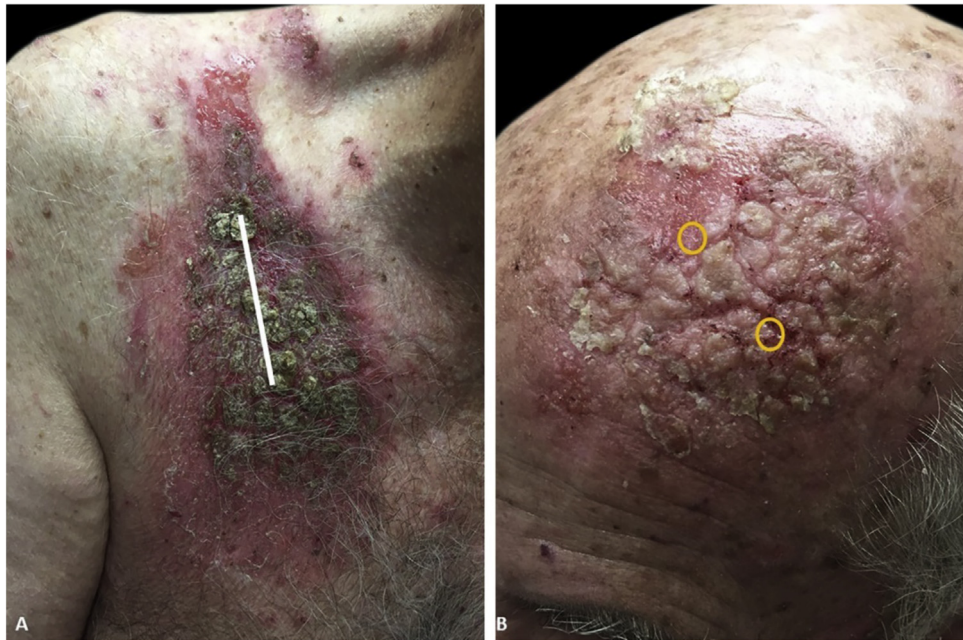

Figure 1 (A), Vegetative, hyperkeratotic, eroded plaques on the right chest (Mohs surgery site). The site of primary closure has been superimposed with a white line. (B), Left temple/forehead (cryosurgery site). Sites of original trauma have been superimposed with orange circles.

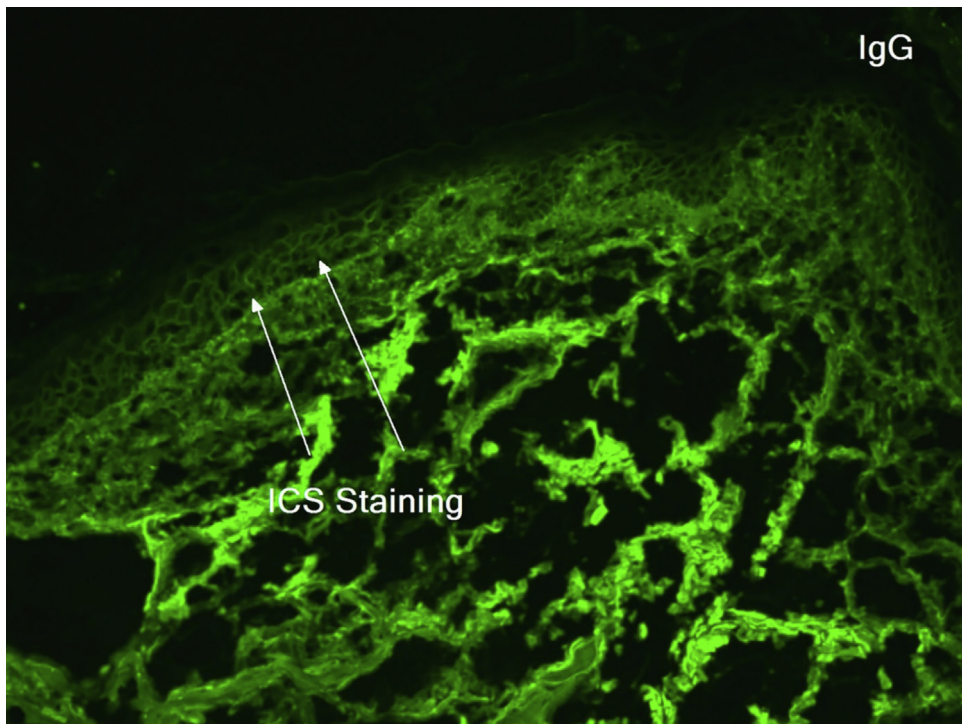


Figure 2 Direct immunofluorescence on skin biopsy demonstrating IgG fluorescence around keratinocytes (white arrows).

healing, oozing and discharge from the wound sites, as well as maceration at the periphery. Wound cultures grew *Pseudomonas aeruginosa*, but the patient failed to respond to systemic and topical antibiotics. Two months after MMS, the patient was noted to have erosions and hyperkeratotic vegetating plaques expanding circumferentially from

the procedure sites (Fig. 1). Biopsy from the chest demonstrated PEH and suprabasal acantholysis suggesting Pveg. Direct immunofluorescence showed deposits of IgG and C3 in the intercellular spaces of the epidermis, compatible with pemphigus (Fig. 2). Indirect immunofluorescence revealed autoantibodies against the epidermal cell surface at a titer

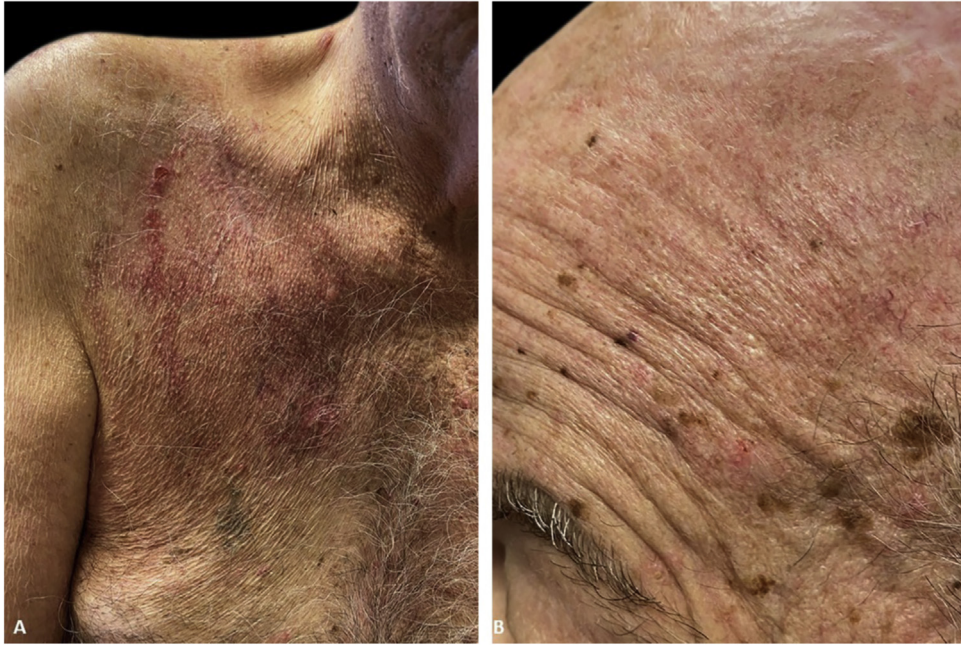

Figure 3 Complete healing 3 weeks after initiation of immunosuppressive therapy with residual erythema. A linear scar in the middle of the right chest can now be seen in the center.

of 1:40. ELISA showed anti-desmoglein (DSG) 1 antibody titer at 131.4 and anti-DSG3 antibody titer at 34.2 (>20 is positive for both).

The immunofluorescence and histopathology results along with the clinical presentation were consistent with Pveg. The patient was started on oral dexamethasone 0.15 mg/kg and azathioprine 150 mg daily and topical steroids, with complete resolution of the skin lesions in the due course (Fig. 3).

Trauma-induced PV has been described after major general surgical procedures (abdominal, chest, orthopedic) and dental procedures.¹ Out of 36 cases of surgically induced-PV, thirteen were in patients without pre-existing pemphigus. The literature review revealed only 2 cases of PV and 2 cases of PF occurring after MMS, and one case of PF after cryosurgery for AKs.²⁻⁵ In most cases of pemphigus following MMS, including this present case, the patients presented with unremarkable healing in the immediate postoperative period followed by the development of erosions, scaling, oozing, and desquamation after 4–5 weeks post-procedure simulating wound infection or contact dermatitis.^{2,4,5} All cases required a high index of suspicion with biopsy confirmation and immunofluorescence testing.

Several mechanisms have been proposed to explain the induction of pemphigus and Koebnerization of pre-existing pemphigus by surgical trauma, and the process is likely to be multifactorial.¹ Epidermal injury may expose DSG 1 and 3 and lead to new autoantibody formation in genetically susceptible patients or to activation of pre-existing antibodies already present in low (subclinical) titers.^{1,2,4} Furthermore, surgical trauma may link antigens not related to pemphigus but capable of immune response to pemphigus antigens through the process of epitope spreading.^{1,3} These factors could potentially explain the long latency period (15 weeks)

for pemphigus induction in non-dermatology surgery procedures where there is much less injury to the epidermis. With MMS, cryosurgery or shave biopsies there is more damage to the skin layers and at the dermo-epidermal junction, producing higher concentrations of released antigens (DSG 1 and 3) leading to more efficient epitope spreading and faster and stronger immunological response.^{1,3} Finally, SCC itself could develop an expression of DSG 1 and 3 and trigger an autoimmune response.

Pveg poses a further diagnostic challenge as it has histological similarities with SCC due to the presence of PEH. Besides being associated with suprabasal acantholysis, PEH in Pveg cases is of adnexal (follicular) origin, confined to the epidermis and dermis, with minimal atypia, rare mitoses, and absent individual keratinocyte necrosis.

In patients who have known bullous disease reconstruction of MMS wounds should be simple, and 2nd intention or partial closure should be considered.⁴ Some authors recommend increasing oral immunosuppression in the immediate postoperative period.⁵

In patients like ours who present without previous history of bullous disease, Pveg associated to the Mohs surgery and the criotherapy must have a high suspicion on the appearance of non-healing wounds or localized inflammation occurring several weeks after the procedure.

Financial support

None declared.

Authors' contributions

Nathan Jetter: Participation in the conception and planning of the study; obtaining, analyzing, and interpreting the data; writing; approval of its final version.

Felipe Bochnia Cerci: Analyzing and interpreting the data; writing; approval of its final version.

Karan Pandher: Participation in the conception and planning of the study; obtaining, analyzing, and interpreting the data; writing; approval of its final version.

Aleksandar L. Kronic: Participation in the conception and planning of the study; obtaining analyzing and interpreting the data; critical review of the manuscript; approval of its final version.

Conflicts of interest

None declared.

References

1. Daneshpazhooh M, Fatehnejad M, Rahbar Z, Balighi K, Ghandi N, Ghiasi M, et al. Trauma-induced pemphigus: a case series of 36 patients. *J Dtsch Dermatol Ges.* 2016;14:166–71.
2. Duick MG, Zaks B, Moy RL, Kaplan RP. Mohs micrographic surgery-induced pemphigus. *Dermatol Surg.* 2001;27:895–7.
3. Nazik H, Ozturk P, Mulayim M, Koyuncu E. Pemphigus vulgaris and koebner phenomenon. *Med Sci.* 2019;8:464–5.

4. Rotunda AM, Bhupathy AR, Dye R, Soriano TT. Pemphigus foliaceus masquerading as postoperative wound infection. *Dermatol Surg.* 2005;31:226–31.
5. Tolkachjov SN, Frith M, Cooper LD, Harmon CB. Pemphigus foliaceus demonstrating pathergy after mohs micrographic surgery. *Dermatol Surg.* 2018;44:1352–3.

Nathan Jetter ^a, Felipe Bochnia Cerci ^{b,*}, Karan Pandher ^c, Aleksandar L. Kronic ^d

^a Department of Dermatology, University of Illinois College of Medicine, Chicago, USA

^b Department of Dermatology, Hospital de Clínicas, Universidade Federal do Paraná, Curitiba, PR, Brazil

^c Chicago Medical School, Rosalind Franklin University, Chicago, USA

^d Department of Dermatology, School of Medicine, Northwestern University Feinberg, Chicago, USA

*Corresponding author.

E-mail: cercihc@hotmail.com, felipecerci@ufpr.br (F.B. Cerci).

Received 12 May 2020; accepted 3 July 2020

Available online 15 May 2021

<https://doi.org/10.1016/j.abd.2020.07.018>

0365-0596/ © 2021 Sociedade Brasileira de Dermatologia.

Published by Elsevier España, S.L.U. This is an open access article under the CC BY license

(<http://creativecommons.org/licenses/by/4.0/>).

Pemphigus vulgaris aggravated by obsessive-compulsive behavior: the importance of adjuvant topical occlusive dressing^{☆,☆☆}



Dear Editor,

Pemphigus vulgaris (PV) can be a difficult clinical diagnosis if mucosal involvement is not present. The occurrence of IgG4 anti-Dsg1 autoantibodies is associated with the pathogenesis of skin lesions and anti-Dsg3 with mucosal lesions. Serologically, the predominantly cutaneous presentation has circulating anti-Dsg1 and anti-Dsg3 autoantibodies, with a tendency to higher titers of anti-Dsg1 than anti-Dsg3, which implies a rare clinical phenotype of pemphigus vulgaris.¹

This is a case report of a 64-year-old male patient with a history of depression, type 2 diabetes mellitus, alcoholism,

and liver cirrhosis. He was referred, with a previous diagnosis of PV, due to difficulties in therapeutic management and with a suggestion for rituximab therapy. He had numerous ulcerated lesions, covered by hemato-meliceric crusts, predominantly on the face, pinna and cervical region (Fig. 1). No mucosal lesions were observed. Due to the exuberance of the condition with an atypical clinical presentation, new biopsies were performed, which confirmed the diagnosis of PV through histopathology and direct immunofluorescence. The clinical and laboratory investigation corroborated the aforementioned comorbidities. Serologies for hepatitis and HIV infection were negative. The patient had been using prednisone 0.85 mg/kg for two years without improvement.

During the hospitalization, a compulsive, daytime pattern of lesion manipulation was identified, which resulted in the exacerbation of the pre-existing lesions and the formation of crusts on them, which apparently justified the lack of response to treatment. After a psychiatric evaluation, sertraline 50 mg/day was started, together with psychotherapy, and dressing in polyhexamethylene biguanide (PHMB) gel, rayon and occlusion (Fig. 2). It was also decided to add azathioprine 150 mg/day and maintain the prednisone dose. There was an immediate and visible improvement after two days of the established therapy, and a significant improvement after 40 days (Fig. 3).

A follow-up study of patients with pemphigus (broad sense) found an incidence of depression 1.98 times more frequent than in the control group and 2.42 times higher

[☆] How to cite this article: Lima PB, Jorge MFS, Abbade LPF, Marques SA. Pemphigus vulgaris aggravated by obsessive-compulsive behavior: the importance of adjuvant topical occlusive dressing. *An Bras Dermatol.* 2021;96:523–5.

^{☆☆} Study conducted at the Faculdade de Medicina, Universidade Estadual Paulista, Botucatu, SP, Brazil.