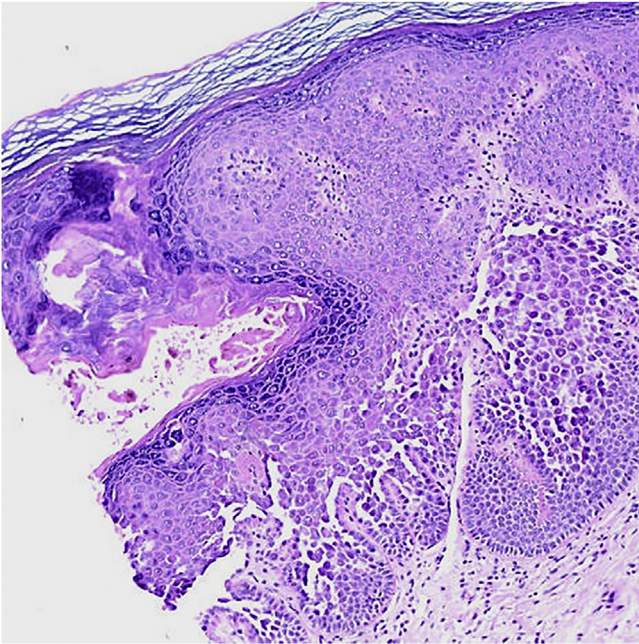

**Figure 3** Histopathological findings. Area of dyskeratosis, acantholysis and suprabasal clefts (Hematoxylin & eosin,  $\times 20$ ).

### Financial support

None declared.

### Authors' contributions

Laura Trujillo Ramirez: Drafting and editing of the manuscript; conception and planning of the study; intellectual participation in the propaedeutic and/or therapeutic conduct of the studied cases; participation in study design; critical review of the literature; critical review of the manuscript.

Camilo Andres Morales Cardona: Drafting and editing of the manuscript; conception and planning of the study; intellectual participation in the propaedeutic and/or therapeutic conduct of the studied cases; participation in study design; critical review of the literature; critical review of the manuscript.



Juan Carlos Hiromi Lopez Takegami: Drafting and editing of the manuscript; conception and planning of the study; intellectual participation in the propaedeutic and/or therapeutic conduct of the studied cases; participation in study design; critical review of the literature; critical review of the manuscript.

### Conflicts of interest

None declared.

### References

1. Díaz-Granados LM, Escobar C, Ospina JP. Lesiones pruriginosas en la vulva en una mujer 24 años. *Rev Asoc Colomb Dermatol.* 2015;23:153–5.
2. Yu WY, Ng E, Hale C, Hu S, Pomeranz MK. Papular acantholytic dyskeratosis of the vulva associated with familial Hailey-Hailey disease. *Clin Exp Dermatol.* 2016;41:628–31.
3. Lee HS, Kim YC. Papular acantholytic dyskeratosis of the inguinal area in a 49-year-old man. *Ann Dermatol.* 2017;29:363–4.
4. Ho J, Bhawan J. Mimickers of classic acantholytic diseases. *J Dermatol.* 2017;44:232–42.
5. Lipoff JB, Mudgil AV, Young S, Chu P, Cohen SR. Acantholytic dermatosis of the crural folds with ATP2C1 mutation is a possible variant of Hailey-Hailey disease. *J Cutan Med Surg.* 2009;13:151–4.

Laura Trujillo Ramirez  <sup>a,b,\*</sup>,  
Camilo Andres Morales Cardona  <sup>a,b</sup>,  
Juan Carlos Hiromi Lopez Takegami  <sup>a,b</sup>

<sup>a</sup> *Fundacion Universitaria Sanitas (Unisanitas), Bogotá, Colombia*

<sup>b</sup> *E.S.E. Hospital Universitario Centro Dermatologico Federico Lleras Acosta, Bogotá, Colombia*

\* Corresponding author.

E-mail: [lauratramirez89@gmail.com](mailto:lauratramirez89@gmail.com) (L. Trujillo Ramirez).

Received 3 December 2020; accepted 22 December 2020  
Available online 19 July 2022

<https://doi.org/10.1016/j.abd.2020.12.017>

0365-0596/ © 2022 Sociedade Brasileira de Dermatologia.

Published by Elsevier España, S.L.U. This is an open access article under the CC BY license (<http://creativecommons.org/licenses/by/4.0/>).

## Pemphigus vulgaris with exclusive manifestation in one of monozygotic twins: could environmental factors be involved? <sup>☆</sup>



Dear Editor,

Pemphigus vulgaris (PV) affects mainly the mucous membranes, through the production of autoantibodies against desmoglein (Dsg) 3. Anti-Dsg1 and anti-Dsg3 autoantibod-

ies are produced in the mucocutaneous form of the disease. The incidence of PV has been increasing in the northeastern region of the state of São Paulo, Brazil, an endemic region for pemphigus foliaceus (PF),<sup>1</sup> Susceptible/protective HLA alleles for PV,<sup>2</sup> agricultural activities, and, more recently, salivary proteins from insect bites<sup>3</sup> have been described in association with PV.

Reports of monozygotic twins affected by PV are rare<sup>4,5</sup> (Table 1). The present report describes the third case of monozygotic twin sisters, 43-years-old, of which only one developed PV. In September 2018, the twin with PV had multiple oral erosions (Fig. 1a). Direct Immunofluorescence (DIF) on the Tzanck smear showed fluorescence with anti-IgG on the keratinocytes cell membrane (Fig. 1b); the oral

<sup>☆</sup> Study conducted at the Department of Internal Medicine, Hospital das Clínicas, Faculty of Medicine, Universidade de São Paulo, São Paulo, SP, Brazil.

**Table 1** Clinical and laboratory data obtained from the literature on monozygotic twins presenting with pemphigus vulgaris.

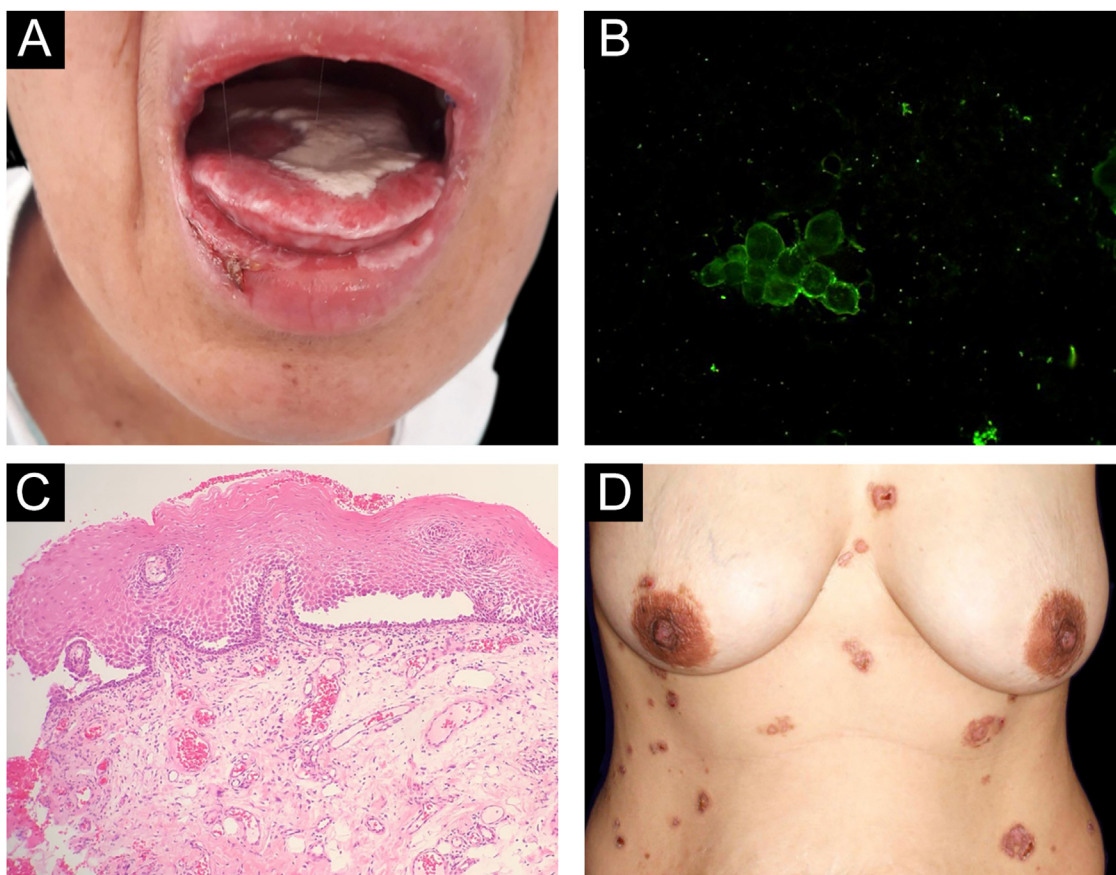
Reference		Clinical form of pemphigus vulgaris	Sex	Age (years)	IIF	Anti-Dsg1 (U/mL)	Anti-Dsg3 (U/mL)	HLA Alleles/haplotypes <sup>c</sup>
Ruocco et al. (1985) <sup>4</sup> Italy	Twin 1	Mucocutaneous	Female	11½	1:40	ND	ND	<u>A*24</u> , <u>A*29</u> ; <u>B*45</u> , <u>B*35</u> ; <u>C*04</u> , <u>C*x</u> ; <u>DRB1*04</u> , <u>DRB1*07</u>
Salathiel et al. (2016) <sup>5</sup> Brazil	Twin 2	Not affected <sup>a</sup>		NA	1:20	ND	ND	
	Twin 1	Mucocutaneous	Female	11	IgG	120.77	160.82	<u>DRB1*04:02</u> - <u>DQA1*03:01</u> - <u>DQB1*03:02</u>
	Twin 2			16	IgG	74.02	151.66	<u>DRB1*14:04</u> - <u>DQA1*01:01</u> - <u>DQB1*05:03</u>
Farid et al. (2021)	Twin 1	Mucocutaneous	Female	43	IgG	2.0±	189.1	<u>DRB1*08:04</u> , <u>DRB1*14:01</u> ; <u>DQA1*01:01</u> , <u>DQA1*05:01</u> ; <u>DQB1*03:01</u> <sup>+</sup> , <u>DQB1*05:01</u> <sup>++</sup>
Brazil (current)	Twin 2	Not affected <sup>b</sup>		NA	IgG	1.6	0.7	

IIF, Indirect immunofluorescence; Dsg, Desmoglein; ND, Not determined; NA, Not affected.

<sup>a</sup> At 23 years old.

<sup>b</sup> At 45 years old; ± anti-Dsg1 titer when the patient had exclusive oral lesions.

<sup>c</sup> PV susceptibility alleles are underlined; resistance + and susceptibility++ alleles to pemphigus foliaceus (see Ref. <sup>2</sup>).



**Figure 1** (A), Lesions on the oral mucosa: erosions on the tongue covered by a whitish pseudomembrane, erosions on the labial mucosa, erosions and crusts on the lower lip. (B), Direct immunofluorescence on oral Tzanck smear cytology: fluorescence with anti-IgG on the keratinocytes cell membrane. (C), Histopathology of the oral mucosa (Hematoxylin & eosin, ×40): acantholytic suprabasal bulla. (D), Skin lesions: erythematous plaques on the abdomen and chest with bullae, erosions and hematic crusts.

mucosal biopsy demonstrated acantholytic suprabasal bullae (Fig. 1c). Multinucleated keratinocytes suggestive of HSV infection were also observed in the Tzanck smear. DIF on the skin biopsy and indirect immunofluorescence (IIF) with normal skin substrate presented fluorescence with anti-IgG on the keratinocytes cell membrane. Prednisone 40mg/day, dapsone 50mg/day, and folic acid 5mg/day were prescribed. After a few days, lesions appeared on the abdomen, anterior chest region, and back (Fig. 1d), with the presence of Nikolsky sign. Biopsy of the lesion on the back showed the presence of an acantholytic suprabasal bulla on histopathology, and interkeratinocyte fluorescence for IgG and C3 on DIF. After eight months of treatment, dapsone was replaced by cyclophosphamide at 50 mg/day. In March 2020, the patient suspended the medication due to the coronavirus pandemic. In June 2020, the oral lesions recurred and prednisone was restarted.

When the patient had exclusive mucosal lesions, the ELISA test resulted in anti-Dsg1 2.0 U/mL and anti-Dsg3 189.1 U/mL (MBL, Japan, cutoff of 20 U/mL for both), while her sister showed negative values on ELISA (1.6 U/mL and 0.7 U/mL, respectively) and IIF.

Both sisters had two HLA susceptibility alleles for PV: *HLA-DRB1\*08:04* and *HLA-DRB1\*14:01*, while the *HLA-DQA1* alleles were not associated with PV.<sup>2</sup> Moreover, they had two other alleles, *HLA-DQB1\*03:01*, and *HLA-DQB1\*05:01*, which have been described in association with resistance and susceptibility to PF, respectively<sup>2</sup> (Table 1).

Two years later, only one of the twins had PV. Although they had an identical HLA profile, they had not been exposed to similar environmental factors. Both lived in a region prevalent for PV,<sup>1</sup> in the northeastern region of the state of São Paulo, Brazil. However, the affected sister had worked in rural activities, on a chicken farm, for 10 years, while her unaffected twin sister reported having always worked in the urban area. Rural workers are more exposed to pesticides, as well as to another possible PV trigger – blood-sucking insect bites.<sup>3</sup>

When evaluating the HLA profile and environmental factors in PV triggering, one can detect, in advance, those individuals who are most likely to develop the disease. And the question arises whether by modifying the contributing factors, whenever possible, one could prevent the emergence of PV.

In conclusion, the genotype-environmental factor interactions need to be further explored in the pathogenesis of pemphigus, and the present report illustrates this scenario.

## Financial support

This work was partially supported by FAPESP (*Fundação de Amparo à Pesquisa do Estado de São Paulo*; #2010/51729-2) and FAEPA (*Fundação de Apoio ao Ensino, Pesquisa e Assistência*).

## Authors' contributions

Marcela Rosa de Almeida Farid: Approval of the final version of the manuscript; design and planning of the study; drafting and editing of the manuscript; collection, analysis, and interpretation of data; critical review of the literature.

Roberto Bueno-Filho: Approval of the final version of the manuscript; collection, analysis, and interpretation of data;

intellectual participation in the propaedeutic and/or therapeutic conduct of the studied cases; critical review of the manuscript.

Eduardo Antônio Donadi: Approval of the final version of the manuscript; collection, analysis, and interpretation of data; critical review of the manuscript.

Ana Maria Roselino: Approval of the final version of the manuscript; design and planning of the study; drafting and editing of the manuscript; collection, analysis, and interpretation of data; effective participation in research orientation; intellectual participation in the propaedeutic and/or therapeutic conduct of the studied cases; critical review of the literature; critical review of the manuscript.

## Conflicts of interest


None declared.

## Acknowledgments

The authors would like to thank Dr. Leticia Arruda Camargo and Tamiris Amanda Julio, PhD, for their contribution in the preparation of the clinical case and in the assessment of anti-desmogleins by ELISA, respectively.

## References

1. Celere BS, Vernal S, Brochado MJF, Segura-Muñoz SI, Roselino AM. Geographical foci and epidemiological changes of pemphigus vulgaris in four decades in Southeastern Brazil. *Int J Dermatol.* 2017;56:1494–6.
2. Brochado MJ, Nascimento DF, Campos W, Deghaide NHS, Donadi EA, Roselino AM. Differential HLA class I and class II associations in pemphigus foliaceus and pemphigus vulgaris patients from a prevalent Southeastern Brazilian region. *J Autoimmun.* 2016;72:19–24.
3. Wambier CG, Struecker TA, Durski LN, Araújo AG, Wambier SP, Cappel MA, et al. Image Gallery: A case of pemphigus vulgaris following *Simulium* spp. (Diptera) bites. *Br J Dermatol.* 2017;176:e100.
4. Ruocco V, Peluso G, Pisani M. Pemphigus vulgaris in only one of two monozygotic twins. *J Am Acad Dermatol.* 1985;12:587–9.
5. Salathiel AM, Brochado MJ, Kim O, Deghaide NHS, Donadi EA, Roselino AM. Family study of monozygotic twins affected by pemphigus vulgaris. *Hum Immunol.* 2016;77:600–4.

Marcela Rosa de Almeida Farid ,  
Roberto Bueno-Filho , Eduardo Antônio Donadi ,  
Ana Maria Roselino \*

*Department of Internal Medicine, Hospital das Clínicas, Faculty of Medicine, Universidade de São Paulo, São Paulo, SP, Brazil*

\* Corresponding author.

E-mail: [amfrosel@fmrp.usp.br](mailto:amfrosel@fmrp.usp.br) (A.M. Roselino).

Received 9 January 2021; accepted 6 April 2021

Available online 9 July 2022

<https://doi.org/10.1016/j.abd.2021.04.017>

0365-0596/ © 2022 Sociedade Brasileira de Dermatologia.

Published by Elsevier España, S.L.U. This is an open access article under the CC BY license (<http://creativecommons.org/licenses/by/4.0/>).