

# Description of a new method of ovariectomy in female rats

Deepak Kumar Khajuria<sup>1</sup>, Rema Razdan<sup>2</sup>, D Roy Mahapatra<sup>3</sup>

## ABSTRACT

Rats are currently the most used laboratory animals to investigate osteoporosis. We report an efficient method of ovariectomy and compared this method with the two other operative methods of ovariectomy (i.e., midline dorsal skin incision and double dorsolateral approach, which are used commonly for inducing experimental osteoporosis. Female Wistar rats, 12 weeks old, were divided into three groups. Ovariectomy was preceded by a single midline dorsal skin incision, 3 cm long, in the group A; double dorsolateral incisions, approximately 1 cm long, in the group B; and a single ventral transverse incision of 0.4–0.6 cm at the middle abdominal region in the group C. Animals in groups A, B, and C had a mean weight of  $258.12 \pm 0.54$  g,  $255.78 \pm 0.42$  g, and  $254.55 \pm 1.69$  g, respectively. There were significant differences in the duration (in minutes) of surgery in the groups B ( $9.65 \pm 0.86$ ) and C ( $7.55 \pm 0.11$ ,  $P < 0.001$ ) when compared to the group A ( $15.52 \pm 0.30$ ) and in the group B ( $P < 0.01$ ) when compared to the group C. Wound healing time (in days) for groups B ( $9.22 \pm 0.67$ ) and C ( $8.01 \pm 0.93$ ) was significantly shorter than that for group A ( $11.58 \pm 1.2$ ,  $P < 0.001$ ), with the wound healing time for group C being slightly shorter than that for group B. The surgery, as conducted in the group C, was technically easier, less time consuming and showed less wound healing duration.

**Keywords:** ovariectomy, postmenopausal osteoporosis, animal models.

© 2012 Elsevier Editora Ltda. All rights reserved.

## INTRODUCTION

The understanding of postmenopausal osteoporosis is hindered by the difficulty of studying a disease that is restricted to humans. Therefore, the use of an animal model of postmenopausal osteoporosis provides more uniform experimental material and allows for assessment of potential therapies for it.<sup>1</sup> For the study of postmenopausal osteoporosis, the use of an animal model will reduce the problems which are associated with studying the disease in humans, such as time and variability in the behavior of test subjects. Even clinical studies are highly expensive and require longer durations, which is one more reason that explains why animal models play an important role in understanding the osteoporosis research. In the United States, for the preclinical evaluation of new drugs, the Food and Drug Administration (FDA) requires data from animal models.<sup>2</sup>

The most commonly used animals to investigate osteoporosis are rats because they are inexpensive, easy to house, grow rapidly, widely available and the general public is accustomed to the role of rodents for use in research.<sup>3</sup> Ovariectomy in female rats can be performed in different ways and the selection of the operative method for ovariectomy is very important, especially when the number of animals is very high and the duration of the experiment is short. There are mainly two types of incision used for doing ovariectomy in female rats: single midline dorsal skin incision<sup>4</sup> and double dorsolateral incisions.<sup>5</sup>

In this study we focused on creating a minimally invasive method of ovariectomy which can be useful to veterinarians in private practice or in research facilities, as a model for inducing experimental postmenopausal osteoporosis in female rats. We also compared our novel and efficient method of ovariectomy with other reported methods for this surgery in terms of duration

Received on 07/26/2011. Approved on 03/05/2012. The authors declare no conflict of interest. Ethics Committee: Institutional Animal Ethics Committee (IAEC) of Al-Ameen College of Pharmacy.

Department of Pharmacology, Al-Ameen College of Pharmacy.

1. Master in Pharmacy, Research Scholar, Department of Pharmacology, Al-Ameen College of Pharmacy

2. PhD; Professor, Department of Pharmacology, Al-Ameen College of Pharmacy

3. PhD; Assistant Professor, Laboratory for Integrative Multiscale Engineering Materials and Systems, Department of Aerospace Engineering, Indian Institute of Science  
Correspondence to: Deepak Kumar Khajuria. Al-Ameen College of Pharmacy. Department of Pharmacology. Hosur Road, Bangalore, 560027. E-mail: deepak\_kumarkhajuria@yahoo.co.in

of the operative procedure, degree of difficulty of the operative technique and access to gonads and duration of wound healing.

## MATERIALS AND METHODS

### Animals

Twenty-four healthy in-house laboratory-bred Wistar rats with 12 weeks age were included for the study. The animals were maintained under controlled temperature at  $25\text{ }^{\circ}\text{C} \pm 2\text{ }^{\circ}\text{C}$  with 12-hour light/dark cycle. They were fed standard laboratory diet (Amrut rat and mice feed, Pranav Agro Industries Ltd., Sangli, India) and water *ad libitum*. Before conducting the experiment, ethical clearance was obtained from the Institutional Animal Ethics Committee (IAEC) of Al-Ameen College of Pharmacy, Bangalore.

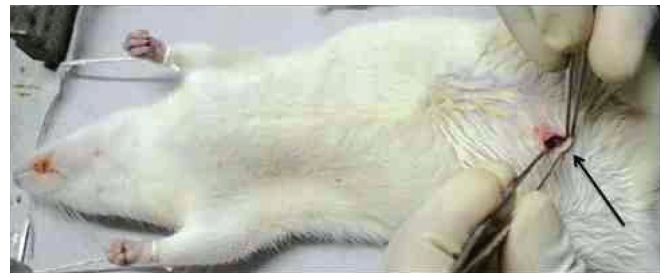### Surgical procedure: ovariectomy

Prior to the surgery the weight of the animals was measured by a digital weighing machine. Female Wistar rats were divided into three groups consisting of eight animals each. The animals were anesthetized with a combination of ketamine (80 mg/kg) and xylazine (10 mg/kg), intraperitoneally (Neon Pharma, Mumbai and Indian Immunologicals Ltd., Hyderabad, respectively).<sup>6</sup>

In the group A, ovariectomy was preceded by a midline dorsal skin incision, 3-cm long, approximately halfway between the middle of the back and the base of the tail according to the method described by Lasota et al.<sup>4</sup> In the group B, ovariectomy was made by two dorsolateral incisions; one small incision (1.5 cm) was made through the skin and the muscle wall on each side of the backbone, in the dorsal aspect according to the method described by Park et al.<sup>5</sup> In the group C, operation was made after placing an anesthetized animal on its dorsal surface. The fur on the rat abdomen was completely removed with depilatory cream (Veet, Reckitt Benckiser, India).

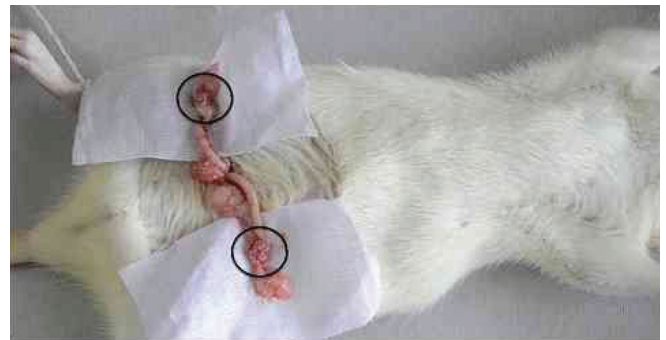The area of surgery was cleaned with ethanol (Merck, India). A small transverse peritoneal incision of 0.4–0.6 cm was made with surgical scalpel blade no. 11 on the middle part of the abdomen slightly towards right, just near to the second right nipple of the rat, as shown in Figure 1. After peritoneal cavity was accessed, the adipose tissue was pulled away until the right uterine tube and the ovary surrounded by a variable amount of fat were identified. The ovary and associated fat were easily located and exteriorized by gentle retraction. The procedure was repeated for the left ovary through the same incision, as shown in Figure 2. The periovarian fat with the ovary was pulled away from the incision site gently to prevent detachment of a small piece of ovary, which may fall into the abdominal cavity where it may be reimplanted and carry on its normal function.<sup>7</sup> After identifying the ovary and

uterine horn, a braided silk suture (Ethicon mersilk sutures-3/0, Johnson & Johnson Ltd., India) was performed around the area of the distal uterine horns, that was sectioned thereafter, and the ovaries were removed, as shown in Figure 3.



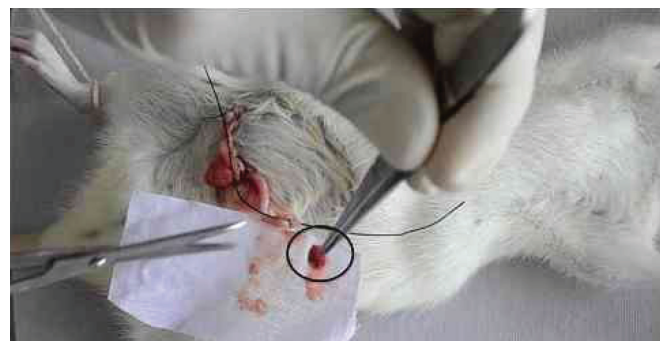**Figure 1**

Transverse incision made on the middle part of abdomen slightly towards the right with a surgical scalpel blade. The transverse abdominal muscle is exposed after skin incision.



**Figure 2**

After the muscle dissection, the peritoneal space and adipose tissue surrounding ovary are exposed. Thick black circles show the ovary surrounded by adipose tissue.



**Figure 3**

Ligation at the distal uterine horn in order to completely remove the ovary, one at a time. The ovary surrounded by fat is completely removed (thick black circle).

The uterine horn was returned to the peritoneal cavity after the removal of ovaries. The wound was closed in two layers (muscle and skin) using sterile sutures. The peritoneum and the muscle layers were sutured with one absorbable suture (Ethicon chromic sutures-3/0, Johnson & Johnson Ltd., India) and the skin was sutured with one non-absorbable suture (Ethicon mersilk sutures-3/0, Johnson & Johnson Ltd., India). Povidone iodine was applied on the area to disinfect the skin after suturing. High degree of aseptic procedure was maintained throughout the operation.

After surgery, the rats were housed individually in polyurethane boxes for a period of one week to allow recovery and then re-grouped in their home cages. There was also some concern that the ventral approach in rodents means that the wound was in an almost constant direct contact with the paddy husk bedding, which may result in more frequent wound breakdowns. In order to prevent this, the animals after surgery were housed individually in polyurethane boxes provided with clean and dry bedding sets made of 100% sterilized cotton fabric for extra comfort and warmth for a period of one week in order to avoid hypothermia and to prevent possible contamination.

### Evaluation of wound healing

To evaluate wound healing, duration of healing, absolute and normalized length area of the wound were used. The maximum length area was measured on the second day after surgery. Thereafter, this measurement was carried out every two days until full healing occurred. The healing percentage or the normalized values were calculated by dividing the maximum length of the wounds by that measured on the second day after surgery. The duration of wound healing was the time taken for full contraction of the wound. Wound healing percentage was calculated using the equation  $[(L_2 - L_1) / L_2 \times 100]$ , where  $L_2$  and  $L_1$  are the maximum wound lengths on the second and any other day, respectively.<sup>8</sup>

### Statistical analysis

Results are given as mean ± SEM. One-way Analysis of Variance (ANOVA) followed by Bonferroni's test did the comparisons between different groups. In all cases, a probability error of less than 0.05 was selected as the criterion for statistical significance.

## RESULTS

### Mortality rate

There was no procedure-related death reported in the group B. However, two animals from group A and one animal from group B died within two days after surgery. Any procedure that causes

pain in humans is assumed to cause pain in animals. Also, it is well known that surgical procedures often cause painful tissue damage. However, for larger incisions which need more sutures, such as in case of groups A and B, rats often have an inflammatory reaction to the absorbable sutures. Moreover, it takes too long to apply the sutures. This might be the reason of increased mortality rate of animals in groups A and B. Well-established studies have shown repeatedly that small transverse abdominal incisions enhance locomotion, increase appetite, and reduce the time of postoperative recovery for humans, rodents, and rabbits, which are particularly sensitive to pain and inflammation.

### Body weight

Before operation, there was no significant difference in the rat's body weight between groups. Table 1 summarizes the effects of ovariectomy on body weight in all groups. There was no significant difference in the body weight of animals after surgery in all three groups.

### Surgery duration

The surgery duration in group C ( $7.55 \pm 0.11$  min) was found to be significantly less than in groups A ( $15.52 \pm 0.30$  min,  $P < 0.001$ ) and B ( $9.65 \pm 0.86$  min,  $P < 0.01$ ), as shown in Table 1. Also in group B, the surgery duration was significantly lower when compared with group A ( $P < 0.001$ ).

### Wound healing time

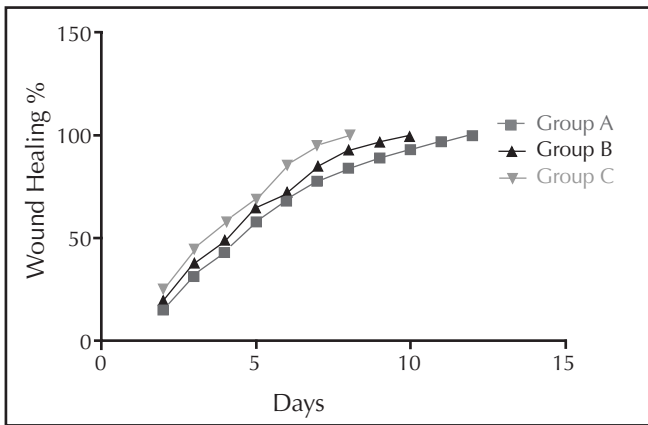
The wound healing time of groups B ( $9.22 \pm 0.67$  days) and C ( $8.01 \pm 0.93$  days) was significantly shorter than those of group A ( $11.58 \pm 1.2$  days,  $P < 0.001$ ), as shown in Table 1.

**Table 1**

Comparison of different surgical procedures of ovariectomy in rats

Groups	Incision	Body weight	Surgery duration (min)	Wound healing time (days)
Group A (n = 8)	Single midline dorsal, 3 cm long	258.12 ± 0.54	15.52 ± 0.30	11.58 ± 1.2
Group B (n = 8)	Two dorso-lateral, each 1.5 cm long	255.78 ± 0.42	9.65 ± 0.86*	9.22 ± 0.67*
Group C (n = 8)	Abdominal transverse, 0.4–0.6 cm long	254.55 ± 1.69	7.55 ± 0.11**	8.01 ± 0.93*

Data are shown as mean ± SEM (n = 6), evaluated by Bonferroni's test. All values are mean ± SEM, n = 8. \*Significantly statistical comparison with group A ( $P < 0.001$ ); \*\*Significantly statistical comparison with group B ( $P < 0.01$ ).



**Figure 4**  
Wound healing percentage per day in groups A, B, and C.

However, we observed no significant difference in the wound healing time of group C when compared with group B. The distributions of wound length and healing percentage per day showed significant variation between groups A and C. The variation of the wound length was different among all three groups (Figure 4).

## DISCUSSION

Rodents are the most commonly used animal model for osteoporosis studies, because after ovariectomy female rat skeleton is more sensitive to the loss of ovarian hormones and exhibit most of the characteristics of human postmenopausal osteoporosis. Therefore, for the preliminary evaluation of a new pharmacological agent which might be effective in postmenopausal osteoporosis, rodents are generally the species of first choice, followed by verification in other species before undertaking clinical trials in human patients. However, the procedure for creating an efficient method of ovariectomy in female rats has not been reported in the published literature so far, to the best of our knowledge. Thus, in this article we describe a novel approach for creating a minimal invasive ovariectomy. We also compared our method with two other methods of ovariectomy which had been reported earlier (i.e., single midline dorsal skin incision and double dorsolateral approach).

Before making an abdominal incision, the surgeon needs to consider multiple factors such as the area that needs to be exposed, operative exposure, simplicity, and the need for quick

entry into the abdominal cavity. The most important factor is an adequate exposure to the operative field. Complications during surgery can occur because of inadequate exposure, which is often due to the unwillingness of the surgeon to extend the incision. In this study, the duration of surgery in group C (ventral transverse incision, 0.4–0.6 cm long) was found to be significantly less than in groups A (single midline dorsal skin incision, 3 cm long) and B (double dorsolateral incisions, each 1.5 cm long).

A careful selection of the incision site and the proper closure of the wound after an abdominal incision are very important for the surgery success.<sup>9</sup> The type of the incision may however have its influence on the occurrence of postoperative wound complications. The small transverse incision at the abdominal region is based on better anatomical and physiological principles. Reported advantages of transverse incisions for abdominal surgery include better cosmetic results, less pain, and low incidence of hernia formation.<sup>10</sup>

The wound healing time of group C was significantly shorter than those of group A. No significant difference in the wound healing time of group C was observed when compared with group B, although the healing time of wounds in group C was lower when compared to group B. The results reported in this paper suggest the need of a precise muscle incision during an ovariectomy, which results in a quick location of the ovary in the female rats. Large muscle incisions or double dorsolateral incisions may lead to excess bleeding, requiring the use of more sutures.

## CONCLUSION

By comparison of these different types of incisions for the ovariectomy in rats, it is suggested that the use of a ventral abdominal transverse incision rather than a single midline dorsal skin incision, or a double dorsolateral incision may influence parameters like duration of surgery, recovery, and complication rates. Compared to groups A and B, the operation conducted in group C was technically easier, less time consuming, and with faster wound healing.

## ACKNOWLEDGEMENTS

The authors wish to thank the Al-Ameen College of Pharmacy for providing the facilities to carry out the research work.

## REFERENCES

1. Thorndike EA, Turner AS. In search of an animal model for postmenopausal diseases. *Front Biosci* 1998; 3:c17–26.
2. Hartke JR. Preclinical development of agents for the treatment of osteoporosis. *Toxicol Pathol* 1999; 27(1):143–7.
3. Turner RT, Maran A, Lotinun S, Hefferan T, Evans GL, Zhang M *et al.* Animal models for osteoporosis. *Rev Endocr Metab Disord* 2001; 2(1):117–27.
4. Lasota A, Danowska-Klonowska D. Experimental osteoporosis – different methods of ovariectomy in female white rats. *Rocz Akad Med Bialymst* 2004; 49(Suppl 1): 129–31.
5. Park SB, Lee YJ, Chung CK. Bone mineral density changes after ovariectomy in rats as an osteopenic model: stepwise description of double dorso-lateral approach. *J Korean Neurosurg Soc* 2010; 48(4):309–12.
6. Shirke SS, Jadhav SR, Jagtap AG. Methanolic extract of *Cuminum cyminum* inhibits ovariectomy-induced bone loss in rats. *Exp Biol Med* 2008; 233(11):1403–10.
7. Parhizkar S, Ibrahim R, Latiff LA. Incision choice in laparotomy: a comparison of two incision techniques in ovariectomy of rats. *World Apple Sci J* 2008; 4:537–40.
8. Bouzarjomehri F, Hajizade S, Sharafi AA, Firoozabadi SMP. Effects of low frequency pulsed electromagnetic fields on wound healing in rat skin. *Arch Iran Med* 2000; 3(1):23–7.
9. Burger JW, van 't Riet M, Jeekel J. Abdominal incisions: techniques and postoperative complications. *Scand J Surg* 2002; 91(4):315–21.
10. Grantcharov TP, Rosenberg J. Vertical compared with transverse incisions in abdominal surgery. *Eur J Surg* 2001; 167(4):260–7.