



REVISTA BRASILEIRA DE REUMATOLOGIA

www.reumatologia.com.br



Case report

IgA nephropathy in systemic lupus erythematosus patients: case report and literature review



Leonardo Sales da Silva, Bruna Laiza Fontes Almeida, Ana Karla Guedes de Melo, Danielle Christine Soares Egypto de Brito, Alessandra Sousa Braz, Eutília Andrade Medeiros Freire*

School of Medicine, Universidade Federal da Paraíba, João Pessoa, PB, Brazil

ARTICLE INFO

Article history:

Received 1 August 2014

Accepted 19 October 2014

Available online 16 February 2015

Keywords:

Systemic lupus erythematosus
IgA nephropathy
Glomerulonephritis

ABSTRACT

Systemic erythematosus lupus (SLE) is a multisystemic autoimmune disease which has nephritis as one of the most striking manifestations. Although it can coexist with other autoimmune diseases, and determine the predisposition to various infectious complications, SLE is rarely described in association with non-lupus nephropathies etiologies. We report the rare association of SLE and primary IgA nephropathy (IgAN), the most frequent primary glomerulopathy in the world population. The patient was diagnosed with SLE due to the occurrence of malar rash, alopecia, pleural effusion, proteinuria, ANA 1: 1280, nuclear fine speckled pattern, and anticardiolipin IgM and 280 U/mL. Renal biopsy revealed mesangial hypercellularity with isolated IgA deposits, consistent with primary IgAN. It was treated with antimalarial drug, prednisone and inhibitor of angiotensin converting enzyme, showing good progress. Since they are relatively common diseases, the coexistence of SLE and IgAN may in fact be an uncommon finding for unknown reasons or an underdiagnosed condition. This report focus on the importance of the distinction between the activity of renal disease in SLE and non-SLE nephropathy, especially IgAN, a definition that has important implications on renal prognosis and therapeutic regimens to be adopted in both the short and long terms.

© 2014 Elsevier Editora Ltda. All rights reserved.

Nefropatia por IgA em paciente portadora de lúpus eritematoso sistêmico: relato de caso e revisão de literatura

RESUMO

O lúpus eritematoso sistêmico (LES) é uma doença autoimune multissistêmica que tem como uma das manifestações mais marcantes a nefrite. Apesar de poder coexistir com outras doenças autoimunes e determinar a predisposição a diversas complicações infecciosas, o LES raramente é descrito em associação a nefropatias de etiologia não lúpica. Relatamos

Palavras chave:

Lúpus eritematoso sistêmico
Nefropatia por IgA
Glomerulonefrite

* Corresponding author.

E-mail: eutiliafreire@hotmail.com (E.A.M. Freire).

<http://dx.doi.org/10.1016/j.rbre.2014.10.011>

2255-5021/© 2014 Elsevier Editora Ltda. All rights reserved.

o caso da rara associação entre LES e nefropatia por IgA (NIGa) primária, a glomerulopatia primária mais frequente na população mundial. A paciente foi diagnosticada com LES pela ocorrência de eritema malar, alopecia, derrame pleural, proteinúria, pancitopenia, FAN 1:1.280 padrão nuclear pontilhado fino e anticardiolipina IgM 280 U/mL. A biópsia renal revelou hiper celularidade mesangial com depósitos isolados de IgA, compatível com NIGa primária. Foi tratada com antimalárico, prednisona e inibidor da enzima conversora de angiotensina e apresentou boa evolução. Por consistirem em doenças relativamente frequentes, a coexistência de LES e NIGa pode ser de fato um achado incomum por motivos desconhecidos ou uma condição subdiagnosticada. Este relato atenta para a importância da distinção entre a atividade de doença renal do LES e nefropatias não lúpicas, em especial a NIGa, definição que tem implicações importantes sobre o prognóstico renal e regimes terapêuticos a serem adotados em curto e longo prazo.

© 2014 Elsevier Editora Ltda. Todos os direitos reservados.

Introduction

Systemic lupus erythematosus (SLE) is a chronic disease of the connective tissue characterized by a number of immunological disorders which result in the onset of inflammatory lesion in various organ tissues. Lupus nephritis (LN) is the most common visceral manifestation of SLE, being diagnosed in approximately 37–45% of the patients at some time during the course of the disease in the Brazilian population.^{1,2} The description of nephritis of other etiologies in patients diagnosed with SLE, however, is an uncommon finding.³ IgA nephropathy (IgAN), although being the most common cause of glomerulopathy in general population,⁴ is rarely associated with SLE.^{5–10} We reported a case of rare coexistence of IgAN in a patient with SLE.

Case report

Forty-year-old female patient, complaining of generalized edema six months ago, associated with polyarthralgias, intermittent fever, alopecia, weight loss of 7 kg, and ulcerated lesion on the right leg. On examination the patient was pale, with bilateral periorbital edema, facial flushing, reduced vesicular murmur on the right, lower limb edema (2+/4+) and pyoderma gangrenosum in the middle third of the right leg, associated with stiffness and swelling of the right calf. Additional assessment indicated hemoglobin of 8.9 g/dL, leukopenia, mild thrombocytopenia, ANA 1:1.280 of nuclear fine speckled pattern, CH50 of 88 U/mL, C3 of 46 mg/dL, C4 of 9 mg/dL, negative anti-dsDNA, anticardiolipin IgM of 211 U/mL, proteinuria of 1045 mg/24 h, endogenous creatinine clearance of 162 mL/min, dysmorphic hematuria, and granular urinary casts. Chest computed tomography showed bilateral pleural effusion, mild pericardial effusion, and ascites. Lower limb Doppler ultrasonography ruled out thrombotic event. Renal biopsy was performed, showing 16 intact glomeruli with mesangial granular deposition of IgA, negative for other immune deposits, and mesangial hypercellularity (Fig. 1). The patient was diagnosed with SLE associated with IgAN, and she was initially treated with prednisone 60 mg/day, hydroxychloroquine 400 mg/day, enalapril 10 mg/day, and

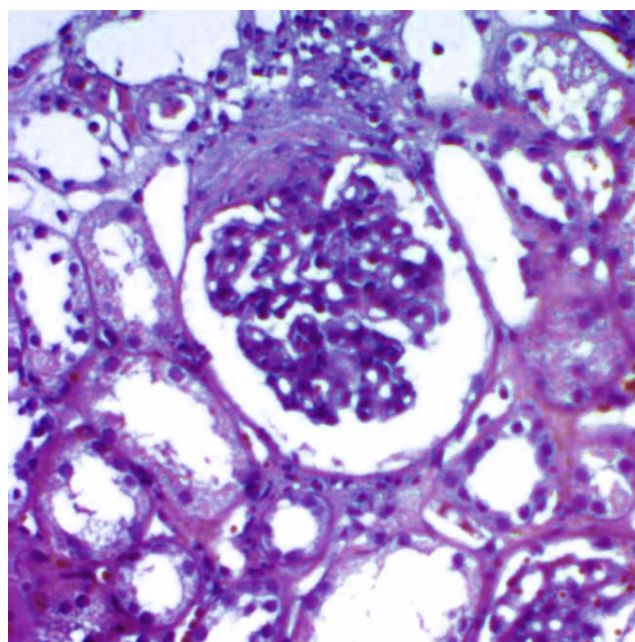


Fig. 1 – Optical microscopy of specimen obtained by renal biopsy revealing mesangial expansion and hypercellularity (HE, 200×).

supplementation of calcium and vitamin D, and antibiotics for skin lesion. After initiating treatment, the patient showed improvement of the joint, cutaneous, hematologic, and renal status, being ready for hospital discharge.

Discussion

SLE is a disease marked by heterogeneity of clinical phenotypes and unpredictable course.^{1,2} These properties make the characterization of the disease, the acknowledgment of its complications, and the detection of overlying conditions a constant challenge in the routine of rheumatology services. The classic clinical presentation of LN is persistent proteinuria and/or cellular casts, or active urinary sediment, i.e., five or more red blood cells or leukocytes per high power field.

Laboratory data may indicate SLE and LN activity, specifically as high titers of anti-dsDNA antibodies and complement consumption.¹¹

The IgAN, on the other hand, manifests itself as persistent microscopic, or sporadic macroscopic hematuria, with flare triggered by inflammatory stress. Proteinuria and other findings may or may not be present, and serum complement levels are typically normal.¹²

Due to the relative frequency of both conditions, the coexistence of primary IgAN and SLE can be an occasional finding. Both LN and IgAN are conditions which are characterized by disorders of immune function, with the presence of circulating immune complexes and anti-C1q antibodies, in addition to the involvement of genetic and environmental risk factors.¹²⁻¹⁴ It is still uncertain whether the rarity of the association of SLE with non-lupus nephritis occurs due to a protective factor presented by patients with SLE, or if we face underdiagnosed conditions.^{3,8,10} The coexistence of SLE and IgAN has been recently described, with only eight cases published in the world so far,⁵⁻¹⁰ with this being the first case reported in Brazil. Mac-Moune et al. first reported this association in 1995,⁵ with three patients who, similar to the one here in Brazil, had glomerular lesion of indolent course associated with exuberant systemic presentations. Curiously, Basile et al. and Kobak et al.^{6,10} described patients who, besides the diagnosis of IgAN and SLE, had Hashimoto's thyroiditis, a relatively common association with SLE, but that rarely coexists with IgAN.

The patient described was admitted to our hospital with a suggestive multisystemic clinical picture, and antibody profile consistent with the diagnosis of SLE. The identification of histopathological findings suggestive of IgAN in SLE patients was, as in most of the cases reported in the literature,^{5,6,8,10} from renal biopsy indicated for histological classification of probable LN. On two occasions the diagnosis of IgAN was suggested in patients with no SLE activity.^{7,9} This fact can point to an IgAN flare determined by the systemic inflammatory insult, a common characteristic of the disease,¹² in this case caused by SLE. Most of the described cases revealed normal complement, a factor favoring the diagnosis of IgA nephropathy. In contrast, the patient described herein, as well as those published by Corrado et al. and Kobak et al.^{8,10} showed complement consumption at diagnosis, possibly reflecting extrarenal lupus activity, such as the hematologic activity reported here. Another common feature among the cases described is the indolent course of IgAN, with urinary sediment changes, variable proteinuria, and preservation of glomerular filtration, with immunosuppressive therapy, when it is undertaken, being indicated due to extrarenal lupus activity.^{5,6,8,10}

Histopathological examination showed mesangial hypercellularity and glomerular deposition of IgA in the absence of other immune deposits. The immunohistological findings of IgAN include mesangial deposits of IgA, C3, and possibly, IgG and IgM in lesser extent.¹² On the other hand, the LN characteristic changes include glomerular, vascular and tubulointerstitial lesions with deposition of polyclonal immunoglobulins, mainly IgG, and fractions of complement C1q, C3 and C4.¹⁴ Although mesangial IgA deposition can be considered a subtype of LN, the absence of IgG, C1q, C3 and

C4 deposits is not an expected finding in LN, being more compatible with the diagnosis of IgAN.^{5,6,12}

The distinction between IgAN and LN in SLE patients has important prognostic and therapeutic implications. The general recommendations for treatment of IgAN are focused on blood pressure control and proteinuria reduction with antihypertensive drugs that act on the renin-angiotensin-aldosterone system, with immunosuppression being reserved to cases of crescentic glomerulonephritis, and corticosteroid therapy for limited time only in patients with persistent proteinuria greater than 1 g/24 h even after 3-6 months of optimized therapy.¹⁵ On the other hand, in the treatment for LN, besides controlling proteinuria and blood pressure, base therapy with antimalarials for all patients is recommended, as well as specific protocols of immunosuppression according to the histopathological class of the disease.¹¹

Finally, this report highlights the possibility of overexposure of primary IgAN in patients with SLE, which is an association that may be more common than it is frequently described in the literature, and has direct implications on the follow-up and treatment of these individuals with the short-, medium- and long-term complications.

Conflicts of interest

The authors declare no conflicts of interest.

REFERENCES

- Bezerra EL, Vilar MJ, Barbosa OF, Santos SQ, Castro MA, Trindade MC, et al. Lupus eritematoso sistêmico (LES): perfil clínico-laboratorial dos pacientes do Hospital Universitário Onofre Lopes (UFRN-Natal/Brasil) e índice de dano nos pacientes com diagnóstico recente. *Rev Bras Reumatol.* 2005;45(6):339-42.
- Borba EF, Araujo DB, Bonfá E, Shinjo SK. Clinical and immunological features of 888 Brazilian systemic lupus patients from a monocentric cohort: comparison with other populations. *Lupus.* 2013;22(6):744-9.
- Anders H, Weening JJ. Kidney disease in lupus is not always 'lupus nephritis'. *Arthritis Res Ther.* 2013;15:108.
- McGrogan A, Franssen CF, Vries CS. The incidence of primary glomerulonephritis worldwide: a systematic review of the literature. *Nephrol Dial Transpl.* 2011;26:414-30.
- Mac-Moune LF, Li EK, Tang LN, Li PK, Lui SF, Lai KN. IgA nephropathy: a rare lesion in systemic lupus erythematosus. *Mod Pathol.* 1995;8:5-10.
- Basile C, Semeraro A, Montanaro A, Giordano R, De Padova F, Marangi AL, et al. IgA nephropathy in a patient with systemic lupus erythematosus. *Nephrol Dial Transpl.* 1998;13:1891-2.
- Fujikura E, Kimura T, Otaka A, Arima S, Satoh H, Itoh S, et al. IgA nephropathy in the patient with systemic lupus erythematosus in remission. *Nippon Naika Gakkai Zasshi.* 2002;11:3282-4.
- Corrado A, Quarta L, Di Palma AM, Gesualdo L, Cantatore FP. IgA nephropathy in systemic lupus erythematosus. *Clin Exp Rheumatol.* 2007;25:467-9.
- Horino T, Takao T, Terada Y. IgA nephropathy in a patient with systemic lupus erythematosus. *Lupus.* 2010;19:650-4.
- Kobak S, Hudaverdi O, Keser G, Oksel F. Coexistence of systemic lupus erythematosus, Hashimoto's thyroiditis, and

- IgA nephropathy in the same patient. *Mod Rheumatol*. 2011;21:89-91.
11. Hahn BH, McMahon MA, Wilkinson A, Wallace WD, Daikh DI, Fitzgerald JD, et al. American college of rheumatology guidelines for screening, treatment, and management of lupus nephritis. *Arthritis Care Res*. 2012;64(6):797-808.
 12. Barratt J, Feehally J. IgA nephropathy. *J Am Soc Nephrol*. 2005;16(7):2088-97.
 13. Gunnarsson I, Rönnelid J, Lundberg I, Jacobson SH. Occurrence of anti-C1q antibodies in IgA nephropathy. *Nephrol Dial Transpl*. 1997;12(11):2263-8.
 14. Sinniah R, Feng PH. Lupus nephritis. Correlation between light, electron microscopic, and immunofluorescent findings and renal function. *Clin Nephrol*. 1976;6(2):340-51.
 15. Floege J, Feehally J. Treatment of IgA nephropathy and Henoch-Schönlein nephritis. *Nat Rev Nephrol*. 2013;9:320-7.