



# REVISTA BRASILEIRA DE REUMATOLOGIA

www.reumatologia.com.br



## Case report

# Miliary tuberculosis: a severe opportunistic infection in juvenile systemic lupus erythematosus patients



Priscilla S. Freire<sup>a</sup>, João D. Montoni<sup>a</sup>, Aline S.M. Ribeiro<sup>a</sup>, Heloísa H. Marques<sup>b</sup>,  
Thais Mauad<sup>c</sup>, Clovis A. Silva<sup>a,d,\*</sup>

<sup>a</sup> Pediatric Rheumatology Unit, Instituto da Criança, School of Medicine, Universidade de São Paulo, São Paulo, SP, Brazil

<sup>b</sup> Pediatric Infectious Diseases Unit, Instituto da Criança, School of Medicine, Universidade de São Paulo, São Paulo, SP, Brazil

<sup>c</sup> Department of Pathology, School of Medicine, Universidade de São Paulo, São Paulo, SP, Brazil

<sup>d</sup> Division of Rheumatology, Instituto da Criança, School of Medicine, Universidade de São Paulo, São Paulo, SP, Brazil

## ARTICLE INFO

### Article history:

Received 20 December 2013

Accepted 14 April 2014

Available online 28 November 2014

### Keywords:

Tuberculosis

Immunosuppressive

Infection

Children

Systemic lupus erythematosus

## ABSTRACT

**Introduction:** One of the main issues in juvenile systemic lupus erythematosus (JSLE) patients is infection, such as tuberculosis (TB). Of note, SLE patients are susceptible to pulmonary and extrapulmonary TB. However, to our knowledge, this contagious disease was rarely reported in pediatric lupus population, particularly diffuse or miliary TB. Therefore, from January 1983 to December 2011, 5,635 patients were followed-up at our Pediatric Rheumatology Unit and 285 (5%) of them met the American College of Rheumatology classification criteria for SLE. **Case reports:** Four (1.4%) of our JSLE patients had disseminated TB and were described herein. All of them were female gender, received BCG vaccination and did not have a history of TB household contact. The median of current age at TB diagnosis and the period between JSLE and TB diagnosis were 17 years old (range 14–20) and 5.5 years (range 2–7), respectively. All patients developed miliary TB during the course of the disease. The median of SLE Disease Activity Index 2000 (SLEDAI-2K) was 4 (2–16) and the patients were treated with immunosuppressive agents (glucocorticoid, azathioprine and/or intravenous cyclophosphamide). Two of them presented sepsis and TB diagnosis was only established at autopsy, especially with lungs, central nervous system and abdominal involvements. Anti-TB therapy (isoniazid, rifampicin and pyrazinamide) was indicated in the other two TB cases, however they deceased.

**Discussion:** Miliary TB is a rare and severe opportunist infection in pediatric lupus population. This study reinforces the importance of routine searches for TB in JSLE patients.

© 2014 Elsevier Editora Ltda. All rights reserved.

\* Corresponding author.

E-mails: [clovis.silva@icr.usp.br](mailto:clovis.silva@icr.usp.br), [clovisaasilva@gmail.com](mailto:clovisaasilva@gmail.com) (C.A. Silva).

<http://dx.doi.org/10.1016/j.rbre.2014.04.007>

2255-5021/© 2014 Elsevier Editora Ltda. All rights reserved.

## Tuberculose miliar: infecção oportunista grave em pacientes com lúpus eritematoso sistêmico juvenil

### R E S U M O

#### Palavras-chave:

Tuberculose  
Imunossupressor  
Infecção  
Crianças  
Lúpus eritematoso sistêmico

**Introdução:** Um dos principais problemas no lúpus eritematoso sistêmico juvenil (LESJ) é a infecção, como a tuberculose (TB). É importante observar que pacientes com LES são suscetíveis à tuberculose pulmonar e extrapulmonar. No entanto, de acordo com o que se sabe, essa doença contagiosa é raramente relatada na população pediátrica com lúpus, particularmente a TB difusa ou miliar. De janeiro de 1983 a dezembro de 2011, 5.635 pacientes foram acompanhados na Unidade de Reumatologia Pediátrica; 285 deles (5%) preencheram os critérios de classificação para LES do American College of Rheumatology.

**Relatos de caso:** Quatro (1,4%) de nossos pacientes com LESJ tinham tuberculose disseminada e foram descritos neste estudo. Todos eram do sexo feminino, receberam a vacina BCG e não tinham história de contato domiciliar com a TB. A mediana da idade no momento do diagnóstico da TB e o período entre os diagnósticos de LES e tuberculose foram de 17 anos (variação de 14 a 20) e 5,5 anos (variação de dois a sete), respectivamente. Todas as pacientes desenvolveram tuberculose miliar durante o curso da doença. A mediana no SLE Disease Activity Index 2000 (SLEDAI-2K) foi de 4 (2 a 16) e as pacientes foram tratadas com agentes imunossupressores (glicocorticoides, azatioprina e/ou ciclofosfamida intravenosa). Duas delas apresentaram sepse e o diagnóstico de tuberculose só foi determinado na necropsia, com envolvimento especialmente dos pulmões, do sistema nervoso central e do abdome. A terapia antituberculose (isoniazida, rifampicina e pirazinamida) foi indicada nos outros dois casos de TB; porém, as pacientes foram a óbito.

**Discussão:** A TB miliar é uma infecção oportunista rara e grave na população pediátrica com lúpus. Este estudo reforça a importância de pesquisas de rotina para TB em pacientes com LESJ.

© 2014 Elsevier Editora Ltda. Todos os direitos reservados.

## Introduction

Infections are very important issues in juvenile systemic lupus erythematosus (JSLE) patients, such as tuberculosis (TB).<sup>1</sup> This is an endemic chronic infectious disease<sup>2</sup> and it is the second cause of death due to contagious diseases in the world.<sup>3</sup>

Of note, SLE patients have an increased susceptibility to pulmonary and extrapulmonary TB,<sup>4-8</sup> with a poor outcome.<sup>6</sup> TB has been especially described in adult active SLE patients receiving immunosuppressive agents,<sup>6</sup> and may mimic lupus clinical findings.<sup>7</sup> To our knowledge, this transmissible disease is rarely reported in pediatric lupus population, particularly diffuse or miliary TB.<sup>4</sup>

Therefore, from January 1983 to December 2011, 5635 patients were followed-up at our service and 285 (5%) of them met the American College of Rheumatology (ACR)<sup>9</sup> classification criteria for SLE. Four (1.4%) of our JSLE patients had diffuse TB. The TB diagnoses were performed from 1996 to 2009 and these were described herein. This study was approved by the Local Ethics Committee of our University Hospital. The demographic data, clinical manifestations, disease activity and disease damage indexes, laboratory exams and therapeutic regimen at miliary TB diagnosis in JSLE patients are described in [Table 1](#). The median of current prednisone dose at TB diagnosis was 30 mg/day (15–60) ([Table 1](#)).

## Case reports

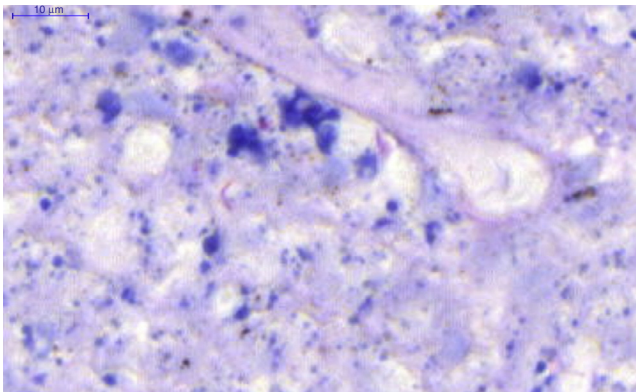
### Case 1

A 20-year-old girl was diagnosed with SLE at 17 years and 11 months based on the following ACR classification criteria:<sup>9</sup> photosensitivity, ulcers of the oral mucosa, arthritis in knees, psychosis, granular casts and immunologic tests: antinuclear antibody (ANA) 1:200, anti double-stranded DNA (anti-dsDNA) 1:40 (normal cut-off <1:10) and anti-cardiolipin (ACL) IgM 63 MPL (normal cut-off <10). Intradermal reaction purified protein derivative (PPD) test was 0 mm. The SLE Disease Activity Index 2000 (SLEDAI-2K) was 22.<sup>10</sup> She was treated with prednisone (60 mg/day), chloroquine (250 mg/day) and azathioprine (100 mg/day). During the next two years, she received chloroquine (250 mg/day). At the age of 20 years, she was on remission and was admitted to the emergency department due to three days of severe acute abdominal pain, fever and cutaneous vasculitis (tender nodules in the hands). Pneumoperitoneum was diagnosed and she was promptly submitted to laparotomy. Caecal perforation with intestinal vasculitis was identified and fixed by ileum-ascendant colon anastomosis. The SLEDAI-2K<sup>10</sup> was 16 and she was treated with three pulses of intravenous methylprednisolone (1 g/day) and metronidazole, followed by prednisone (60 mg/day). The Systemic Lupus International Collaborating Clinics/American College of Rheumatology - Damage Index (SLICC/ACR-DI)<sup>11</sup>

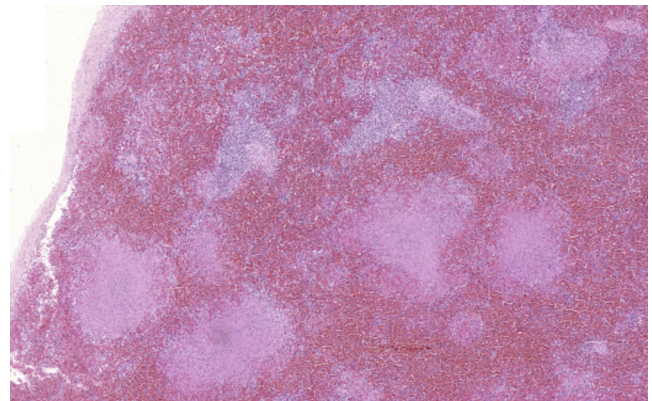
**Table 1 – Demographic data, clinical manifestations, disease activity, disease damage, laboratory exams and treatment at miliary tuberculosis (TB) diagnosis in juvenile systemic lupus erythematosus (JSLE) patients.**

Variables	Cases			
	1	2	3	4
<i>Demographic data</i>				
Age at TB diagnosis, years	20	19	15	14
Interval between JSLE onset and TB diagnosis, years	2	7	6	5
Gender	F	F	F	F
BCG vaccination	+	+	+	+
TB contact history	–	–	–	–
TB clinical manifestations	Peritonitis, pneumonia, coma, papilledema, brain herniation	Cough, mental confusion, headache	Cough, sputum, dyspnea, mental confusion, irritability	Cough, sputum, dyspnea, adenomegaly, abdominal pain, drowsiness, stupor
<i>Disease activity and damage at TB diagnosis</i>				
SLEDAI-2K	16	2	2	4
SLICC-ACR/DI	1	2	0	0
<i>Laboratory exams at TB diagnosis</i>				
Hemoglobin, g/dL	11.8	10.5	7.8	10
Hematocrit, %	36	32	26.4	27.1
Leukocytes, cells/mm <sup>3</sup>	5500	6600	4100	8600
Lymphocytes, cells/mm <sup>3</sup>	502	600	451	6622
Platelets, cells/mm <sup>3</sup>	104,000	150,000	69,000	271,000
<i>Urinalysis</i>				
Leukocytes/mL	200,000	10,000	4000	9000
Erythrocytes/mL	710,000	23,000	0	1000
Proteinuria, g/24 h	0.01	0.98	0.1	1.42
CRP, mg/L	159	39.6	156	38.8
PPD test, mm	0	0	15	15
Chest X-ray	Diffuse infiltrate	Diffuse infiltrate	Diffuse infiltrate, pleuritis	Cotton wool spots infiltrate
MT isolation	Peritoneum, diffuse in autopsy	Diffuse in autopsy	Sputum, diffuse in autopsy	Sputum
JSLE treatment at TB diagnosis (mg/day)	PD (60)	PD (30), AZA (100)	PD (15), AZA (100), CH (250)	PD (30), CH (250)
TB treatment	NP	NP	HRZ MDRTB	HRZ
Outcome	D	D	D	D

BCG, bacillus Calmette-Guérin; LAP, lymphadenopathy; CRP, C-reactive protein; NP, not performed; MT, *Mycobacterium tuberculosis*; - negative; + positive; PPD, intradermal reaction purified protein derivative; H, isoniazid; R, rifampicin; Z, pyrazinamide; PD, prednisone; AZA, azathioprine; CH, chloroquine diphosphate; MDRTB, multi-drug resistant TB; S, survived; D, deceased.



**Fig. 1 – Isolation of *Mycobacterium tuberculosis* in lungs (case 1).**

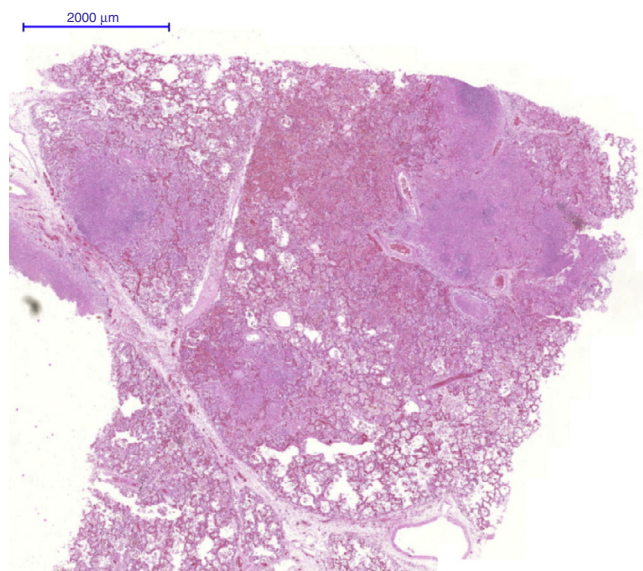


**Fig. 2 – Granulomatous inflammation and caseous necrosis in spleen (case 1).**

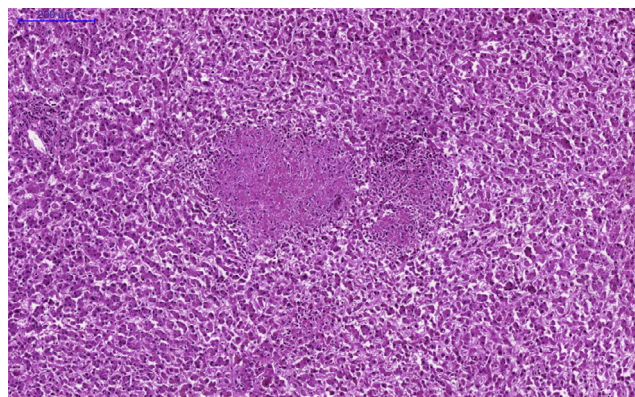
was 1. Six days later, she developed pneumonia and sepsis and was treated with ceftriaxone and vancomycin. After two days, she had coma (Glasgow status 6) and bilateral papilledema was observed. Urgent brain computed tomography demonstrated brain herniation and she deceased. Ten days after her death, the TB diagnosis was established at autopsy findings demonstrated miliary TB with granulomatous inflammation and caseous necrosis with acid-fast bacillus, and isolation of *Mycobacterium tuberculosis* in meninges, lungs (Fig. 1), peritoneum, spleen (Fig. 2), ovary and fallopian tubes. The *M. tuberculosis* was also isolated in cerebrospinal fluid culture (CSF) culture 15 days after death. Other data related to the patient during the tuberculosis period are presented in are in Table 1.

### Case 2

A 19-year-old girl was diagnosed with SLE at 12 years according to the following ACR classification criteria:<sup>9</sup> malar rash, mucosal ulcers, pericarditis, proteinuria 6.3 g/24 h, ANA (1:560, dense fine speckled pattern), anti-ds DNA (1:160) and anti-Sm antibodies. The PPD test was 0 mm and SLEDAI-2K was 16.<sup>10</sup> Renal biopsy showed focal proliferative lupus nephritis. She was treated with three pulses of intravenous methylprednisolone (1.0 g/day), prednisone (60 mg/day) and chloroquine (250 mg/day) in combination with seven monthly intravenous cyclophosphamide (IVCYC) (0.5–1.0 g/m<sup>2</sup>/month) doses followed by every 3 months doses for a period of 2.5 years. During the next 5 years, she was on remission. At the age of 19, she developed vertebral lumbar fracture. Intradermal reaction purified protein derivative (PPD) test was 0 mm and diffuse infiltrate in the chest X-ray (Table 1). SLEDAI-2K<sup>10</sup> was 12, SLICC/ACR-DI<sup>11</sup> was 2 and she received prednisone (30 mg/day) and azathioprine 100 mg/day. At that moment, lumbar dual-energy X-ray absorptiometry (DXA) showed z-score of -4 and she was treated with alendronate and calcitonin. Neither fever nor weight loss was reported. Two



**Fig. 3 – Granulomatous inflammation and caseous necrosis in lungs (case 2).**

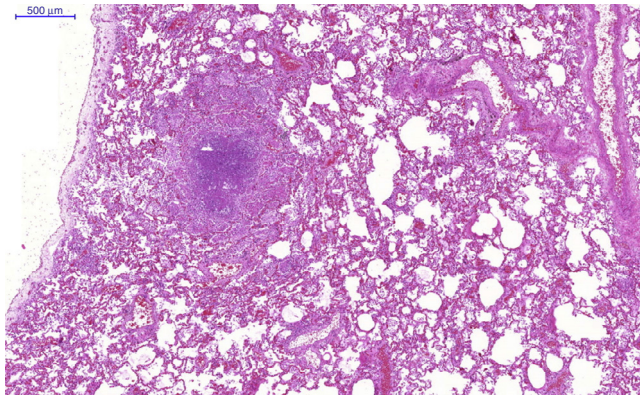


**Fig. 4 – Granulomatous inflammation and caseous necrosis in liver (case 2).**

weeks later, she presented with intermittent mild cough, mental confusion, headache and developed acute pneumonia and sepsis, and deceased after one week, despite broad spectrum antibiotics therapy (ceftriaxone and vancomycin). The TB diagnosis was established at autopsy and revealed acute pneumonia with alveolar hemorrhage, miliary TB with granulomatous inflammation, containing caseous necrosis with isolation of *M. tuberculosis* in cultures of lungs (Fig. 3), lymph nodes, spleen and liver (Fig. 4). *M. tuberculosis* was not isolated in spine.

### Case 3

A 15-year-old girl was diagnosed with SLE at 9 years according to the following ACR classification criteria:<sup>9</sup> arthritis in knees, serositis (pleuritis and pericarditis), lymphopenia, proteinuria 1.1 g/day, ANA (1:560, dense fine speckled pattern), anti-ds DNA (1:60), and ACL IgG (45 GPL) antibodies. The PPD test was 0 mm. The SLEDAI-2K<sup>10</sup> was 18, including nephritis descriptors. She was treated with prednisone (60 mg/day), azathioprine (150 mg/day) and chloroquine (250 mg/day). During the next 6 years, the patient presented mild disease activity and at the age of 15, she had cough, sputum and dyspnea and chest X-ray showed diffuse lung infiltrates with unilateral pleuritis. At that moment she was receiving prednisone (15 mg/day), azathioprine (100 mg/day) and chloroquine (250 mg/day). No family history of TB was reported. The TB diagnosis was established according to culture of sputum with *M. tuberculosis* and PPD test of 15 mm. The SLEDAI-2K<sup>10</sup> was 2 and SLICC/ACR-DI<sup>11</sup> was 0. She was treated with rifampicin, isoniazid and pirazinamide. One week later, she developed abdominal pain and vomiting. The aspartate aminotransferase (AST) was 939 IU/L (normal 5–26), alanine aminotransferase (ALT) 215 IU/L (normal 19–44) and gamma-glutamyl transpeptidase (GGT) 1582 g/dL (10–22). Due to hepatotoxicity, the anti-TB therapy was suspended. Therefore, another screening test was performed and after 10 days, sputum culture showed multi-drug resistant *M. tuberculosis* (namely resistance to isoniazid and rifampicin) and she was treated with ciprofloxacin, ethambutol and streptomycin, the second line treatment presented to eradicate *Mycobacterium tuberculosis* with lower liver toxicity. Three days later, she had



**Fig. 5 – Granulomatous inflammation and caseous necrosis in lungs (case 3).**

mental confusion, irritability and deceased. The autopsy findings showed miliary TB with granulomatous inflammation, caseous necrosis and isolation of *M. tuberculosis* in cultures of lungs (Fig. 5), spleen, liver and bone marrow.

#### Case 4

A 14-year-old girl was diagnosed with SLE at 9 years according to the following ACR classification criteria:<sup>9</sup> arthritis in knees, mucosal ulcers, hemolytic anemia and lymphopenia, proteinuria 1.5 g/24 h, granular urinary casts, ANA (1:240), anti-dsDNA (1:160) antibodies and lupus anticoagulant. The PPD test was 0 mm. The SLEDAI-2K<sup>10</sup> was 16, including nephritis descriptors. She was treated with intravenous methylprednisolone pulses (1.0 g/day), prednisone (60 mg/day) and chloroquine (250 mg/day). One month after this treatment, the proteinuria reduced and we did not perform renal biopsy. During the next 5 years, the patient remained moderate disease activity and at the age of 14, she had cough, fever, diffuse and severe abdominal pain, sputum and dyspnea with cotton-wool spots infiltrate on chest X-ray, and disseminated adenomegaly. No family history of TB was reported. At that time she was under prednisone (30 mg/day) and chloroquine (250 mg/day). The TB diagnosis was established according to sputum culture with *Mycobacterium tuberculosis*. SLEDAI-2K<sup>10</sup> was 4 and SLICC/ACR-DI<sup>11</sup> was 0. She was treated with rifampicin, isoniazid and pirazinamide. Despite the anti-TB treatment, one day later, she developed drowsiness, stupor, severe dyspnea and respiratory insufficiency, requiring mechanic ventilation. Five days later she died. Her parents did not give their consent for an autopsy procedure.

## Discussion

To our knowledge, this was the first study that evaluated disseminated TB in pediatric JSLE population, and showed that miliary TB was a rare and severe opportunist infection in patients under immunosuppressive therapy. These patients were followed-up in only one of the tertiary Pediatric University Hospitals in a large city of Brazil.

Importantly, our 285 JSLE patients received the bacillus Calmette-Guérin (BCG) vaccination at neonatal period, as indicated in all Brazilian newborn. Since this infection is prevalent in our country,<sup>2</sup> these patients are routinely assessed for tuberculosis according to TB household contact history, undergo PPD test and chest X-ray before immunosuppressive treatment. Our cases probably presented new primary TB infections, since the PPD test was 0 mm when immunosuppressive therapies were performed.

Tuberculosis is a contagious disease in which the definite diagnosis requires the identification of *M. tuberculosis*, as confirmed in all of our cases. It is spread by expectoration of airborne droplets of people with active disease which are inhaled and lodged in the distal airways.<sup>3</sup> Intrinsic immunological abnormalities in humoral and cellular functions may contribute to this opportunistic infection in lupus patients.<sup>1</sup> The reactivation of remote infection can be triggered due to an immune system abnormalities,<sup>2</sup> and immunosuppressive disorders are considered risk factors for this disease, such as HIV infection, severe malnutrition<sup>2</sup> and SLE patients.<sup>4-8</sup>

This contagious disease in adult SLE patients is habitually insidious and can range from latent disease and isolated respiratory system involvement to extrapulmonary TB.<sup>4-7,12</sup> Other sites affected in TB lupus patients are the central nervous system, lymphatic organs, peritoneum,<sup>12</sup> genitourinary tract, vertebral bodies, joints and soft tissues.<sup>4,6,7</sup> Of note, tuberculosis, particularly in lungs and meninges, was rarely reported in JSLE patients, as observed in our lupus population.<sup>4,12</sup>

Moreover, disseminated or miliary TB, which involves many organs simultaneously,<sup>3</sup> has been described during the disease course, as observed herein. The prevalence of this severe disease occurred in 0% to 15% of adult SLE patients suffering from TB.<sup>4-7</sup> Diffuse TB may resemble sepsis, as evidenced in our cases, and may be underestimated in lupus population due to the fact that various rheumatologic services do not perform necropsy systematically.<sup>1</sup>

The extra-pulmonary TB may also be related to immunosuppressive drugs, especially glucocorticosteroid use,<sup>7</sup> as observed in our patients. Furthermore, JSLE clinical manifestations may also mimic pulmonary and disseminated TB.<sup>1</sup> Therefore, tuberculosis ought to be investigated in active lupus patients.

The treatment of this infectious disease includes at least three bactericidal drugs (isoniazid, rifampicin and pyrazinamide), as administered in our adolescent patients. One limitation of the present study was the retrospective design, which included patients diagnosed with TB before 2009 and treated with these three medications. Currently, the first-line four-drug therapy is recommended according to World Health Organization guidelines.<sup>13</sup> In Brazil, we have been using these guidelines, including isoniazid, rifampicin, pyrazinamide and ethambutol in children older than 9 years of age, since 2010.<sup>14</sup>

However, despite treatment, disseminated TB may have a fatal outcome. One of our JSLE patients had acute hepatitis that is the most significant adverse event of TB therapy.<sup>6</sup> Additionally, she also presented with multi-drug resistant *M. tuberculosis* (namely resistance to isoniazid and rifampicin), thus leading to an unfavorable outcome.

This study reinforces the importance of screening with new tests for TB diagnosis, such as QuantiFERON-TB Gold test which is an IFN- $\gamma$  release assays, since PPD, the classic assay for latent tuberculosis infection diagnose, has diminished accuracy in immunosuppressed patients.<sup>15</sup> Indeed, recently a study showed that QuantiFERON-TB Gold assay seemed to be a more accurate test for the detection of latent tuberculosis infection compared to PPD test in SLE patients that received BCG vaccination and did not report TB contact history.<sup>16</sup>

In conclusion, miliary TB is a rare and severe opportunist infection in pediatric lupus population. This study reinforces the importance of routine searches for TB in JSLE patients, especially with lungs, central nervous system and abdominal involvements. A multicenter JSLE registry study to evaluate the risk factors associated with this important contagious disease will be performed in Brazilian population suffering from this chronic disease.

---

### Conflict of interest

The authors declare no conflict of interest.

### REFERENCES

---

1. Facó MM, Leone C, Campos LM, Febrônio MV, Marques HH, Silva CA. Risk factors associated with the death of patients hospitalized for juvenile systemic lupus erythematosus. *Braz J Med Biol Res.* 2007;40:993-1002.
2. Sant'Anna CC, Hijjar MA. Recent contribution of the World Health Organization to control childhood tuberculosis. *Rev Saúde Pública.* 2007;41:117-20.
3. Frieden TR, Sterling TR, Munsiff SS, Watt CJ, Dye C. Tuberculosis. *Lancet.* 2003;362:887-99.
4. Ghosh K, Patwardhan M, Pradhan V. Mycobacterium tuberculosis infection precipitates SLE in patients from endemic areas. *Rheumatol Int.* 2009;29:1047-50.
5. Pasoto SG, Borba EF, Bonfa E, Shinjo SK. Lupus pleuritis: a relevant risk factor for pulmonary tuberculosis. *Lupus.* 2010;19:1585-90.
6. Sayarlioglu M, Inanc M, Kamali S, Cefle A, Karaman O, Gul A, et al. Tuberculosis in Turkish patients with systemic lupus erythematosus: increased frequency of extrapulmonary localization. *Lupus.* 2004;13:274-8.
7. Hou CL, Tsai YC, Chen LC, Huang JL. Tuberculosis infection in patients with systemic lupus erythematosus: pulmonary and extra-pulmonary infection compared. *Clin Rheumatol.* 2008;27:557-63.
8. Erdozain JG, Ruiz-Irastorza G, Egurbide MV, Martinez-Berriotxo A, Aguirre C. High risk of tuberculosis in systemic lupus erythematosus? *Lupus.* 2006;15:232-5.
9. Hochberg MC. Updating the American College of Rheumatology revised criteria for the classification of systemic lupus erythematosus. *Arthritis Rheum.* 1997;40:1725.
10. Gladman DD, Ibañez D, Urowitz MB. Systemic lupus erythematosus disease activity index 2000. *J Rheumatol.* 2002;29:288-91.
11. Gladman D, Ginzler E, Goldsmith C, Fortin P, Liang M, Urowitz M, et al. The development and initial validation of the Systemic Lupus International Collaborating Clinics/American College of Rheumatology damage index for systemic lupus erythematosus. *Arthritis Rheum.* 1996;39:363-9.
12. Kim JM, Kim KJ, Yoon HS, Kwok SK, Ju JH, Park KS, et al. Meningitis in Korean patients with systemic lupus erythematosus: analysis of demographics, clinical features and outcomes; experience from affiliated hospitals of the Catholic University of Korea. *Lupus.* 2011;20:531-6.
13. World Health Organization. Treatment of tuberculosis guidelines; 2009. Report no.: WHO/HTM/TB/2009/420. ISBN: 9789 241547833.
14. Manual de recomendações para controle da tuberculose no Brasil. Secretaria de Vigilância em Saúde/MS. [http://portal.saude.gov.br/portal/arquivos/pdf/manual\\_de\\_recomendacoes.tb.pdf](http://portal.saude.gov.br/portal/arquivos/pdf/manual_de_recomendacoes.tb.pdf)
15. Redelman-Sidi G, Sepkowitz KA. Interferon gamma release assays in the diagnosis of latent tuberculosis infection among immunocompromised adults. *Am J Respir Crit Care Med.* 2013;188:422-31.
16. Yilmaz N, Zehra Aydin S, Inanc N, Karakurt S, Direskeneli H, Yavuz S. Comparison of QuantiFeron-TB Gold test and tuberculin skin test for the identification of latent *Mycobacterium tuberculosis* infection in lupus patients. *Lupus.* 2012;21:491-5.