

USE OF BLOCKED INTRAMEDULLARY NAIL FOR THE TREATMENT OF HUMERAL DIAPHYSEAL FRACTURES

FERNANDO BALDY DOS REIS¹, ARNALDO VALDIR ZUMIOTTI², HÉLIO JORGE ALVACHIAN FERNANDES³, MILTON CHOCHF⁴, FLÁVIO FALOPPA⁵

SUMMARY

Clinical and radiographic outcomes of 31 patients with humeral diaphyseal fractures submitted to surgery with intramedullary nails were studied. From these, four patients presented fractures at the nail insertion site and were treated using a different method. From the 27 patients left, the healing rate was 96.1%, with an average duration of 63.4 days. Five of them complained of pain in the shoulder and only one presented abduction limitation. Temporary

palsy of the radial nerve was found in two patients and pseudoarthrosis in one of them, who was submitted to a new surgical intervention with plate and autologous bone graft, after 5 months. It was concluded that, although blocked intramedullary nails present a high incidence of the retrograde access port leading to fractures in its insertion site and the anterograde port causing pain in the shoulder.

Keywords: Rotator Cuff; Humeral fractures; internal fixation

INTRODUCTION

The surgical treatment of humeral diaphyseal fractures with blocked intramedullary nails is becoming more popular in recent years, but controversy exists regarding its efficiency compared to the use of osteosynthesis with plates. Prospective and randomized studies comparing these two osteosynthesis methods report a higher complication rate with the use of nails, consequently leading to a higher number of retreatments.

In spite of these evidences, the non-violation of the fracture nucleus and the possibility of use through retrograde access avoiding rotator cuff handling, makes the use of this osteosynthesis method very attractive.

The objective of this study is to report the outcomes of surgical treatment of humeral diaphyseal fractures with blocked intramedullary nails with emphasis on potential complications.

MATERIALS AND METHODS

Between 1999 and 2002, 31 patients with humeral diaphysis fractures were operated at Hospital São Paulo and Hospital Sirio Libanês, in whom osteosynthesis with blocked intramedullary nail insertion was performed. From these patients, 21 were males and 10 were females. Left humerus was affected in 10 patients and the right humerus in 21. There was no neurovascular lesion due to fracture. According to AO classification, 24 fractures were type A, 2 were type B, and 4 were type C (Table 1).

From these, 3 were type-1 open fractures according to Gustilo-Anderson's Classification. In two patients with open fractures, the temporary use of an external fixation device was chosen, being the conversion to blocked intramedullary nail performed on the 10th day of post-operative follow-up. In 14 patients, the used implant was a flexible blocked intramedullary nail (Flexnail*), and, in 17

patients, the universal intramedullary nail was used (UHN*). Access ports used were anterograde in 16 patients and retrograde in 15 patients.

Surgical Technique Retrograde access port

After being submitted to general anesthesia and to brachial plexus blockage, the patients were placed in dorsal decubitus with flexed trunk until half-seated position was reached. Then, asepsis and antisepsis were performed and sterilized drapes were placed. A longitudinal 4-cm incision addressing the skin and subcutaneous tissue was done at deltoid-pectoralis sulcus, and then, by blunt divulsion, from the acromion anterior border, deltoid anterior fibers were separated until the total exposure of humerus major tuberosity. The insertion point was performed proximal to the major tuberculum after longitudinal opening, with knife, of the rotator cuff maintaining the fibers in its insertion. Following, the nail was introduced into the proximal segment, and, with the aid of an image intensifier, fracture reduction was performed with the nail itself. Proximal blockage was done with the aid of a guide, and the distal blockage was made with hands free, with the use of the image intensifier. After rotator cuff and skin suture, the operated limb was immobilized with sling and the patient was encouraged to initiate an early rehabilitation program (Figures 1A and 1B).

Retrograde access port

After being submitted to general anesthesia and to brachial plexus blockage, patients were placed in ventral decubitus. Then, asepsis and antisepsis were performed and sterilized drapes were placed. A longitudinal 5-cm incision, addressing skin and subcutaneous tissue, was done on arm's posterior plane at the olecranal fossa protuberance. Triceps fascia was opened longitudinally and the muscular fibers were divulsed until olecranal fossa was exposed,

Study conducted by the Traumatology Discipline of the Department of Orthopaedics and Traumatology - Federal University of São Paulo, Paulista Medical School - UNIFESP/EPM.

Correspondences to: Helio J.A.Fernandes: Rua Borges Lagoa,783, 5º andar- Departamento de Ortopedia, Disciplina de Trauma Vila Clementino- SP - e mail: heliofernandes@terra.com.br

1. Full Professor of the Discipline of Traumatology, Department of Orthopaedics and Traumatology, Federal University of São Paulo – Paulista Medical School – UNIFESP/EPM.
2. Associate Professor – Head of the Discipline of Traumatology – Hand and Microsurgery – Medical College, University of São Paulo - USP
3. Assistant Professor, PhD, Head of the Trauma Department, Discipline of Traumatology, Department of Orthopaedics and Traumatology, Federal University of São Paulo – Paulista Medical School – UNIFESP/EPM.
4. Assistant Professor – PhD in Traumatology, Department of Orthopaedics and Traumatology of the Federal University of São Paulo – Paulista Medical School – UNIFESP/EPM
5. Chairman and Head of the Department of Orthopaedics and Traumatology, Federal University of São Paulo – Paulista Medical School – UNIFESP/EPM

Received in: 12/15/04; approved in: 05/05/05

TYPE	A1	A2	A3	B1	B2	B3	C1	C2	C3
Nr. OF PATIENTS	1	5	18	0	2	0	5	1	4

Table 1- Distribution of the number of patients according to fracture type as for AO classification of diaphyseal fractures

avoiding joint capsule opening. The insertion point was performed at 1 cm proximal to olecranal fossa with 3 holes made with a 3.2cm drill so as to form a small equilateral triangle. The center of this triangle was enlarged with an appropriate drill up to the diameter of 10 mm (Figures 2A, 2B and 2C), taking care to not to breach humeral anterior cortical. The nail was introduced at the medullar channel through this port and, with the use of an image intensifier, reduction was performed, at fracture closed focus, with the use of that nail. Distal blockage was performed with the use of a guide and the proximal, with free hands, with the aid of the image intensifier. After triceps fascia and skin suture, a dressing was placed and the operated limb was kept in sling, being the patient recommended to initiate an early rehabilitation program (Figures 3A and 3B).

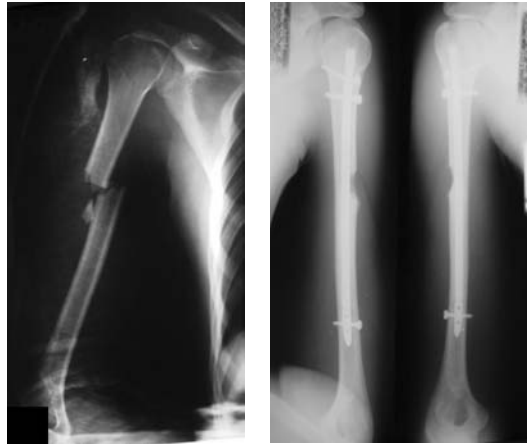
Evaluation criteria

On post-operative period, patients were periodically evaluated through clinical and radiographic examination, with the following data being recorded: shoulder joint range of motion, presence of pain in those joints, time for fracture union, and eventual complications, such as: humeral fracture, pseudoarthrosis, neurological lesion, and infection.

RESULTS

During surgical procedure, a new fracture of the humerus occurred at the nail introduction site in one patient and in 3 other patients after two weeks of follow-up. In these four patients, the retrograde access port was used and the method was replaced by osteosynthesis with plate and screws. In three of them, the used nail was the flexible type (Flexnail) and in one patient, the stiff universal (UFN) was used. The four patients were females.

In the 27 patients left, whose treatment was completed, the union rate was 96.1 % . The union time for those patients was, in average, 63.4 days, with a minimum of 50 and a maximum of 80 days.



Figures 1A and 1B: Anterograde nail in humeral, type-B fracture

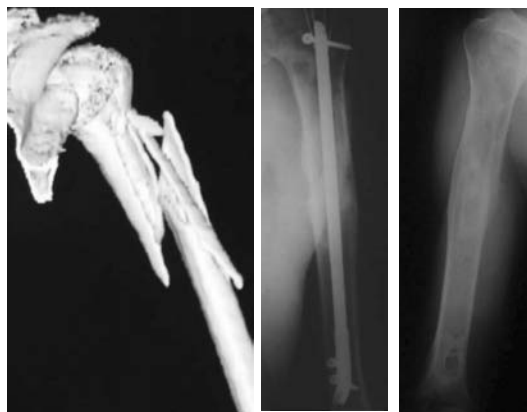
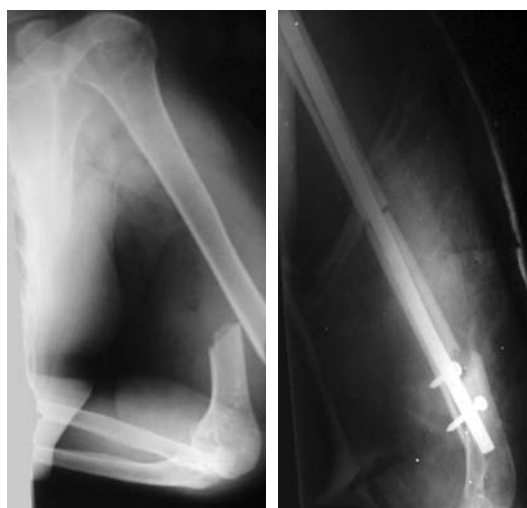

Figure: 2A. Radiographic appearance of humeral diaphyseal fracture, type C1, in a 63 year-old patient. 2B. Details of the osteosynthesis with blocked intramedullary nail (Flexnail-type) through retrograde port. 2C. Final outcome showing fracture union.



Figures 3A and 3B: Retrograde nail used for transverse fracture. A fracture occurred at the nail insertion site.

From those 27 patients, five complained about pain in the shoulder and only in one an abduction limitation was seen. Temporary palsy of the radial nerve was seen in two patients. Only one of them presented pseudoarthrosis and, 5 months following surgery, a new surgical procedure was indicated with the use of plate and autologous bone graft.

DISCUSSION

The gold standard for surgical treatment of humeral diaphyseal fractures is osteosynthesis with plates^(1,2), applying the osteosynthesis principle with absolute stability in simple trait fractures and relative stability in complex fractures. McCormack et al.⁽¹⁾, based on a prospective and randomized study, recommend the use of plates because of the higher complication rates with the use of intramedullary nails. On the other hand, in a similar study, Chapman et al.⁽³⁾ did not find a significant difference in union rate, although there was a higher number of complications with the use of nails. However, with the development of blocked intramedullary nails, the outcomes of more recent studies are showing union rates very close to those achieved with plates^(4,5,6,7,8). Critical analysis of the methodology used in these studies, in turn, shows that most of them are retrospective and based on cases series, that's why they are considered as studies with poor scientific evidences⁽⁹⁾.

Due to the small number of prospective and randomized studies comparing the efficiency of osteosynthesis with plates to intramedullary nails on humeral diaphyseal fractures, it is concluded that available data are still not sufficient to bring to a definitive conclusion based on scientific evidences⁽¹⁰⁾.

Regarding the access port for intramedullary nail introduction, Rommens et al.⁽¹¹⁾ do not report significant differences between anterograde and retrograde ports concerning union rates and complications frequency. As opposite, Scheerlink and Handberg⁽¹²⁾, and Blum et al.⁽¹³⁾ report a higher incidence of pain in the shoulder

with the anterograde port. This is mainly due to the transgression of the rotator cuff, a complication that might be minimized by the development of more modern nails which could avoid rotator cuff injuries due to the possibility of constructing the insertion point at a distal plane to the major humeral tuberosity. In our series, we found a higher incidence of pain in the shoulder with the anterograde port. Differently from the findings in literature, in our study, we had a high rate of fractures at the insertion point of retrograde intramedullary nails. This happened to 4 female patients, showing that probably due to the narrower diameter of the medullary channel, a higher level of care is required in construction the insertion point and introducing the nail.

Excluding the 4 cases of fracture at the nail insertion point, the union rate for the other 27 patients was very close to that found

in literature. Still regarding complications, two patients developed temporary palsy of the radial nerve, showing regression after 4 weeks. This complication was similar to that described by Blum et al.⁽¹⁴⁾ and it is attributed to the manipulations for indirect reduction of the fracture.

CONCLUSIONS

1. The use of blocked intramedullary nails for osteosynthesis of humeral diaphyseal fractures presents a high union rate.
2. The use of blocked intramedullary nails through retrograde access port can lead to fractures in its insertion point.
3. Anterograde access port with rotator cuff transgression can cause pain in the shoulder.

REFERENCES

01. McCormack RG, Brien D, Buckley RE. Fixation of fractures of the shaft of the humerus by dynamic compression plate or intramedullary nail. A prospective randomized trial. *J Bone Joint Surg Br* 2000; 82:336-9.
02. Treatment of humeral shaft fractures : intramedullary nails versus plate fixation. *Orthop. Trauma Directions*. 1:15-20, 2003.
03. Chapman JR, Henley BM, Agel J, Benca PJ. Randomized prospective study of shaft fracture fixation. Intramedullary nails versus plates. *J Orthop Trauma* 2000; 14:407-15.
04. Lin J, Hou SM. Antegrade locked nailing for humeral shaft fractures. *Clin Orthop* 1999; 365:201-10.
05. Lin J, Hou SM, Hang YS. Treatment of humeral shaft delayed unions and non-unions with humeral locked nails. *J Trauma* 2000; 48:695-703.
06. Ajmal M, O'Sullivan M, McCabe J. Antegrade locked intramedullary nailing in humeral shaft fractures. *Injury* 2001; 32:692-4.
07. Rommens PM, Verbruggen J, Broos PL. Retrograde locked nailing of humeral shaft fractures; a review of 39 patient. *J Bone Joint Surg Br* 1995; 77:84-9.
08. Zatti G, Teli M, Ferrario AJ. Treatment of closed humeral shaft fractures with intramedullary elastic nails. *J Trauma* 1998;45:1046-50.
09. Hanson BP, Dettori JR. Intramedullary nailing of shaft fractures. AO recommended literature. *Gen Orthop Trauma* 2002; 3:8-10.
10. Norvell DC, Dettori JR. Randomized prospective study of humeral shaft fracture fixation – Intramedullary nail versus plates. AO Recommended Literature. *Gen Orthop Trauma* 2000; 1:6-13.
11. Rommens PM, Endrizzi DP, Blum J, White RR. Humerus shaft. In: Rüedi TP, Murphy W. *Ao principles of fracture management*. Stuttgart:Thieme, 2000. p. 291-305.
12. Scheerlinck T, Handelberg F. Functional outcome after intramedullary nailing of humeral shaft fractures. Comparison between retrograde Marchetti-Vicenzi and unreamed AO antegrade nailing. *J Trauma* 2002; 52:60-71.
13. Blum J, Janzing H, Gahr R. Clinical performance of new medullary humeral nail antegrade versus retrograde insertion. *J Orthop Trauma* 2001; 15:342-9.
14. Blum J, Rommens PM, Jazing H, Langendorff HS. Retrograde nailing of humeral shaft fractures with the unreamed humerus nail. An international multicenter study. *Unfallchirurg* 1998; 101:342-52.