

# NEUROMUSCULAR ELECTRIC STIMULATION IN HETEROTROPIC OSSIFICATION REGRESSION

DANIEL BECHARA JACOB FERREIRA<sup>1</sup>, HENRIQUE CAMBRAIA LIPPELT<sup>1</sup>, ALBERTO CLIQUET JÚNIOR<sup>2</sup>

## SUMMARY

Heterotropic ossification is a common complication after spinal cord injury. Gradual advancements in the physiopathology and rehabilitation fields, and new treatment methods are a hope for the recovery of the clinical picture of injured individuals in the near future. The objective of this study was to evaluate the heterotropic ossification response of the thigh-femoral joints to neuromuscular electric stimulation in tetraplegic patients after rachial-medullar trauma. Six patients were submitted to neuromuscular electric stimulation for an average period of

16.6 months, being evaluated for X-ray imaging. Improvements on X-ray images were identified in two patients and the non-progression of the picture was observed in the remaining patients. Neuromuscular electric stimulation in spinal cord-injured individuals could be a useful method for treating heterotropic ossification and related progression prevention.

**Keywords:** Ossification heterotropic; Spinal cord injuries; Electric stimulation.

## INTRODUCTION

According to the World Health Organization, trauma is currently the major cause of death and disability among young patients. Despite prevention campaigns, it still reaches high levels, being frequently correlated to spinal cord injuries. This results in devastating consequences, especially from an economical and emotional perspective to that portion of the population, who are usually economically active <sup>(1)</sup>.

The gradual advancement achieved both in the early handling of a politraumatism patient and in a better understanding of the physiopathology of the spinal cord injury, with rehabilitation protocols, genic therapy, and researches on the use of stem cells for replacing injured tissues of the spinal cord, has contributed for patients' functional recovery, with a potential of injury reversion in the near future <sup>(2,3)</sup>. For this recovery and rehabilitation to be optimized, complications

originated by the spinal cord injury must be avoided. One of the most common complications is the heterotropic ossification (HO), with an incidence of 40-50% in those patients, with 10-20% in this group developing a more severe form, which may require surgical treatment <sup>(4)</sup>. About 3 – 8% evolve to ankylosis<sup>(5)</sup>.

HO etiology remains controversial. One theory is based on the production of bone morphogenetic proteins (BMPs) which will act in primitive mesenchymal cells that are able to differentiate into osteoblasts causing an ectopic bone production <sup>(6)</sup>.

Treatment for HO mentioned in literature is divided into prophylactic and therapeutic methods, such as: bisphosphonates, indomethacin, radiotherapy, and surgery <sup>(4,7)</sup>.

Bisphosphonates act by inhibiting the precipitation of calcium phosphate, blocking its conversion into hydroxyapatite. The EHDP is one of the most employed ones,

Study conducted by the Department of Orthopaedics and Traumatology (D.O.T.) – Medical Sciences College (F.C.M.) – Campinas State University (UNICAMP)

Correspondences to: Alberto Clíquet Júnior - D.O.T. – F.C.M. – UNICAMP - Caixa Postal 6011 – Cep 13083-970 - Campinas – São Paulo - E-mail: cliquet@fcm.unicamp.br

1. Resident doctor of the Department of Orthopaedics and Traumatology.

2. Chairman of the Department of Orthopaedics and Traumatology.

Received in: 08/11/05; approved in: 08/19/05

and must be administered at a dosage of 20mg/kg/day for a six-month period (7).

Indomethacin is used as a prophylactic method, acting on the inhibition of prostaglandins synthesis. Its most frequent use is after surgical procedures, such as total hip arthroplasty, at a dosage of 25mg t.i.d. for six weeks (8). Radiotherapy has been used more recently as a primary treatment in early HO in patients with spinal cord injuries. Current studies results have shown the non-progression of the picture in the majority of patients (9). It prevents precursor cells conversion into bone tissue-forming cells, in lower dosages of 200 cGy / day for five days (10).

Surgery is recommended for repositioning the limb and joint motion gain, preferably in the first six months after that picture is established (11).

Today, a number of research projects are being developed on the use of neuromuscular electric stimulation (NMES) in patients initiating gait restoring (12). The objective of this study is to evaluate the NMES impact as an additional therapeutic option in tetraplegic patients aiming the HO reversion on hip joint.

## MATERIALS AND METHODS

Twenty one tetraplegic patients admitted in the Biomechanics and Rehabilitation of the Locomotive Apparatus laboratory of Hospital das Clínicas, UNICAMP (Campinas State University) were assessed.

Regarding the ethical aspects of the research, this study was in compliance with the rules of the Committee on Ethics in Human Experiments of this institution, with participants executing the Free and Informed Consent term.

All patients were submitted to X-ray evaluation of the hips (anteroposterior and Lauenstein planes) prior to neuromuscular electric stimulation, being divided into groups regarding the presence of heterotropic ossification on the hips, divided into grades I, II, III or IV, employing Brooker's scale (13).

The patients were submitted to a neuromuscular electric stimulation program.

**Neuromuscular stimulation system:** An 4-channel electric stimulator was used for quadriceps contraction. Stimulation parameters were: bipolar single-phase wave, duty cycle 4/12, frequency of 25 Hz, duration of one pulse train of 300  $\mu$ s, amplitude of up to 250V (1 k $\Omega$  load).

**Drills Program:** Each patient took part of a drill program consisting in 20-minute neuromuscular electric stimulation sessions, twice a week.

Program evaluation was performed in the group of patients presenting HO at the early X-ray images, who had participated in the stimulation program for at least 12 months, totaling a number of 6 patients.

After drills period, whose patients were reassessed for X-ray status, by comparing baseline hips X-ray images (anteroposterior + Lauenstein) to those taken after the stimulation program.

## RESULTS

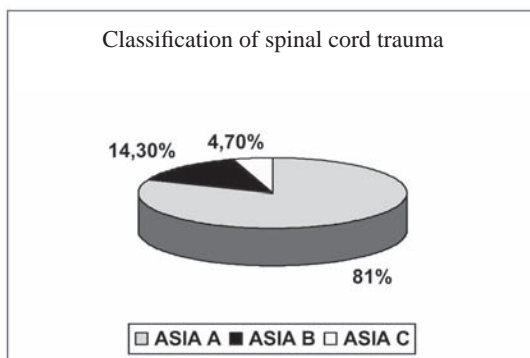
Mean age of patients was 31.7 years, ranging from 20 to 58 years old.

Regarding the neurological evaluation and classification

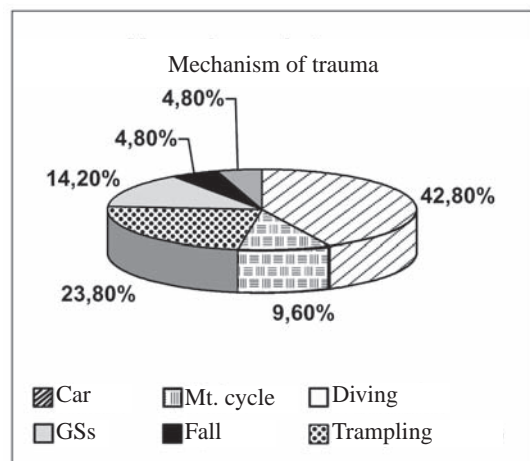
of spinal cord trauma, according to the American Spine Injury Association (ASIA), 81% of the patients were graded as grade A, 14.3% as grade B, and 4.7% as grade C (Figure 1).

The most common mechanism of trauma was traffic accidents, accounting for 52.4% of the cases (42.8% car, 9.6% motorcycle), followed by shallow diving accounting for 23.8%, and then followed by gunshots (GS) with 14.2% of the cases, high falls 4.8%, and trampling 4.8% (Figure 2). Of the 21 patients admitted by the laboratory, 13 (61.9%) presented with heterotropic ossification at baseline X-ray images.

Using the Brooker's scale, 71.41% of the patients were graded as type I, 7.15% as type II, 14.29% as type III, and 7.15% as type IV (Figure 3). The NMES time for patients meeting comparison criteria ranged from 12 to 32 months, resulting in an average of 16.66 months.



**Figure 1** - Distribution of grades suggested by ASIA classification for patients admitted in the service.



**Figure 2** - Traffic accidents were the major cause of spinal cord trauma in assessed patients.

Among the 6 assessed patients, two presented with improvements at X-ray images, and the remaining 4 patients didn't show any improvement, but, on the other hand, their clinical picture remained steady (Figure 4).

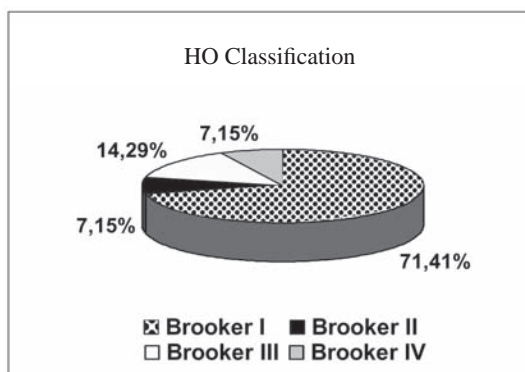
## DISCUSSION

The mean age of the patients in the study agrees with literature. It was observed that spinal cord trauma occurs in an age group that is economically active, causing a strong social and economic impact <sup>(1)</sup>.

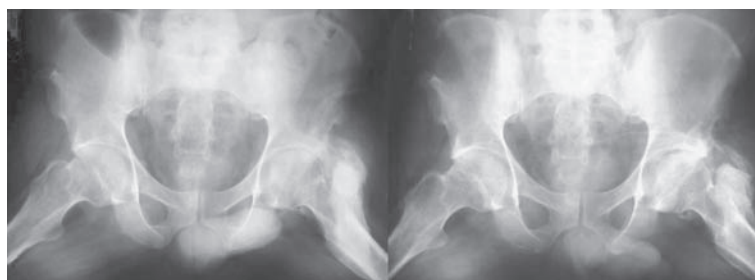
Neurological classification of the spinal cord trauma (as per ASIA) in patients and mechanisms of trauma: car accidents and GSs were compatible

to the average mentioned in literature <sup>(1,14)</sup>. There was only a subtle difference, at the comparison, regarding shallow diving and high falls <sup>(1)</sup>.

HO incidence in patients' X-ray images at baseline was also in accordance to literature references <sup>(15)</sup>. Even by the small number of assessed patients, the follow-up and the electric stimulation time are one of the highest in literature. The non progression of the picture for the remaining subjects is a fact deserving further considerations, suggesting



**Figure 3** - Heterotrophic ossification, in the 21 patients of the study, according to Brooker's scale.



**Figure 4** - X-ray images of hips, at Lauenstein plane, of the same patient showing Brooker's grade-III HO regression, after 32 months of NMES.

that NMES could be a protection factor for heterotrophic ossification occurrence. Another factor that should be further studied is that an even more significant improvement of the picture is directly correlated to the stimulation time, thus, a longer follow-up could provide outcomes that could be even more promising.

## CONCLUSION

This study suggests that the neuromuscular electric stimulation in tetraplegic patients with heterotrophic ossification may be a prophylactic and therapeutic treatment method, which might contribute to its regression or to prevent its development.

If the NMES program in joint motion rehabilitation and maintenance is accepted as worthy, one should take into consideration that better results could be achieved with a longer treatment period, with patient's full compliance with the recommended treatment being crucial.

## ACKNOWLEDGEMENTS

The authors acknowledge the support provided by the São Paulo State Research Support Foundation (FAPESP).

## REFERENCES

- Defino HLA, Zardo EA. Trauma Raquimedular. In: Hebert S, Xavier R. Ortopedia e Traumatologia Princípios e Prática. 3ªed. Porto Alegre: Artmed; 2003. p. 942-51.
- de Barros EM, Cristante AF, Palma RM, dos Santos CV, Marcon RM. An experimental model for the transplantation of fetal central nervous system cells to the injured spinal cord in rats. Rev Hosp Clin Fac Med São Paulo. 2002; 57:257-64
- Fischer D, Kurpysz M, Siminiak T. Stem cell therapy as the reinforcement of organ regeneration. Artif Organs. 2005; 29:366-8.
- Banovac K, Williams JM, Patrick LD, Levi A. Prevention of heterotrophic ossification after spinal cord injury with COX-2 selective inhibitor (rofecoxib). Spinal Cord. 2004; 42:707-10.
- van Kuijk AA, Geurts AC, van Kuppevelt HJ. Neurogenic heterotrophic ossification in spinal cord injury. Spinal Cord. 2002; 40:313-26.
- Banovac K, Sherman AL, Estores IM, Banovac F. Prevention and treatment of heterotrophic ossification after spinal cord injury. J Spinal Cord Med. 2004; 27:376-82.
- Garland DE. A clinical perspective on common forms of acquired heterotrophic ossification. Clin Orthop. 1991; 263:13-29.
- Schmidt SA, Kjaersgaard-Andersen P, Pedersen NW, Nielsen JB. The use of indomethacin to prevent the formation of heterotrophic bone after total hip replacement. A randomized, double-blind clinical trial. J Bone Joint Surg Am. 1988; 70:834-8.
- Sautter-Bihl ML, Liebermeister E, Nanassy A. Radiotherapy as a local treatment option for heterotrophic ossifications in patients with spinal cord injury. Spinal Cord. 2000; 38:33-6.
- van der Werf GJ, van Hasselt NG, Tonino AJ. Radiotherapy in the prevention of recurrence of paraarticular ossification in total hip prostheses. Arch Orthop Trauma Surg. 1985; 104:85-8.
- Garland DE, Orwin JF. Resection of heterotrophic ossification in patients with spinal cord injuries. Clin Orthop. 1989; 242:169-76.
- Ortolan RL, Cunha FL, Carvalho DC, Franca JE, Santa Maria AS, Silva OL et al. Tendências em biomecânica ortopédica aplicadas à reabilitação. Acta Ortop Bras. 2001; 9:44-58.
- Brooker AF, Bowerman JW, Robinson RA, Riley LH Jr. Ectopic ossification following total hip replacement. Incidence and a method of classification. J Bone Joint Surg Am. 1973; 55:1629-32.
- Taly AB, Nair KP, Jayakumar PN, Ravishankar D, Kalaivani PL, Indiradevi B, et al. Neurogenic heterotrophic ossification : a diagnostic and therapeutic challenge in neurorehabilitation. Neurol India. 2001; 49:37-40.
- Heilbuoss N, Kuhn Jr WG. Erosive bone lesions and soft tissue ossification associated with spinal cord injuries (paraplegia). Radiology. 1947; 48:579-85.