

# TREATMENT OF PELVIC AND ACETABULAR FRACTURES THROUGH MODIFIED STOPPA PORT

DANIEL BALBACHEVSKY<sup>1</sup>, ROBINSON ESTEVES SANTOS PIRES<sup>2</sup>, FLÁVIO FALOPPA<sup>3</sup>, FERNANDO BALDY DOS REIS<sup>4</sup>

## SUMMARY

This study describes the modified Stoppa access port for treating fractures on pelvic anterior region and fractures affecting the acetabulum anterior column. In this access port, a suprapubic cross-sectioned incision is performed on skin, longitudinal opening of the abdominal rectus muscle with lateral displacement of venters, and subperiosteal bone dissection through the medial surface of the hemipelvis addressed, so that implant materials can be placed on that inner surface. This access port, little used in our area, presents advantages over

the traditional ports, such as the ilioinguinal and iliofemoral, due to the potential for a smaller surgical wound and soft parts dissection, enabling implants to be placed directly on quadrilateral layer, achieving a stable fixation and reducing the risks of infection and injuries to neurovascular structures. As a result of current literature and of the experience of the authors with the use of that access port, we can conclude that it is a good alternative for accessing those fractures.

**Keywords:** Pelvis; Acetabulum; Fractures.

## INTRODUCTION

Unstable pelvic fractures and hip fractures accompanied by incongruence or joint instability have been surgically treated since 1964, with the first studies being conducted by Judet e Letournel<sup>(1)</sup>. Although they represent only 3-8% of the total fractures of the body, pelvic injuries account for a mortality rate of up to 20%<sup>(2)</sup>. Acetabular fractures affecting the anterior column, alone or associated to other regions of the acetabulum, represent about 67% of those fractures, and infection rates associated to the ilioinguinal access port can reach to 30%<sup>(3,4)</sup>.

Those fractures require a careful surgical approach, because they are near some structures such as the urinary bladder, spermatic funicle or round ligament, and, in cases of joint or per-articular fractures, care should be taken with femoral nerve and vessels, as well. A stable internal fixation, with anatomic joint reduction in cases of joint fractures, should be the objectives of treatment, and may be achieved through a number of methods.

Traditional access ports used in fractures of the anterior region of the pelvis and of the anterior column of the acetabulum are Pfannestiel, ilioinguinal e iliofemoral, with the last two being related to a higher risk of bleeding and additional soft parts and neurovascular structures injuries. Another difficulty found in fixating those fractures is in selecting the site for placing implants, moreover on juxta-articular fractures and on quadrilateral layer fractures.

## Many techniques have already been described for fixation:

Letournel and Judet<sup>(5,6)</sup> described the quadrilateral layer

fixation with screws inserted along it, through ilioinguinal or iliofemoral ports. Tile<sup>(4,7)</sup> described the use of small "T"-shaped fragments plates, or double 3.5 mm reconstruction plates, acting as a "spring-plate" on quadrilateral layer, helping on reduction and avoiding acetabular protrusion. Mast et al.<sup>(8)</sup> described a similar technique, with a tubular 1/3 plate, placed beneath a reconstruction plate at the iliopectineal line, towards the quadrilateral layer, with the same purpose.

Mears and Rubash<sup>(9)</sup> described the use of cerclage threads tied on the supra-acetabular region, associated to cortical-spongy bone graft of the ipsilateral iliac crest, also intending to avoid acetabular protrusion. Tidermark et al.<sup>(10)</sup> recommended the primary total arthroplasty of the hip with cage against acetabular protrusion and bone graft for derived acetabular fractures in elderly patients and in those with osteoporosis, in whom the osteosynthesis failure rate is potentially high.

Hirvensalo et al.<sup>(11)</sup> and Cole and Bolhofner<sup>(12)</sup> modified the Stoppa port<sup>(13)</sup>, first described for treating abdominal hernias, now addressing pelvic and hip fractures, respectively. Based on those authors' experience, we felt motivated to perform and describe this technique, which is performed by longitudinal divulsion of the abdominal rectus, bone dissection through the inner surface of the pelvis, enabling to place implants beneath the pectineal line, as well as on the quadrilateral layer<sup>(11,12,14)</sup>. In addition to facilitate implants placement, this access does not directly address femoral vessels and nerve, thigh's lateral skin nerve, spermatic funicle, or round ligament, thus reducing potential risks of iatrogenic neurovascular injuries, additional injuries to soft parts, the amount of bleeding and surgical time.

Study conducted at Hospital São Paulo by the Discipline of Traumatology, Department of Orthopaedics and Traumatology, Federal University of São Paulo - Paulista Medical School.

Correspondences to: Rua Borges Lagoa, 783 - 5º andar - Vila Clementino - São Paulo - SP - CEP 04038-032 - E-mail: danbal61@hotmail.com

1 - Post-graduation student, Discipline of Traumatology, Department of Orthopaedics and Traumatology, Federal University of São Paulo.

2 - Post-graduation student, Discipline of Traumatology, Department of Orthopaedics and Traumatology, Federal University of São Paulo. Orthopaedic doctor at Hospital Felício Rocho (Belo Horizonte - MG).

3 - Chairman and Head of the Department of Orthopaedics and Traumatology, Federal University of São Paulo.

4 - Associate Professor, Discipline of Traumatology, Department of Orthopaedics and Traumatology, Federal University of São Paulo

Received in: 03/12/06; approved in: 04/19/06

The objective of this study is to describe the performance of the modified Stoppa access port in the treatment of fractures on pelvic anterior region and on acetabular fractures compromising the anterior column, placing implants at the lower pectineal region.

## MATERIALS AND METHODS

### X-Ray Studies:

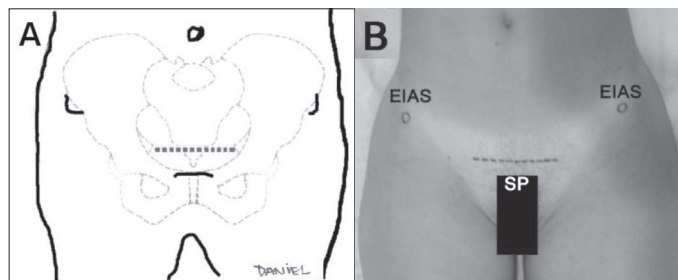
X-ray images at anteroposterior, *inlet* and *outlet* planes for pelvic fractures, and at anteroposterior, alar and obturator for hip fractures, as well as computed tomography imaging are essential for diagnosing and understanding injuries to be treated, and are part of surgical planning for treating those fractures.

### Surgical instruments:

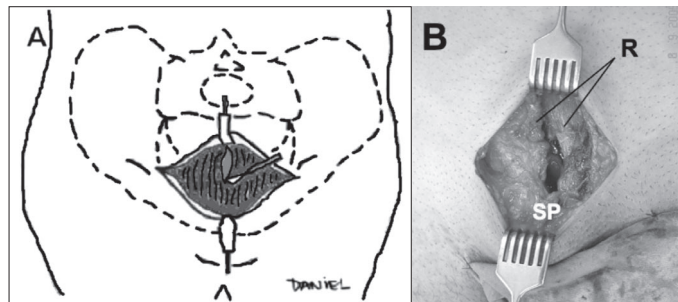
The implants and surgical instruments for pelvis and acetabulum, with reconstruction plates, specific reduction tweezers, retractors and long drills are indispensable, because they facilitate access, reduction and fixation of those fractures. Also, a radiotransparent table and radioscopy enable intra-operative X-ray control, of which use must be mandatory because we are placing implants near hip joint.

### Positioning and Preparing:

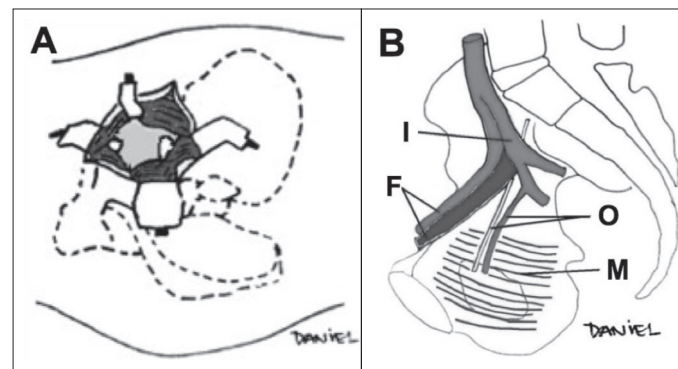
After an antibiotic prophylaxis and the respective anesthetic procedure, the patient is placed with a probe at dorsal decubitus, and pelvic antisepsis and trichotomy is performed, from navel throughout the thigh proximal third. In cases of acetabular fractures, the ipsilateral lower limb is also submitted to antisepsis to enable reduction maneuvers.



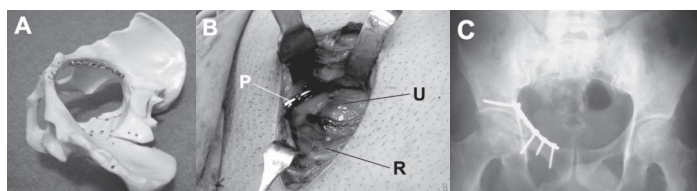
**Figure 1** – (A) Schematic figure, and (B) clinical example showing skin incision site, 2 cm proximal to pubic symphysis. (EIAS = anterosuperior iliac spine, SP = pubic symphysis).



**Figure 2** – (A) Schematic figure, and (B) clinical example of access port, showing the cross-sectional suprapubic incision and longitudinal aperture of the abdominal rectus muscle (R). (SP = pubic symphysis).



**Figure 3** – Schematic figures showing (A) right hemipelvis in an oblique view, in which the abdominal rectus muscle was laterally retracted and the bladder was posteriorly retracted, enabling access to iliopubic branch and quadrilateral layer. (B) Internal appearance of the pelvis, showing neurovascular and muscular structures. (I = internal iliac artery, F = femoral vessels, O = obturator artery and nerve, and M = internal obturator muscle).



**Figure 4** – (A) Bone model showing a reconstruction plate placed at the infrapectineal region on the right. (B) Intra-operative detail of the access port in a fracture of the right acetabulum's anterior column (P = plate, U = bladder, R = abdominal rectus muscle). (C) Post-operative X-ray image showing the reconstruction plate placed on infrapectineal region.

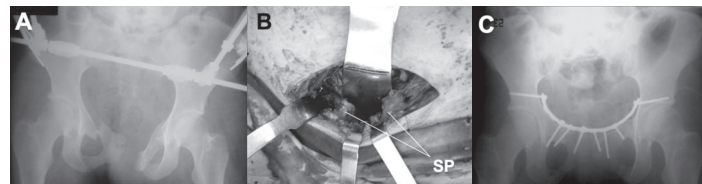
### Access Port:

The surgeon is positioned at the opposite side to the fracture in order to open the port, which starts with a cross-sectioned incision on skin and subcutaneous cellular tissue, 2 cm proximal to pubic symphysis, approximately 6 - 10 cm long (Figure 1). A median longitudinal wound is then performed between abdominal rectus venters, with lateral retraction of those, bladder identification and protection, which is retracted posteriorly with the aid of pads and a flexible spatula (Figures 2 and 5B). Now, we can palpate the pubic symphysis and the bone dissection is subperiosteally performed, inferior to the iliopectineal line, from the pubic posterior surface throughout the quadrilateral layer, enabling access to even the lower portion of sacroiliac joint (Figure 3A). During this bone dissection, one must be cautious with femoral vessels, which are located above the pectineal line, with internal iliac vessels, more medial and distant from quadrilateral layer, with the obturator nerve and vessels, which are directed towards the obturator foramen, as well as occasional anastomosis between lower epigastric vessels and obturators (*corona mortis*), which must be identified and linked in case they are present (Figure 3B).

### Osteosynthesis:

Fractures on iliopubic branches, anterior wall or column, or on quadrilateral layer are viewed, and the reduction may be achieved by means of traction maneuvers or with the aid of ball-spike pusher instruments or other reduction tweezers, laid on the quadrilateral layer. Temporary fixation may be made with

2.0mm Kirschner wire and hip flexion may be required to enable reduction. After fracture reduction, one or more 3.5 mm reconstruction plates are placed at the lower pectineal region or on the quadrilateral layer, and must be molded so as to follow pelvic curvature (Figure 4). The plate is then fixed at the posterior region, above major ischiatic incisure, as well as at the posterior surface of the iliopubic branch, and may be extended to up to contralateral hemipelvis, depending on fracture pattern (Figure 5). No screws should be placed on the quadrilateral layer due to a higher risk of penetration into hip joint space. The quality of implants' reduction and positioning are confirmed by X-ray images or by radioscopy. Hemostasis is then performed, followed by an aspiration drain inserted next to implants and at the retropubic space, abdominal rectus muscle's venters closure, subcutaneous cellular tissue and skin.



**Figure 5** – (A) X-ray image of a patient's pelvis showing disjunction of the pubic symphysis associated to fractures of the iliac and bilateral ischiopubic branches, which was early treated by external fixation. (B) Intra-operative photograph of the access port after abdominal rectus opening, bladder protection with a flexible spatula and injury exposure (PS = pubic symphysis). (C) Postoperative X-ray image showing osteosynthesis with a reconstruction plate placed on infrapectineal region.

## DISCUSSION

Pelvic unstable fractures affecting the anterior region, and the fractures of acetabulum's anterior column represent a challenge for traumatologists. A number of fixation methods and surgical tactics have been described for treating those fractures, with the ilioinguinal port being performed by the majority of surgeons and showing a potential to high complication rates<sup>(7,8,9,14,15)</sup>. The modified Stoppa's port was advocated by Hirvensalo et al.<sup>(11)</sup> for applying an infrapectineal plate for the treatment of anterior injuries of the pelvic ring. That same port was described by Cole and Bolhofner<sup>12</sup> for treating fractures of the acetabulum's anterior column involving quadrilateral layer.

As it has been described in literature, this access port provided good outcomes in our experience, with no infection episodes, excessive bleeding or cases of lost reduction, also reducing surgical time compared to the ilioinguinal port. We believe that this access port and the fixation technique are useful for fractures on acetabulum's anterior column or wall, as well as for cross-sectioned fractures, for "T-shaped" fractures, fractures on the anterior column associated to posterior hemitransversal and for fractures on both columns, and may be performed alone, in conjunction with the proximal portion of the ilioinguinal port or with the posterior port. It is particularly biomechanically advantageous in those cases when femoral head migrates medially (10 - 15%)<sup>(6)</sup>, forcing quadrilateral layer against inner pelvis. It is also shown to be advantageous in complex fractures of pelvic anterior region extending to periarticular region, requiring an extensive surgical port when addressed by traditional ilioinguinal port.

Therefore, the modified Stoppa's port has the advantages of a smaller surgical incision and soft parts dissection, which reduces risks of complications and allows for placing implants directly at the internal surface of the pelvis, optimal for fractures affecting acetabulum's anterior column and for complex fractures of pelvic anterior region.

To date, this technique seems promising to us, nevertheless the number of operated patients and our limited clinical follow-up do not enable us to draw a definite conclusion. Thus, in our service, we are developing a study design for comparing this access port to the ilioinguinal one, with the purpose of checking our early impressions.

## REFERENCES

- Judet R, Judet J, Letournel E. Fractures of the acetabulum. Classification and surgical approaches for open reduction: preliminary report. *J Bone Joint Surg Am.* 1964; 46:1615-38.
- Pohleman T, Tscherne H, Baumgartel F, Egbers HJ, Euler E, Maurer F, et al. Pelvic fractures: epidemiology, therapy and long-term outcome. Overview of the multicenter study of the Pelvis Study Group. *Unfallchirurg.* 1996; 99:160-7.
- Giannoudis PV, Grotz MRW, Papakostidis C, Dinopoulos H. Operative treatment of displaced fractures of the acetabulum. A meta-analysis. *J Bone Joint Surg Br.* 2005; 87:2-9.
- Tile M. Fractures of the pelvis and acetabulum. 3rd ed. Philadelphia: Williams & Wilkins; 2003.
- Letournel E, Judet R. Fractures of the acetabulum. 2nd ed. New York: Springer-Verlag; 1993.
- Letournel E. Acetabulum fractures: classification and management. *Clin Orthop.* 1980; 151:81-106.
- Tile M. Fractures of pelvis and acetabulum. 2nd ed. Baltimore: Williams & Wilkins; 1995.
- Mast J, Jakob R, Ganz R. Planning and reduction techniques in fracture surgery. Berlin: Springer-Verlag; 1989.
- Mears DC, Rubash HE. Pelvic and acetabular fractures. Thorofare: Slack; 1986.
- Tidermark J, Blomfeldt R, Ponzer S. Primary total hip arthroplasty with a Burch-Schneider antiprotusion cage and autologous bone grafting for acetabular fractures in elderly patients. *J Orthop Trauma.* 2003; 17: 193-7.
- Hirvensalo E, Lindahl J, Bostman O. A new approach to the internal fixation of unstable pelvic fractures. *Clin Orthop.* 1993; 297:28-32.
- Cole JD, Bolhofner BR. Acetabular fracture fixation via a modified Stoppa limited intrapelvic approach: description of operative technique and preliminary treatment results. *Clin Orthop.* 1994; 305: 112-23.
- Stoppa RE. The treatment of complicated groin and incisional hernias. *World J Surg.* 1989; 13:545-54.
- Qureshi AA, Archdeacon MT, Jenkins MA, Infante A, DiPasquale T, Bolhofner BR. Infrapectineal plating for acetabular fractures: a technical adjunct to internal fixation. *J Orthop Trauma.* 2004; 18:175-8.
- Letournel E. The treatment of acetabular fractures through the ilioinguinal approach. *Clin Orthop.* 1993; 292:62-76.