

BONE MARROW STEM CELLS AND PLATELET-RICH PLASMA EFFECTS ON NERVOUS REGENERATION AND FUNCTIONAL RECOVERY IN AN ACUTE DEFECT MODEL OF RATS' PERIPHERAL NERVE

JEFFERSON BRAGA-SILVA¹, DANIEL GEHLEN⁶, JAVIER A. ROMAN², CAROLINE MENTA⁶, EDUARDO DE ANDRADE ATKINSON⁶, DENISE CANTARELLI MACHADO³, CHRISTIAN VIEZZER⁶, GUSTAVO LEIVAS BARBOSA⁶, CRISTIANE VON WERNE BAES⁶, VINÍCIUS DUVAL SILVA⁴, JADERSON COSTA DA COSTA⁵

SUMMARY

Objectives: The effects of the use of bone marrow stem cells (MSC) and platelet-rich plasma (PRP) on peripheral nerves regeneration were assessed by using an established model of sciatic nerve regeneration in rats. **Methods:** A 10-mm nervous defect was reconstructed by using a silicone tube filled with MSC, PRP or both. The control group received only the silicone tube. A fifth group was also set, in which the interval was reconstructed by using a dried segment of the nerve. Motor function was tested six weeks after surgery, by means of a gait test. After motor test, the rats were anesthetized, the

sciatic nerve and the tube were dried, and the transmission electronic microscopy was performed. **Results:** The quantitative analysis shows an improved functional recovery in MSC group compared to the other groups. Nervous regeneration was reported for MSC group by means of transmission electronic microscopy with an almost full recovery of the neural anatomy. **Conclusion:** Our results suggest that the use of MSC combined with tubing technique yields a satisfactory recovery of motor function and nervous regeneration.

Keywords: Stem Cells; Peripheral Nerves; Models, Animal.

Citation: Braga-Silva J, Gehlen D, Roman JA, Menta C, Atkinson EA, Machado DC, et al. Bone marrow stem cells and platelet-rich plasma effects on nervous regeneration and functional recovery in an acute defect model of rats' peripheral nerve. *Acta Ortop Bras.* [serial on the Internet]. 2006; 14(5):273-275. Available from URL: <http://www.scielo.br/aob>.

INTRODUCTION

Although autologous nervous graft is a treatment alternative for nervous injuries in which primary repair cannot be made without using excessive tension, some difficulties exist in using this technique, such as the adjustment of graft's length and diameter. Numerous attempts have been made intending to induce nervous regeneration in nerve defects using non-biological materials, such as silicone tubes^(1,2,3). However, non-biological materials' ability to induce nervous regeneration has been considered inappropriate, and the development of artificial nerves combining cells, such as the Schwann's cells^(4,5) and neurotrophic factors^(6,7) together with non-biological materials has currently been broadly used. The objective of the present study was to assess the effect of bone marrow cells, platelet-rich plasma, and the combination of both on peripheral nerves regeneration compared to techniques currently in use for peripheral nerves injuries treatment.

MATERIALS AND METHODS

Isolation and Culture of Bone Marrow Stem Cells

The isolation of bone marrow stem cells was performed after a lethal dose of Ketamin and Chloropromazin was administered. Tibia and femur were dissected. The marrow was removed with 1 ml DBPS (Gibco TM, Invitrogen Corporation, Carlsbad, CA) using a 0.8X25mm (21 Gauge) needle. Bone marrow stem cells were washed twice with 1 ml DBPS for centrifugation means for 30 seconds at 700 G. Then, cells were re-suspended at a density of 10⁷cells/ml DBPS.

Preparation of the Platelet-Rich Plasma

The platelet-rich plasma was prepared using a collection obtained by heart puncture with a tube containing sodium citrate. The sample was centrifuged at 160G for 8 minutes and a fraction of 10 mm over erythrocytes, containing a fraction of the rich plasma was removed. Calcium gluconate (10%) was added, and the tube was incubated at 37°C until the

Study conducted at the Hand Surgery and Reconstructive Microsurgery Service, Pontifícia Universidade Católica do Rio Grande do Sul, Brazil and Biomedical Research Institute, Pontifícia Universidade Católica do Rio Grande do Sul, Porto Alegre, Rio Grande do Sul, Brazil

Correspondences to: Av. Ipiranga 6690 - Centro Clínico PUCRS, Sala 216, CEP 90610-000, Porto Alegre, Brasil - Email: jeffmao@terra.com.br

1 - Full Professor, Hand Surgery, UNIFESP.

2 - Orthopaedics and Traumatology doctor.

3 - Biologist, PUC College.

4 - Pathology Professor, Medical School, PUCRS.

5 - Head of Biomedical Research Institute, PUCRS.

6 - Medicine student.

Received in: 04/24/06; approved in: 07/07/06

solution became viscous. Platelet-rich plasma was used for re-suspending stem cells of the bone marrow at a density of 10^7 cells.

Surgical Procedure

Experimental procedures were approved by the Committee on Ethics in our institution and were conducted according to the Guidelines for Research Principles Involving Animals and Human Beings, taking appropriate measures for minimizing pain and discomfort to animals. Forty eight female Wistar adult rats were anesthetized with an intramuscular injection of a solution constituted of Ketamina™ (Ketamin-S(+)) 50 mg/ml 70mg/kg and Xylazine (100mg/ml) 10 mg/kg. The sciatic nerve was accessed on the lateral face of right thigh. A 10-mm segment of the nerve was resected and the defect was immediately reconstructed. The animals were divided into five groups according to the technique used for reconstruction. In groups 1 to 4, defect was reconstructed with a flexible silicone tube (average length: 14 mm, and; average diameter: 0.8 mm). The epineurium was sutured at a point located 2 mm away from tube's end. Nerve's end was completely introduced into tube's lumen, producing a closed compartment. The groups were divided according to the preparation used for priming tube's lumen. Group 1: empty tube (ET); Group 2: bone marrow stem cells (MSC); Group 3: platelet-rich plasma (PRP); Group 4 (MSC + PRP): combination of bone marrow stem cells and platelet-rich plasma. The interval was reconstructed using a resected segment of the nerve as an autograft in group 5 (AG), which was sutured using a conventional technique. Due to results predictability in control groups (1 and 5), the number of animals was half of the established one (n=06) for the remaining experimental groups (n=12). After surgery, all animals remained healthy throughout the study period.

Functional and Histological Analysis

Gait tests were obtained according to Medinaceli's method^(8,9), 10 weeks after surgery. They were measured by using a digitalization

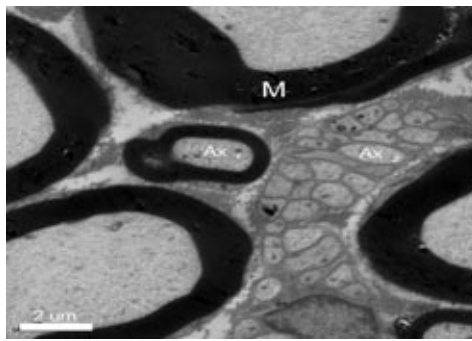


Figure 1 - Transmission electronic microscopy of a nerve in ET group. Cross-section of a nerve showing myelin (M) sheath, some myelinic axons at left central region (Ax 1) and non-myelinic axons at right central portion (Ax 2).

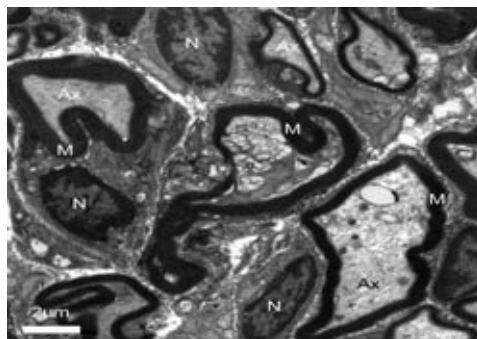


Figure 2 - Transmission electronic microscopy of a regenerated nerve within a tube filled with bone marrow stem cells. Cross-section of a nerve segment within the silicone tube evidencing a large number of myelinic axons (Ax), myelinic sheaths (M) and Schwann cells' nuclei (N).

block connected to a PC using morphometric software. The Sciatic Function Index (SFI) was obtained for each animal. The SFIs from different experimental groups were compared using variance analysis and post-hoc Tukey's test. In all statistical analyses, $p < 0.05$ was regarded as statistically significant. The animals were sacrificed soon after gait tests. Transmission electronic microscopy was used for assessing nerve regeneration within tube filled with MSC and in control group (ET group), in which an empty (without MSC) silicone tube was used (Figures 1 and 2).

RESULTS

The Sciatic Function Index (SFI) was obtained for each animal, 10 weeks after surgical procedure. All groups were compared conjunctively, and also in pairs. The results are shown on Table 1 and Graph 1, as average \pm SD.

The quantitative analysis of SFIs suggests an improved functional recovery in MSC group compared to other groups, which is evidenced by better gait test results, followed by PRP and MSC + PRP groups, which were statistically equivalent. The next best result was seen in the AG group.

The ET group presented the worst results, showing an increased difficulty in recovering motor function.

Nervous regeneration was evidenced in MSC group by means of transmission electronic microscopy showing an almost full neural anatomy recovery. Myelinic and non-myelinic axons were identified in a proper amount inside the tube filled with MSC (Figure 1). In the group using only a silicone tube, regeneration also occurred, but significantly less than previous group. The ET group showed a slower growth and

a lower amount of nervous fibers, as well as a poorer arrangement of those and a lower number of myelinated axons (Figure 2).

DISCUSSION

Human adult stem cells are able to maintain, generate and replace terminally differentiated cells in its specific tissues as a result of physiological cell turnover or tissue regeneration due to injury⁽¹⁰⁾.

Table 1 - Average sciatic function index according to each kind of treatment.

	Treatment Group				
	ET	MSC	PRP	MSC + PRP	AG
AVERAGE	-85.1000	- 27.5164*	- 43.1911	- 41.8642	-51.3200
S.E	0.9798	0.8414	2.0810	1.0630	1.4906
S.D.	0.4000	2.7905	6.2431	3.6825	0.6666

Sciatic Function Index: Measures function loss. The closer it is to zero, the better the gait function.

ET: Empty Tube; MSC: Stem cells derived from Bone Marrow, PRP: Platelet-Rich Plasma; AG: Autograft.

S.E.: Standard Error; S.D.: Standard Deviation

* $p < 0.05$


Recent studies suggest that adult stem cells generate differentiated cells beyond their specific tissue capacities, a process called “developing plasticity”⁽¹¹⁾.

It has been previously evidenced that not only stem cells derived from embryonic or neural tissue⁽¹²⁾, but also other organ-specific stem cells, can generate neural phenotypes^(13,14).

The use of marrow stem cells in cases of peripheral nerves injuries is regarded as one of the most promising alternatives compared to the options available for treating nervous injuries. After all, these fulfill a therapeutic gap between the potential to perform primary repair - often impossible due to a significant nervous loss - and the performance of an autologous autograft, which, in turn, is commonly associated to technical difficulties that preclude the use of such technique by the surgeon. Our study evidences that the use of stem cells not only is a significant alternative, but also shows superior results when compared to other employed techniques. Studies in vivo have proven that bone marrow stem cells have an important regenerative potential after being transplanted in transected sciatic nerves' ends^(15,16).

The present study showed that the functional performance assessed by gait test analysis of rats treated with tubing and bone marrow stem cells was significantly better than any of the other groups. The beneficial effect of PRP was also evidenced. The results of the group MSC + PRP are easy to interpret when compared to MSC and PRP groups.

A possible additional effect of stem cells preparation, when



Graph 1 - Sciatic Function Index of the different groups observed in the study.”

combined with PRP was assessed, since the scores for groups PRP and NSC + PRP were statistically similar. A possible interpretation is that the PRP preparation somehow inhibits MSC effects, either partially or even completely.

Our data suggest that MSC injected into the silicone tube induce Schwann's cells' proliferation and differentiation, promoting a faster and more abundant rege-

neration, with a higher number of myelinated fibers formed, thus enabling a greater functional recovery when compared to studied groups.

CONCLUSION

Our results suggest that the use of rats' bone marrow stem cells combined to tubing technique promotes a better recovery of motor function and a more abundant regeneration in an acute nerve defect model when compared to other groups evaluated in this study.

The exact mechanism accounting for this response is not fully understood. Additional research is necessary for understanding the mechanisms of differentiation occurred within the tube filled with the preparation of adult bone marrow stem cells, able to promote nervous regeneration induction.

The use of autologous adult stem cells is a promising candidate for therapeutic use, and may allow researchers to design clinical studies with reasonable costs, without facing any ethic issue as the use of embryonic stem cells, in addition to avoid immune responses compromising transplants.

REFERENCES

1. Yoshii S, Oka M. Peripheral nerve regeneration along collagen filaments. *Brain Res.* 2001; 888:158-62.
2. Zhao Q, Lundborg G, Danielsen N, Bjursten LM, Dahlin LB. Nerve regeneration in a “pseudo-nerve” graft created in a silicone tube. *Brain Res.* 1997; 769:125-34.
3. Belkas JS, Shoichet MS, Midha R. Peripheral nerve regeneration through guidance tubes. *Neurol Res.* 2004; 26:151-60.
4. Mimura T, Dezawa M, Kanno H, Sawada H, Yamamoto I. Peripheral nerve regeneration by transplantation of bone marrow stromal cell-derived Schwann cells in adult rats. *J Neurosurg.* 2004; 101:806-12.
5. Dezawa M, Takahashi I, Esaki M, Takano M, Sawada H. Sciatic nerve regeneration in rats induced by transplantation of in vitro differentiated bone-marrow stromal cells. *Eur J Neurosci.* 2001; 14:1771-6.
6. Dugrillon A, Eichler H, Kern S, Kluter H. Autologous concentrated platelet-rich plasma (cPEP) for local application in bone regeneration. *Int J Oral Maxillofac Surg.* 2002; 31:615-9.
7. Mazar Z, Peleg M, Garg AK, Luboshitz J. Platelet-rich plasma for bone graft enhancement in sinus floor augmentation with simultaneous implant placement: patient series study. *Implant Dent.* 2004; 13:65-72.
8. De Medinaceli L, Freed WJ, Wyatt AJ. Na index of the functional condition of rat sciatic nerve based on measurements made from walking tracks. *Exp Neurol.* 1982; 77:634-9.
9. De Medinaceli L, Wyatt AJ. Neurobehavioral evaluation of function following experimental nerve damage. *Neurobehav Toxicol Teratol.* 1984; 6: 415-7.
10. Slack JMW. Stem cells in epithelial tissue. *Science.* 2000; 287:1431-3
11. Körbling M, Estrov Z. Adult stem cells for tissue repair - a new therapeutic concept? *N Engl J Med.* 2003; 349:570-82.
12. Murakami T, Fujimoto Y, Yasunaga Y, Ishida O, Tanaka N, Ikuta Y, et al. Transplanted neuronal progenitor cells in a peripheral nerve gap promote nerve repair. *Brain Res.* 2003; 974:17-24.
13. Woodbury D, Schwarz EJ, Prockop DJ, Black IB. Adult rat and human bone marrow stromal cells differentiate into neurons. *J Neurosci Res.* 2000; 61:364-70.
14. Zhao LR, Duan WM, Reyes M, Verfaillie CM, Keene DC, Low WC. Human bone marrow stem cells exhibit neural phenotypes and ameliorate neurological deficits after grafting into the ischemic brain of rats. *Exp Neurol.* 2002; 174:11-20.
15. Choi BH, Zhu SJ, Kim BY, Huh JY, Lee SH, Jung JH. Transplantation of cultured bone marrow stromal cells to improve peripheral nerve regeneration. *Int J Oral Maxillofac Surg.* 2005; 34:537-42.
16. Pereira Lopes FR, Camargo de Moura Campos L, Dias Correa J Jr, Balduino A, Lora S, Langone F, et al. Bone marrow stromal cells and resorbable collagen guidance tubes enhance sciatic nerve regeneration in mice. *Exp Neurol.* 2006; 198:457-68.
17. Cuevas P, Carceller F, Dujovny M, Garcia-Gomez I, Cuevas B, Gonzalez-Corrochano R, Diaz-Gonzalez D, et al. Peripheral nerve regeneration by bone marrow stromal cells. *Neurol Res.* 2002; 24:634-8.