

# OSTEOINTEGRATION OF IMPACTED LYOPHILIZED GRAFTS

CARLOS ROBERTO GALIA, CARLOS ALBERTO DE SOUZA MACEDO, RICARDO ROSITO, LUIS FERNANDO MOREIRA

## ABSTRACT

**Objective:** The purpose of the study was to provide a clinical and X-ray based evaluation of the results and osteointegration ability of lyophilized human and bovine bone grafts. **Methods:** This is a non-concurrent cohort trial of 63 patients (66 hips) submitted to revision total hip arthroplasty (RTHA) using impacted freeze-dried human and bovine cancellous bone grafts. The study was carried out in the Hospital de Clínicas de Porto Alegre from May 1997 to September 2002. The patients were divided in two groups: Group 1 (n=35), composed by those receiving human grafts, and Group 2 (n=31), receiving bovine grafts. The mean follow-up time was 33 months. The grafts were purified and lyophilized using a protocol developed by the authors. The clinical

analysis was based on Merle, d'Aubigné and Postel's scores; while the radiographic analysis was based on an established score for radiographic bone incorporation. **Results:** No clinical or radiographic differences were found between the groups, and both groups showed an overall osteointegration rate of 85% both in the acetabular and in the femoral component. **Conclusions:** Impacted lyophilized human and bovine bone grafts produced by following to the proposed protocol did not cause damage to the patients. Results obtained with both bovine and human grafts were similar.

**Keywords:** Arthroplasty, replacement, hip. Bone transplantation. Freeze drying.

**Citation:** Galia CR, Macedo CAS, Rosito R, Moreira LF. Osteointegration of impacted lyophilized grafts. *Acta Ortop Bras.* [online]. 2009;17(2):24-8. Available from URL: <http://www.scielo.br/aob>.

## INTRODUCTION

Although there are several causes for total hip arthroplasty reviews (THARs), such as infection and instability, the aseptic loosening is the most frequent one, and, most of times, is associated to some degree of reduced bone stock.<sup>1</sup> This makes the creation of tissue libraries and the study of different ways to process and store grafts and bone replacements imperative, considering that to date, the demand for tissues is far beyond its availability.<sup>2</sup>

Motivated by this reality and by the experience of the Hip Surgery Group (GCQ) at Hospital de Clínicas de Porto Alegre (HCPA) with THARs, where the offer of frozen allografts was far beyond the need, we decided to study alternatives for tissue processing for taking a better advantage of human bone grafts, as well as the use of bovine grafts. For this purpose, we started a lyophilization process and, after a survey in literature, experimental studies, physicochemical and structural analyses, and its use in other minor orthopaedic procedures, this clinical trial on THARs was conducted.

The objective of this study was to assess, from a clinical and X-ray imaging perspective, the results and the ability of lyophilized human and bovine bone grafts to integrate to the bone, which were produced according to a protocol developed by the authors using an impacted spongy bone in 66 cemented and non-cemented THAR surgeries.

## MATERIALS AND METHODS

The present study is a non-concurrent cohort. Sixty three patients (66 hips) were consecutively submitted to THAR by the Hip Surgery Group (GCQ) of the Orthopaedics and Traumatology Service of HCPA, university hospital, between May 1997 and September 2004. All hips received pricked and impacted lyophilized bone graft (hydrated for 1 hour) on the femur, acetabulum or both. The grafts were removed from human or bovine bones, and randomly used according to the availability of the warehouse department at the moment of surgical procedure. The patients were divided for later analysis into two groups: Group 1 (n=35), which was composed by those who received human lyophilized bone graft and Group 2 (n=31) composed by those who received the bovine graft.

Group 1 had 11 (31%) male patients, and 24 (69%) female patients. Age median (SD) was 63 (14) years (range: 28 - 80) and the mean follow-up time was 57 months (12-76). Group 2 had 12 (39%) male patients and 19 (61%) female patients. Age median (SD) was 59 (10) years (ranging from 41 to 80) and the mean follow-up time was 61 months (15 - 58).

Right hip was affected in 17 (49%) patients, while left hip in 18 (51%) for Group 1 subjects; for Group 2, the right hip was affected in 21 (68%) patients, while the left hip in 10 (32%).

The patients received an Informed Consent Term standardized by GCQ-HCPA and approved by the Committee of Ethics in Research of the institution.

All authors state no potential conflict of interests concerning this article.

Orthopaedics and Traumatology Service, Hospital das Clínicas de Porto Alegre, Federal University of Rio Grande do Sul Medical School  
Correspondences to: Rua Ramiro Barcellos, 2350 - Largo Eduardo Zaccaro Faraco - Porto Alegre, RS, Brasil. CEP 90035-903. E-mail: [cgalia@hcpa.ufrgs.br](mailto:cgalia@hcpa.ufrgs.br)

Received in: 12/12/07; approved in: 10/03/08

All human or bovine bone grafts have been processed, following a processing protocol developed by the authors, able to produce bone grafts with the characteristics shown on Table 1.

**Table 1 – Physicochemical analysis of lyophilized bones**

Determinations	Human (%)	CI 95%	Bovine (%)	CI 95%
Water	7.93	-	7.75	-
Fat	0.06	0.1	0.1	0.1
Nitrogen	4.3	0.1	4.3	0.1
Protein content	27.5	0.2	27.2	0.2
Phosphorus	11.9	0.1	11.9	0.2
Total P <sub>2</sub> O <sub>5</sub>	27.1	0.2	27.2	0.7
Calcium	24.6	0.7	23.7	0.6
Ca / P	2.06	-	1.99	-
Total sodium	0.57	0.01	0.46	0.01
Ashes	64.8	0.6	64.3	0.1
Chloride	1.3	0.06	1.3	0.2

\* CI = Confidence Interval \*\* Average of three assays

Human and bovine grafts were submitted to deep freezing (-80°C), after they had been washed with deionized water, chemically surfacted, centrifuged for mechanical removal of fat and marrow cells, washed in an ultra-sonic washer and then placed into the lyophilizer. Once this process was completed, they were sterilized at the autoclave.

The amount of graft employed varied, according to the bone gap to be filled, from 15 to 70 g.

All patients were operated by the same surgeon and by the same surgical team. The access port employed for all cases was the posterolateral, which is routinely used by GCQ-HCPA.

The study separately considered the reviews of acetabular component or femoral component in all treated cases. Therefore, in a patient in whom two components were replaced, these were assessed and considered separately. Thus, on Group 1 (n=35) 47 components were reviewed, 17 exclusively acetabular, 12 acetabular and femoral together, and 6 exclusively femoral; on Group 2 (n=31), 39 components were reviewed, that is, 16 exclusively acetabular, 8 acetabular and femoral concomitantly, and 7 exclusively femoral.

On Group 1, 22 cemented acetabular components, of which 12 received acetabular supplementation MDT® (São Paulo-Brazil), one received a reconstruction meshwork (Baumer® – São Paulo - Brazil) and nine did not receive metal devices; seven were non-cemented, being six expansive (Biomecânica®, São Paulo - Brazil) and one Bi-Contact/Aesculap® (Tuttlingen-Germany). On the femoral component, 17 cases received non-cemented squared wedge-like titanium Biomecânica® prosthesis; one cemented square collarless wedge-like polished Alfa/Baumer® (São Paulo-Brazil). Of these, three used meshwork or lyophilized cortical bone rules for reconstruction.

On Group 2, 19 cemented acetabular components were used, of which 14 received acetabular supplementation, one received reconstruction meshwork Alfa/Baumer® (São Paulo-Brazil) and four received no metal devices; five received non-cemented expansive Biomecânica®. On femoral component, seven cases received non-cemented titanium square wedge-like prostheses Biomecânica® brand; two Bi-Contact®, and six Alfa/Baumer®. Of these, five used meshwork or lyophilized cortical bone rules for reconstruction.

Concerning the classification of bone gaps, the criteria described by D'Antonio et al.<sup>3</sup> were followed for acetabular gaps, while the Endo-Klinik<sup>4</sup> criteria were used for femoral gaps. The distribution of acetabular and femoral gaps between groups is shown on Tables 2 and 3.

**Table 2 – Distribution of acetabular gaps**

D'Antonio	Group 1 - N (%)	Group 2 - N (%)	Total - N (%)
Type I	Nil	Nil	Nil
Type II	12 (41)	7 (29)	19 (36)
Type III	12 (41)	10 (42)	22 (41)
Type IV	5 (18)	7 (29)	12 (23)
Type V	Nil	Nil	Nil
Total	29 (100)	24 (100)	53 (100)

**Table 3 – Distribution of femoral gaps**

Endo-Klinik	Group 1 - N (%)	Group 2 - N (%)	Total - N (%)
Type I	Nil	Nil	Nil
Type II	5 (28)	6 (40)	11 (33)
Type III	9 (50)	6 (40)	15 (45)
Type IV	4 (22)	3 (20)	7 (22)
Total	18(100)	15(100)	33 (100)

Patients' assessment was based on clinical and X-ray imaging evaluations.

Clinical analysis was based on the criteria established by Merle, d'Aubigné and Postel.<sup>5</sup>

Under X-ray perspective, we used several criteria established by literature that subjectively quantify the graft over the host bone, such as: radioluminescence, density, bone trabeculate formation and components' migration.<sup>6</sup> In this study we added another criterion, which we call flocculation. Then, a checking X-ray score was designed to enable a numeric comparison of graft integration between both groups. Each of the criteria, except migration, received an individual score from 0 to 2 in each of the three De Lee e Chanley's<sup>7</sup> zones for acetabulum and of the seven Gruen et al.'s<sup>8</sup> zones for the femur, with 0 being a poor result and 2 a good result. Once the scoring of each gap was provided, the scores for each component, acetabular and femoral, were summed up. For migration, 0 was established for above 6 mm, 1 for 3-5 mm, and 2 for less than 3 mm. From an acetabular point of view, the total sum could reach 26 points, 58 for femur. We regarded as satisfactory results those between very good, good and moderate. The scores classification is shown on Table 4.

**Table 4 – Distribution of acetabular and femoral scores.**

Classification	Acetabulum	Femur
Very good	24 – 26	54 – 58
Good	21 – 23	49 – 53
Moderate	18 – 20	44 – 48
Fair	15 – 17	39 – 43
Poor	> 15	>39

## STATISTICAL ANALYSIS

The statistical analysis was performed with the aid of the statistical software SPSS (SPSS Inc, Chicago, IL)

On the descriptive analysis, the following were used for quantitative variables: arithmetic average, standard deviation (SD), maximum and minimum values, and median; for qualitative (categorical) variables, percentages, whenever applicable.

For quantitative variables, the Student's t-test was used, and, in asymmetry situations, the Mann-Whitney's U test and the Wilcoxon's test were employed. For categorical variables, the Pearson's chi-squared test was used to compare clinical and X-ray characteristics between groups with human and bovine grafts in order to test the impact caused by these grafts on prognosis.

For assessing the potential simultaneous effect of the several factors studied on clinical outcome, Cox's logistic bivariate regression was employed.

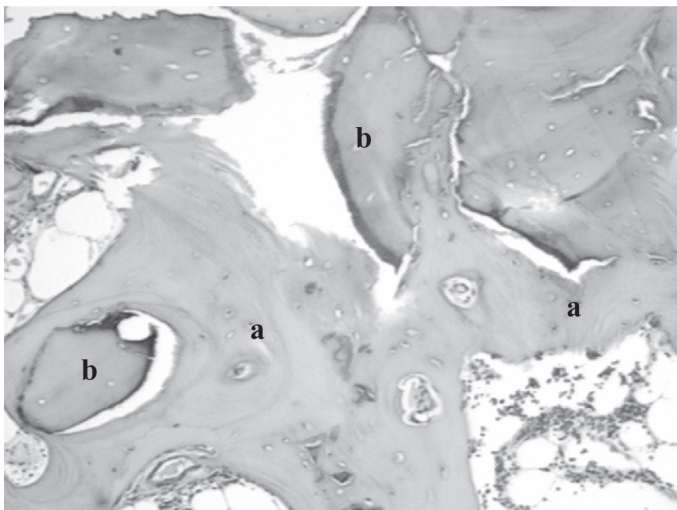
A P value < 0.05 was regarded as statistically significant. In the Cox's model, the significance level adopted was  $\leq 0.10$  with a confidence interval of 90%.

## RESULTS

Both groups showed homogeneity concerning the distribution of gender, age, follow-up time, co-morbidities, as well as for acetabular and femoral gaps.

The mean hospitalization time was 11 (8 - 20) and 10 days (7 - 20) for Groups 1 and 2, respectively. No serious complication occurred during the early postoperative period. Only two deaths (one from each group), 2 and 3 years after the procedure were reported in this series, both resulting from causes unrelated to HTAR.

On Group 1, only one case of superficial infection (cellulitis) occurred 6 months after the procedure, which evolved well with traditional antibiotics therapy. There was one case of traumatic dislocation three years after surgery, which required surgical review after bloodless reduction attempts. This enables the performance of a biopsy, which showed graft integration signs, characterized by the presence of necrotic bone trabeculae involved by neoformed bone tissue, hematopoietic marrow and adipose cells. (Figure 1)



**Figure 1** – Histological section of human lyophilized bone graft with three years of evolution showing: a) bone neoformation involving b) necrotic trabeculae.

On Group 2, a dislocation occurred in the early postoperative period in one case, which required reoperation, evolving with hematoma formation and deep infection. This patient was submitted, then, to prosthesis removal and surgical debridement.

Overall, no minor clinical interurrences without systemic involvement were reported.

The criteria employed in the X-ray, radioluminescence, density, trabeculate, flocculation and migration assessment, and analyzed separately in each group showed that: on Group 1, for the acetabular component, the lowest score was given to trabeculate: 1.77 (SD=0.49) while flocculation received the highest: 1.98 (SD=0.06). For Group 2, the lowest score was given to trabeculate: 1.65 (SD=0.45) and the highest to radioluminescence: 1.86 (SD=0.21). If we compare each feature above separately, there was no statistically significant difference between both groups, except for flocculation, where Group 1 had a significantly higher mean score (1.98) that Group 2 (1.81) ( $p=0.004$ ). The results are shown on Table 5.

**Table 5** – Acetabular X-ray scores

X-ray parameters	Group 1	Group 2	Mean
Radioluminescence	1.82 (0.3)*	1.86 (0.2)	1.84 (0.3)
Density	1.87 (0.3)	1.84 (0.3)	1.86 (0.3)
Trabeculae	1.77 (0.5)	1.65 (0.4)	1.71 (0.5)
Flocculation**	1.98 (0.0)	1.81 (0.3)	1.91 (0.2)
Migration	2.0 (0.0)	1.79 (0.0)	1.90 (0.0)

\* SD: Standard Deviation; \*\* S: Significant.

For the femoral component, the lower score on Group 1 was given to trabeculate: 1.77 (SD=0.54), and for Group 2, migration: 1.50 (SD=0.73); the highest score in both groups was given to flocculation: 2.0 (SD=0), where no case was seen. The differences between groups were also insignificant. The results are shown on Table 6.

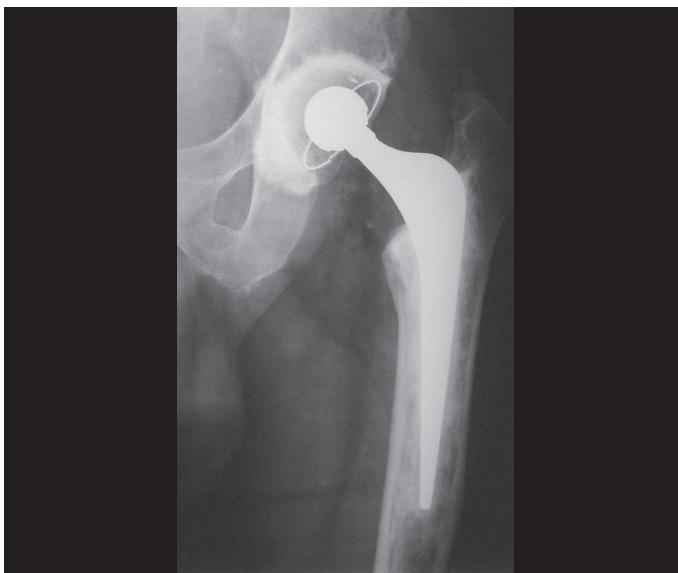**Table 6** – Femoral X-ray scores

X-ray Parameters	Group 1	Group 2	Mean
Radioluminescence	1.97 (0.0)	1.85 (0.3)	1.92 (0.2)
Density	1.82 (0.4)	1.72 (0.5)	1.77 (0.4)
Trabeculae	1.77 (0.5)	1.73 (0.4)	1.75 (0.5)
Flocculation**	2.0 (0.0)	2.0 (0.0)	2.0 (0.0)
Migration	1.72 (0.7)	1.50 (0.7)	1.61 (0.7)

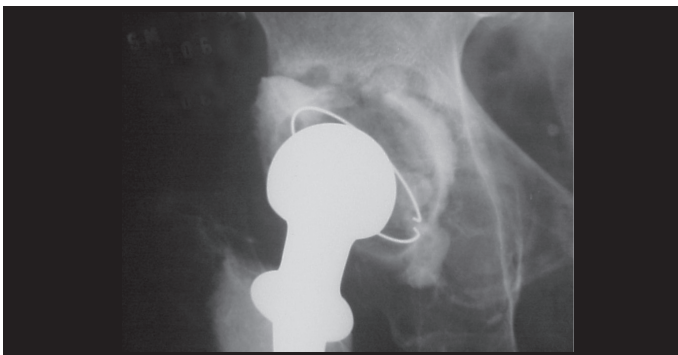
\* SD: Standard Deviation; \*\* S: Significant.

When considering the established EROI by the sum of above mentioned characteristics, the acetabular portion on Group 1 had a mean score of 24 points, while Group 2 scored 23 points (NS) out of 26. None of the groups had cases with scores below 15 points. For femoral assessment, the average was 55 for Group 1 and 53 for Group 2, out of 56 points (NS). Group 1 had only one patient with score below 43 and Group 2 had 3 patients below 43 points (NS).

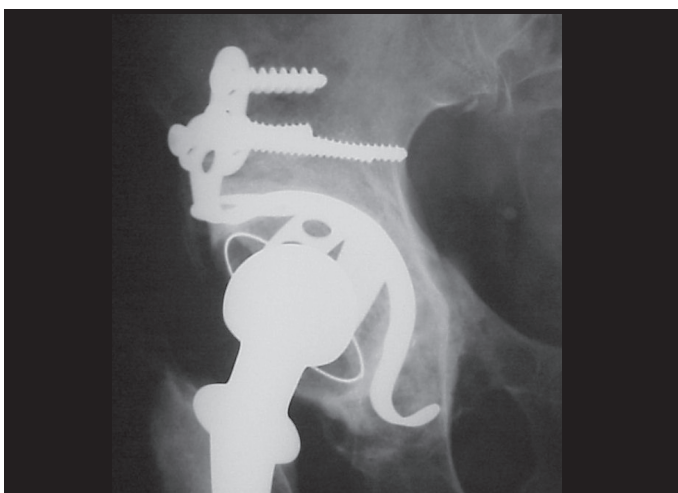
Satisfactory results were regarded as those between very good, good and moderate. According to the evaluation, thus, the results of bone union on the acetabulum were satisfactory in 95% of the cases in both Groups (NS). (Figure 2) Under a femoral point of view, the results were satisfactory for Groups 1 and 2 in 88% and 89% of the cases, respectively (NS). (Figures 3A and 3B). The results for acetabular and femoral scores in each group are shown on Tables 7 and 8, respectively.



**Figure 2** – Postoperative status of femoral nail review with 68 months of evolution.



**Figure 3A** – Preoperative status of acetabular loosening.



**Figure 3B** – 54 months postoperatively.

**Table 7** – Distribution of acetabular scores and classification between groups

Score (points)	Group 1		Group 2	
	N	%	N	%
<15	0	0	0	0
15-17	1	3.4	1	4.2
18-20	4	13.8	6	25.0
21-23	1	3.4	2	8.3
24-26	23	79.3	15	62.5

**Table 8** – Distribution of femoral scores and classification between groups

Score (Points)	Group 1		Group 2	
	N	%	N	%
<43	1	5.5	2	13.3
43-46	1	5.5	0	0
47-50	2	11.0	1	6.6
51-54	0	0	2	13.3
55-58	14	77.7	10	66.6

## DISCUSSION

For hip surgery, the most appropriate graft is believed to be the one that is minimally changed by processing. In physicochemical analyses, lyophilized bones produced according to the protocol developed by the authors maintained similar mineral and protein characteristics to frozen bones, and show a strong similarity between bovine and human bones.

Maintaining physicochemical and mechanical characteristics enables a lyophilized bone, after hydration, to be satisfactorily handled from a technical and mechanical perspective, although lacking the same texture and softness of a frozen bone.<sup>9</sup>

Both studied groups were homogenous in terms of gender, age, follow-up time, bone gaps, co-morbidities, hospitalization time and intraoperative complications.

From a clinical point of view, using the Merle d'Aubigné and Postel's scale, the medical outcomes achieved on groups 1 and 2 were regarded as good and very good in 86% and 80% of the cases, respectively. Although the follow-up time is still short for a more consistent clinical evaluation, this suggests that the use of bovine and human lyophilized grafts, during the period of this study, has shown no damages to patients or significant differences between both. It is important to mention that when we compare our results with those reported by literature using similar or different surgical techniques with similar follow-up time, but with frozen allografts, no significant differences were found as well that could be attributed to the use of lyophilized grafts, either withdrawn from bovine or human sources. Furthermore, we must consider a learning curve with the use of impacted grafts, either lyophilized or frozen.<sup>6</sup> Several studies provide a clinical and X-ray assessment of the use of lyophilized human and bovine grafts in a variety of bone diseases, showing good results. However, in HTAR surgeries, we found few indexed articles reporting the use of human lyophilized grafts, and even fewer papers addressing bovine bone grafting.<sup>10,11</sup> Such resistance showed by hip surgeons to use lyophilized grafts may be partially associated to the diversity of grafts commercially available, with distinct purposes and indications. As a result, dif-

ferent mechanical and biological responses are seen, may times causing a certain fear, due to unawareness, at the moment of choosing and using this kind of graft.<sup>9</sup>

The deficiency on the criteria for interpreting the integration of grafts by means of imaging tests is another challenging factor for analysis. For this reason, a standardized X-ray score was established – the EROI – in an attempt to better correlate this kind of evaluation with bone grafts integration both on the femur and the acetabulum. Although EROI had appropriately correlated with the bone integration pattern, which clearly provided a reduced interpretation subjectivity of the X-ray findings, that score deserves a redefinition of the parameters and re-evaluation of the weight applied to each X-ray criterion, because a criterion such as flocculation, for example, has shown to be more reliable in determining non-integration. The most significant migrations should also be reassessed.

Except for the checking femoral criteria described by Gie et al.<sup>6</sup>, X-ray evaluations reported by literature are quite distinct and subjective, in addition of being dependent on the examiner. Many times, the presence of radioluminescence, density and bone trabeculate cannot be visualized due to the use of metal materials, such as meshwork, plates, acetabular supplements, as well as cement. Some cases using reconstruction meshwork on a large portion of the acetabulum or femur, render a more accurate X-ray analysis unfeasible. Flocculation, in turn, seems to be an accurate criterion for determining the non-integration of a graft to the host bone. Provided there are serial and standardized X-ray images, migration could be a good criterion for mechanical failure of the surgical assembly, but this is not always reliable at least for a portion of graft integration.<sup>12</sup> Taking X-ray criteria into account, although limited, the results achieved with human and bovine lyophilized bone grafts in this series were comparable to each other and to those reported by literature with the use of frozen bone allograft, achieving a good X-ray performance. Under a femoral point of view, Lind et al.<sup>13</sup>, using the technique of impacted frozen graft and cement, reported, in a similar follow-up time, 88% of graft incorporation, thus similar to that found by the authors of this study.

## REFERÊNCIAS

1. Macedo CAS, Galia CR, Valin MR, Rosito R, Timm H, Muller LM. Uso de reforço acetabular em artroplastia total de quadril. *Rev Bras Ortop.* 1998;33:307-14.
2. Finkemeir CG. Bone-grafting and bone-graft substitutes. *J Bone Joint Surg Am.* 2002; 84:454-64.
3. D'Antonio JA, Capello WN, Borden LS, Bargar WL, Bierbaum BF, Boettcher WG et al. Classification and management of acetabular abnormalities in total hip arthroplasty. *Clin Orthop Relat Res.* 1989;(243):126-37.
4. Engelbrecht E, Heinert K. Klassifikation und behandlungsrichtungen von knochen-substanzverlusten bei reversionoperationen am huftgelenk. In: *Endo-Klinik, Hanburg. Mittelfristige ergebnisse: primare und revionsarthroplastik* Hrsg. Berlin: Springer-Verlag; 1987. p.89-201.
5. Merle AR, Postel M. Functional results of hip arthroplasty with acrylic prosthesis. *J Bone Joint Surg Am.* 1954;36:451-61.
6. Gie GA, Linder L, Ling RS, Simon JP, Slooff TJ, Timperley. Impacted cancellous allografts and cement for revision total hip arthroplasty. *J Bone Joint Surg Br.* 1993;75:14-21.
7. De Lee JG, Charnley J. Radiological demarcation of cemented sockets in total hip replacement. *Clin Orthop Relat Res.* 1976;(121):20-32.
8. Gruen TA, McNeice GM, Amstutz HC. "Modes of failure" of cemented stem-type femoral components: a radiographic analysis of loosening. *Clin Orthop Relat Res.* 1979;(141):17-27.
9. Cornu O, Bavadekar A, Godts B, Van Tomme J, Delloye C, Banse X. Impaction bone grafting with freeze-dried irradiated bone. Part I. Femoral implant stability: cadaver experiments in a hip simulator. *Acta Orthop Scand.* 2003;74:547-52.
10. Thien TM, Welten ML, Verdonchos N, Buma P, Yong P, Schreurs W. Acetabular revision with impacted freeze-dried cancellous bone chips and a

The use of lyophilized bone grafts provide a reduced risk of infectious transmissible and tumoral diseases, because, in its processing, in addition to the discellularization performed, chemical reagents are used that are able to inactivate bacteria, viruses, and, possibly, prions due to sodium hypochlorite exposure.<sup>14,15</sup> After all this process, they are still submitted to autoclave for sterilization<sup>16</sup>, which, in our library, reaches virtually 100% of efficacy. And this importance is also confirmed when we observe the uncountable annual notifications to the Centers of Disease Control and Prevention (CDC) for bacterial infections secondary to the use of frozen bone allografts, despite of the strict biosafety rules of the American Association of Tissue Bank.<sup>17</sup> Therefore, concerns associated to the transmission of prions responsible for Bovine Spongiform Encephalopathy (BSE) attributed to the use of bovine lyophilized bone graft seem to be not justified, especially when care with breed selection is taken into account, as well as the source country, which is particularly the case of Brazil, with a *neglectful risk* to BSE. Furthermore, risk analysis performed provide a quite accurate view about this topic.<sup>18</sup>

Literature is full of articles addressing the use of frozen bone grafts, adopting these as almost a standard and parameter for bone grafting in THARs.<sup>19,20</sup> However, the lack of prospective, randomized studies comparing the various kinds of grafts represent a gap and, at least, questions current paradigms that seem to lack scientific validation.

## CONCLUSION

This study allow us to conclude that the process of lyophilizing bovine or human bones, according to the protocol developed by the authors, did not cause any damages to patients, so being regarded as with appropriate quality for use in THARs.

Furthermore, the use of bovine lyophilized bone graft showed similar clinical and X-ray results to human lyophilized bone graft, thus consisting in an alternative to human-sourced grafts.

- cemented cup: a report of 7 cases at 5 to 9 years' follow-up. *J Arthroplasty.* 2001;16:666-70.
11. de Roock NJ, Drabu KJ. Impaction bone grafting using freeze-dried allograft in revision hip arthroplasty. *J Arthroplasty.* 2001;16:201-6.
12. Barden B, Fitzek JG, Huttegger C, Loer F. Supportive strut grafts for diaphyseal bone defects in revision hip arthroplasty. *Clin Orthop Relat Res.* 2001;(387):148-55.
13. Lind M, Krarup N, Mikkelsen S, Horlyck E. Exchange impaction allografting for femoral revision hip arthroplasty: results in 87 cases after 3.6 years' follow-up. *J Arthroplasty.* 2002;17:158-64.
14. Taylor D. Inactivation of the BSE agent. *C R Biol.* 2002;325:75-6.
15. Aranda-Anzaldo A, Viza D, Busnel RG. Chemical inactivation of human immunodeficiency virus in vitro. *J Virol Methods.* 1992;37:7182.
16. Viceconti M, Toni A, Brizio L, Rubbini L, Borrelli A. The effect of autoclaving on the mechanical properties of bank bovine bone. *Chir Organi Mov.* 1996;81:63-8.
17. Invasive *Streptococcus pyogenes* after allograft implantation – Colorado, 2003. [acessado em 2004 Jan 23]; [1 tela] Disponível em: <http://www.cdc.gov/mmwr/preview/mmwrhtml/mm5248a1.htm>
18. Wenz B, Oesch B, Horst M. Analysis of the risk of transmitting bovine spongiform encephalopathy through bone grafts derived from bovine bone. *Biomaterials.* 2001;22:1599-606.
19. Ullmark G, Obrant KJ. Histology of impacted bone-graft incorporation. *J Arthroplasty.* 2002;17:150-7.
20. Slooff TJ, Buma P, Schreurs BW, Schimmel JW, Huiskes R, Gardeniers J. Acetabular and femoral reconstruction with impacted graft and cement. *Clin Orthop Relat Res.* 1996;324:108-15.