

# SPONTANEOUS FRACTURE OF THE FEMORAL NECK FOLLOWING PFN REMOVAL

ARNALDO JOSÉ HERNANDEZ<sup>1</sup>, EDIMAR FÁVARO<sup>2</sup>, MARCOS HENRIQUE FERREIRA LARAYA<sup>3</sup>, ARNALDO VALDIR ZUMIOTTI<sup>1</sup>

## ABSTRACT

Femoral neck fracture without associated trauma following consolidation of a transtrochanteric fracture is a rare event. The authors report a case of transtrochanteric fracture that was treated with PFN and which

presented fracturing of the femoral neck two weeks after removal of the device. This occurrence was treated with partial arthroplasty.

**Keywords:** Femoral fractures/complications. Fracture fixation. intramedullary. Femoral neck fractures.

**Citation:** Hernandez AJ, Fávaro E, Laraya MHF, Zumiotti AV. Spontaneous fracture of the femoral neck following PFN removal. *Acta Ortop Bras.* [online]. 2009; 17(3):187-9. Available from URL: <http://www.scielo.br/aoob>

## INTRODUCTION

The major legacy of the 20th Century for human race was longevity. Even in developing countries, an overwhelming increase of life expectancy was seen.<sup>1</sup> Paradoxically, one of the greatest challenges of the new century is to minimize the socioeconomical impact of population's aging process associated to an improvement of quality of life.

With population's aging process in the last decades, there was a strong increase of the number of fractures affecting the proximal femur.<sup>2</sup> In Brazil, 90% of SUS resources allocated to orthopaedic illnesses are consumed by nine conditions, including transtrochanteric fractures.<sup>3</sup>

Among the therapeutic arsenal for treating this fracture, the Proximal Femoral Nail (PFN®), is gaining attention, since its introduction in clinical practice by the pioneering studies by Schwab et al.<sup>4</sup> and Simmermacher et al.<sup>5</sup> Subsequently, other authors confirmed the effectiveness of this implant in providing stabilization in proximal femoral fractures with minimal bleeding, and in allowing early load release.<sup>6,7</sup>

Despite of its wide acceptance in clinical practice, this is not a complication-free method. Below, we describe a case of spontaneous femoral neck fracture following the removal of this implant in a united transtrochanteric fracture and the therapy provided.

## CASE REPORT

An 82 year-old female patient suffered a fall, resulting in pain and functional disability of the right hip. At the time, transtrochanteric fracture of the right hip was diagnosed and reduction with PFN® fixation was conducted in 12-4-2001. (Figure 1)

Eighteen months after osteosynthesis, with the transtrochanteric fracture showing union (Figures 2 and 3) and no X-ray changes, the patient reported unspecific pain on the lateral surface of the

hip, which was making her walk difficultly. At that time, we interpreted that the implant should have been placed slightly high, somehow causing an impact, and a subtle lateral migration of the screws of the femoral head was perceived. Based on this precept, we decided to remove the implant, and the patient was asked to apply partial load (30% of the body weight), with walker. (Figure 4)

After two weeks, the patient sought us in our practice complaining of a strong worsening of the pain picture and trouble to walk. X-ray images of the hip were taken, where a femoral neck fracture was found, which was classified as Garden's grade 3. (Figure 5) Upon diagnosis, the patient and her family were made aware of the occurrence, and the patient was hospitalized for surgical treatment. Because of her advanced age and of the degree of deviation of the femoral neck fracture, we decided to conduct a partial hip arthroplasty.

## DISCUSSION

One of the most common complications of PFN® is the lateral migration of the femoral head screws, known as effect Z or zeta. This complication is well documented by literature.<sup>8,9</sup> Another complication reported by Rappold et al.<sup>10</sup> was the breakage of three implants in a series of subtrochanteric fractures.

Despite of the diversity of complications described in literature, we didn't find any case of femoral neck fracture after PFN® removal with the primary fracture showing union, although this complication is described in association with other syntheses.<sup>11,12</sup>

The occurrence of femoral neck fractures after transtrochanteric fracture union is a rare event.<sup>11-16</sup> Most of the times, when this occurs, these fractures are associated to a new trauma episode<sup>12,13,15-17</sup>, its occurrence being uncommon after implants removal.<sup>11,15</sup>

The real cause of this complication is still unclear, but literature suggests that its etiology may be correlated to an incorrect inser-

All the authors state no potential conflict of interest concerning this article.

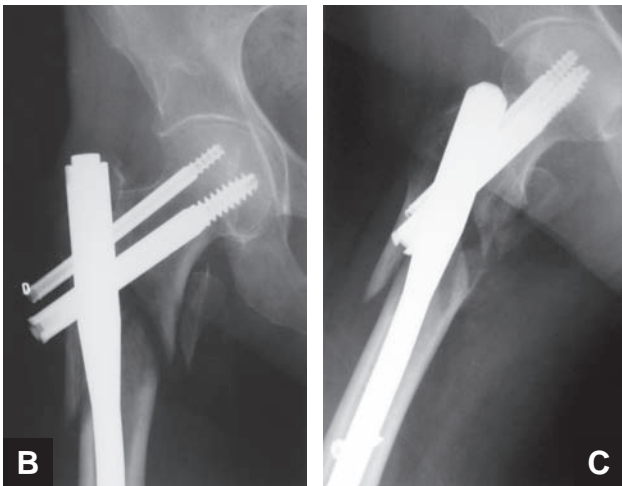
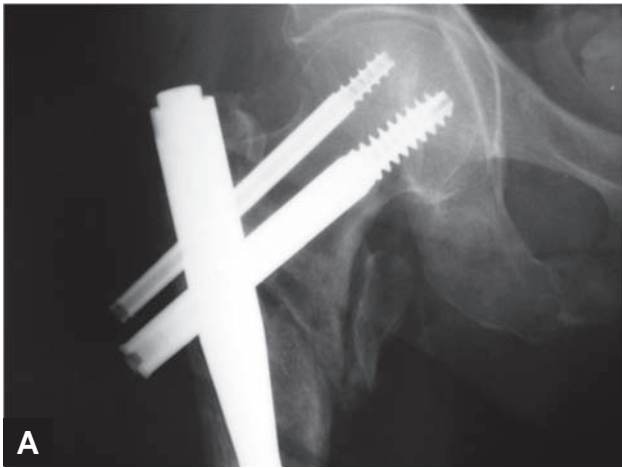
1. LIM.41 – Musculoskeletal System Laboratory of the Department of Orthopaedics and Traumatology, Medical School, University of São Paulo, SP, Brazil

2. Medical Sciences School, Santa Casa de São Paulo, SP, Brazil.

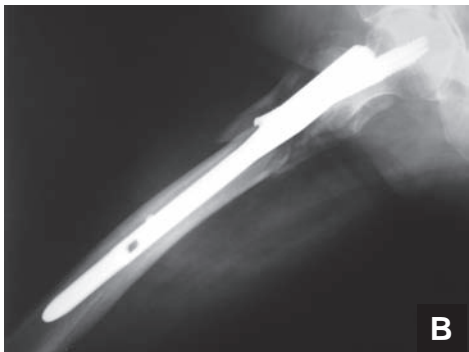
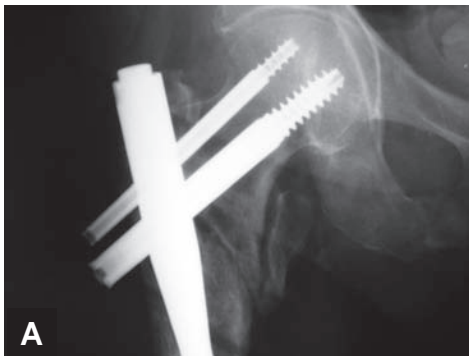
3. Medical School of Marília, SP, Brazil.

Correspondences to: Arnaldo José Hernandez, MD, Rua Barata Ribeiro 414, Cj. 53, São Paulo-SP, BRASIL, CEP 01308-000, E-mail: [ajhernandez@uol.com.br](mailto:ajhernandez@uol.com.br)

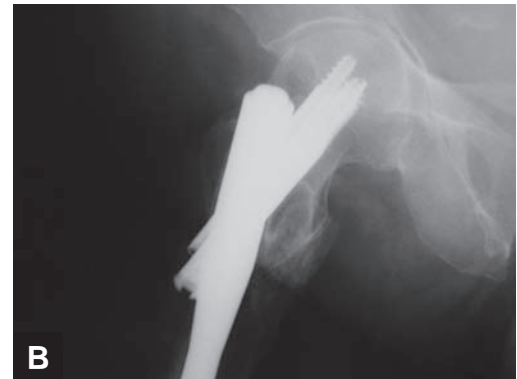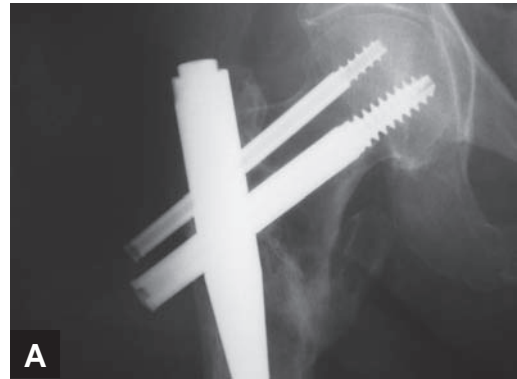
Received in: 10/19/07; approved in: 06/23/08



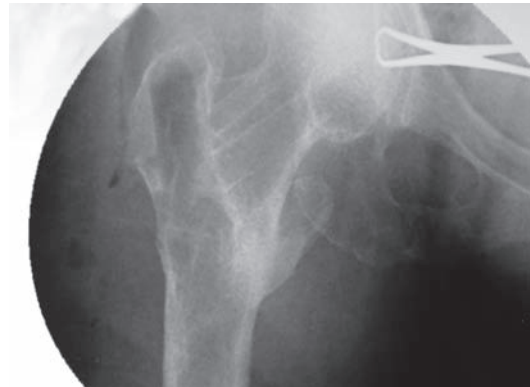
**Figure 1** – X-ray images at frontal plane (A and B) and lateral plane (C) of right hip at the early postoperative period for transtrochanteric fracture fixation with PFN®.



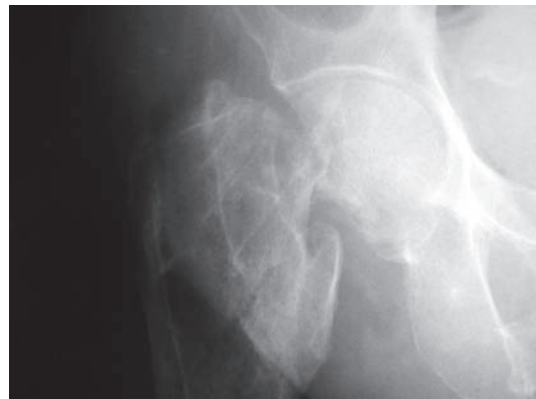
**Figure 2** – X-ray images at frontal plane (A) and lateral plane (B) of the hip showing transtrochanteric fracture in union process.



**Figure 3** – X-ray images at frontal plane (A) and lateral plane (B) of the hip 1.5 year postoperatively. Note fracture union.



**Figure 4** – Intraoperative X-ray image when removing the synthesis. Note the fracture on the transtrochanteric region united and no X-ray changes on the femoral neck.



**Figure 5** – X-ray image of the right hip two weeks after synthesis removal evidencing femoral neck fracture.

tion of implants or to avascular necrosis.<sup>12-14,18</sup> However, Buciuto et al.<sup>11</sup> described seven spontaneous fractures of the femoral neck, within in average 19 days after the removal of the implant (DHS® and/ or angled plate), with a histological examination of the femoral head being carried out in three cases, with inconclusive results. The patients were treated with arthroplasty. Additionally to these potential mechanisms, literature also suggests that after an implant's removal, osteoporosis can also contribute to the weakening the subcapital region of the femoral neck, making it more likely to concentrate stress.<sup>15,19</sup> Buciuto<sup>11</sup> also suggests that

the pain reported by the patient previously to implant removal, with an united transtrochanteric fracture might have been misunderstood, which, in fact, could be clinical signs of subcapital stress fracture.

The purpose of this paper is to make physicians aware of this rare complication, and, with this information in hands, they must soon inform their patients.

In our opinion, due to risks inherent to this practice, the removal of intramedullary implants of the proximal femur should be carefully performed.

## REFERENCES

1. Ramos LR, Veras RP, Kalache A. Population aging: a Brazilian reality. *Rev Saú-de Pública.* 1987;21:211-24.
2. Cummings SR, Rubin SM, Black D. The future of hip fractures in the United States. Numbers, costs, and potencial effects of postmenopausal estrogen. *Clin Orthop Relat Res.* 1990;(252):163-6.
3. Koberle G. Fraturas transtrochanterianas. *Rev Bras Ortop.* 2001;36:325-9.
4. Schwab E, Höntzsch D, Weise K. Treatment of unstable inter-and subtrochanteric fractures with the proximal femoral nail (PFN). *Akt Traumatol.* 1998;28:56-60.
5. Simmermacher RK, Bosch AM, Van der Werken C. The AO/ASIF-proximal femoral nail (PFN): a new device for the treatment of unstable proximal femoral fractures. *Injury.* 1999;30:327-32.
6. Nuber S, Schonweiss T, Ruter A. Stabilisation of unstable trochanteric femoral fractures. Dynamic hip screw (DHS) with trochanteric stabilisation plate vs. proximal femur nail (PFN). *Unfallchirurg.* 2003;106:39-47.
7. Saudan M, Lubbeke A, Sadowski C, Riand N, Stern R, Hoffmeyer P. Peritrochanteric fractures: is there an advantage to an intramedullary nail? A randomized, prospective study of 206 patients comparing the dynamic hip screw and proximal femoral nail. *J Orthop Trauma.* 2002;16:386-93.
8. Boldin C, Seibert FJ, Fankhauser F, Peicha G, Grechening W, Szyszkowitz R. The proximal femoral nail (PFN) a minimal invasive treatment of unstable proximal femoral fractures: a prospective study of 55 patients a follow-up of 15 months. *Acta Orthop Scand.* 2003;74:53-8.
9. Windolf J, Hollander DA, Hakimi M, Linhart W. Pitfalls and complications in the use of the proximal femoral nail. *Langenbecks Arch Surg.* 2005;390:59-65.
10. Rappold G, Hertz H, Spitaler R. Implant Breakage of the proximal femoral nail (PFN). *Eur J Trauma.* 2001;27:333-7.
11. Buciuto R, Hammer R, Herder A. Spontaneous subcapital femoral neck fracture after healed trochanteric fracture. *Clin Orthop Relat Res.* 1997;(342):156-63.
12. Baker DM. Fractures of the femoral neck after healed intertrochanteric fractures: a complication in of too short a nail plate fixation. Report of the three cases. *J Trauma.* 1975;15:73-81.
13. Parker MJ, Walsh ME. Importance of sliding screw position in trochanteric fracture. 4 cases of secondary cervical fracture. *Acta Orthop Scand.* 1993;64:73-4.
14. Ross PM, Kurtz N. Subcapital fracture subsequent to Zuckel nail fixation. A case report. *Clin Orthop Relat Res.* 1980;(147):131-3.
15. Taylor PRP, Hepple S, Stanley D. Combination subcapital and intertrochanteric fractures of the femoral neck. *Injury.* 1996;27:68-71.
16. Wolf AM, Kessler HW. [Letter to the editor]. *Clin Orthop Relat Res.* 1990;(256):308.
17. Gogan W, Daum WJ, Simmons DJ, Evans EB. Subcapital fracture of the hip following an intertrochanteric fracture. A case report and literature review. *Clin Orthop Relat Res.* 1988;(232):205-9.
18. Mariani EM, Rand JA. Subcapital fractures after open reduction and internal fixation of intertrochanteric fractures of the hip. Report of three cases. *Clin Orthop Relat Res.* 1989;(245):165-8.
19. Rosson J, Murphy W, Tonge C, Shearer J. Healing of residual screw holes after plate removal. *Injury.* 1991;22:383-4.