

# SIMULTANEOUS “BUCKET-HANDLE” TEAR OF BOTH MENISCI ON THE SAME KNEE

---

ANDRE FRANCISCO GOMES, VINICIUS CHISSINI PAGANELLA, MAURÍCIO ZAPPAROLI, EMERSON KLEBER ZANONI,  
FABIANO FERRARI LUCASKI, RODRIGO AGUIAR

---

## ABSTRACT

Simultaneous “bucket-handle” tear of menisci on the same knee is a rare phenomenon. We describe a case of a bucket-handle tear of menisci and tear of anterior cruciate ligament of the same knee showed on magnetic resonance

imaging and confirmed by arthroscopy. The magnetic resonance imaging can provide accurate diagnosis of this type of injury.

**Keywords:** *Magnetic resonance imaging. Knee. Menisci tibial.*

---

**Citation:** *Gomes AF, Paganella VC, Zapparoli M, Zanoni EK, Lucaski FF, Aguiar R. Simultaneous “bucket-handle” tear of both menisci on the same knee. Acta Ortop Bras. [online]. 2009; 17(4):247-9. Available from URL: <http://www.scielo.br/aob>.*

---

## INTRODUCTION

Magnetic resonance is the imaging method of choice for assessing patients suspected of meniscal injuries, showing a high sensitivity and specificity for detecting ruptures, as well as complications and associated injuries.<sup>1</sup> Meniscal tears can be defined according to its etiology as degenerative and trauma-related, and according to its orientation as horizontal, vertical, radial, oblique or complex. Among complications are unstable meniscus injuries, such as the “bucket-handle” one, with fragment displacement, potentially causing joint blockage.<sup>2</sup>

“Bucket-handle” meniscal injury is characterized by a tear, usually vertical longitudinal or oblique, where the central portion of the meniscus forms a free fragment dislocating towards the central portion of the joint, at the intercondylar region. This fragment remains stuck to the remnant meniscus by the anterior and posterior horns, forming the “bucket handle”.<sup>2</sup> This kind of injury compromises mostly the medial meniscus, of post-traumatic etiology.

Although relatively common on one compartment, especially on the medial one, this injury on both menisci of a same knee is a rare phenomenon, with few cases described in literature.<sup>3-7</sup> Here, we present a case of simultaneous “bucket handle” tear on both menisci of a same knee, diagnosed by magnetic resonance and surgically confirmed by videoarthroscopy, with literature review.

## CASE REPORT

A 27 year-old male patient with history of left knee sprain occurred in the previous year during a volleyball game, evolving with joint effusion at acute phase. He sought medical care soon after sprain, with X-ray images of the knee being taken and showing no fracture signs. The patient received symptomatic treatment and was guided to rest. After about five weeks, he experienced no pain, but started to miss some steps when ambulating, and reported that his knee “displaced and locked” (sic). At physical examination, he showed reduced tropism at the right thigh, with no signs of joint effusion, 140° of motion, + lachmann, + anterior drawer, defenda pivot, ++ mcmurray, + appley.

The patient was submitted to magnetic resonance study (Siemens Magnetom Avanto, 1,5 T, Erlangen, Germany). The test was performed according to the following protocol: patient at supine position with knee slightly rotated outwards (about 5 degrees), using a specific surface coil; section thickness between 3.0 and 4.0 mm and interval between sections between 0.6 and 1.0 mm, depending on the employed sequence; 160 mm FOV and 512 × 512 matrixes. The following sequences were assessed: Sagittal “fast spin echo” weighted on T2 (TR: 3,500 ms and TE: 91 ms) and protons density (TR: 1,800 ms and TE: 32 ms); axial, sagittal and coronal “fast spin echo” weighted on protons density (TR: 2000 ms and TE: 25 ms), with fat suppres-

---

All the authors state no potential conflict of interest concerning this article.

---

*Clínica DAPI (DIAGNÓSTICO AVANÇADO POR IMAGEM), Curitiba, PR, Brazil.*

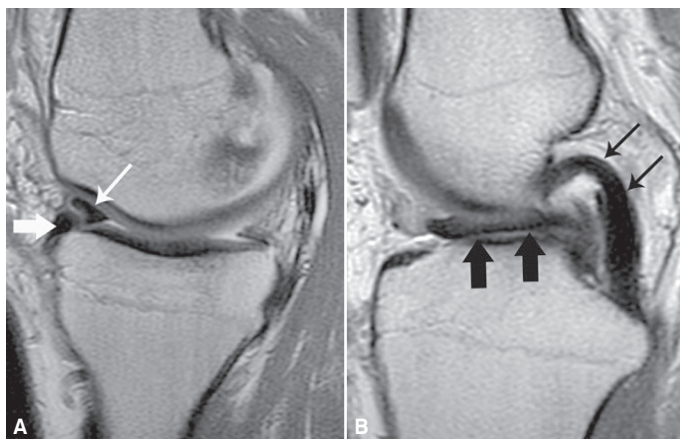
**Correspondences to:** *Al. Julia da Costa, 1525 Ap 61, Bigorriho.CEP: 80730-070 – Curitiba, PR, Brasil. Email: andregomes2006@uol.com.br*

Received in: 08/13/08; approved in: 12/02/08

sion technique; oblique coronal “fast spin echo” weighted on T2 (TR: 3000 ms and TE: 80 ms) for studying the anterior cruciate ligament.

The study showed a reduction of menisci volume, with fragments displaced to the intercondylar region, consistent with “bucket handle” tear (Figures 1 and 2) and undefined anterior cruciate ligament, characterizing a full tear. Bilateral double delta sign formation was evidenced next to anterior horn of menisci and the posterior double cruciate sign, related to the central fragment of medial meniscus. (Figure 1) On the images at coronal and oblique coronal planes, three low-signal structures have been identified at the intercondylar region, characterized by central fragments of medial and lateral menisci and of the posterior cruciate ligament. (Figure 2) The anterior cruciate ligament was not identified.

The patient was submitted to videoarthroscopy as shown by Figure 2, confirming the injuries found at magnetic resonance imaging, with bilateral subtotal meniscectomy and anterior cruciate ligament reconstruction with tendinous gracile and semitendinous transposing being performed.

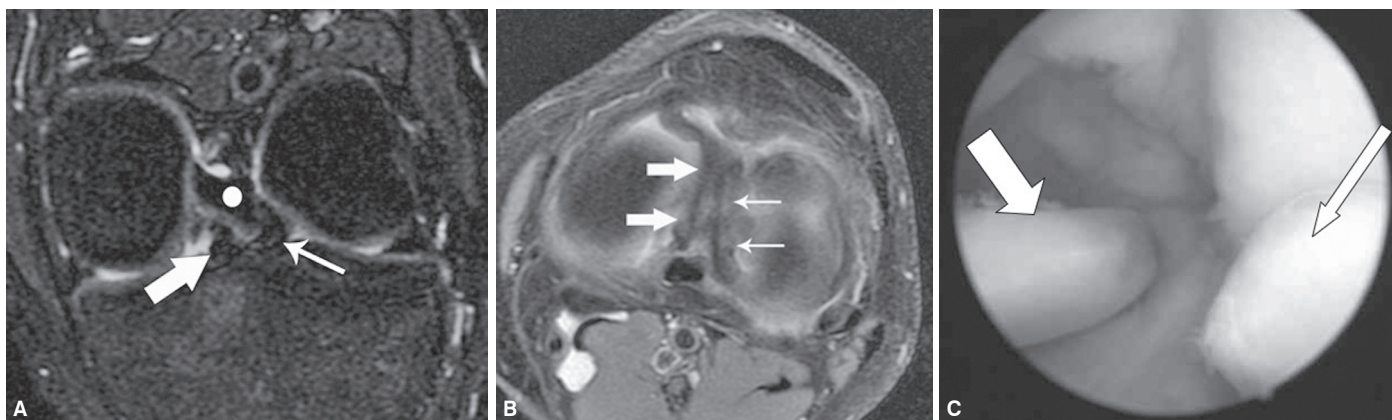


**Figure 1** – Sagittal images weighted on protons density. A: Double delta or inverted meniscus sign, represented by the anterior horn of the remaining medial meniscus (thick arrow) and anteriorly migrated and rotated fragment (thin arrow). B: Double posterior cruciate sign, represented by medial meniscus fragment migrated to the intercondylar region (thick arrows) and posterior cruciate ligament (thin arrows).

## DISCUSSION

Meniscal “bucket handle” tears are usually a result of trauma in young patients, and account for 10% of meniscal injuries, being three times more frequent on medial meniscus. They are often associated to anterior cruciate ligament rupture, as evidenced by the present case, and may occur in its acute form, upon anterior cruciate ligament tears or due to instability in chronic injuries. Joint blockage is a frequent finding at physical examination, although it may be absent in lateral meniscus injuries.<sup>3</sup> In magnetic resonance studies, the most specific findings are: 1 - double posterior cruciate ligament sign, at sagittal plane, due to the interposition of the central fragment of the medial meniscus, in parallel and below posterior cruciate ligament; 2 - flipped meniscus sign/double delta sign, at sagittal or coronal planes, due to the summation of anterior or posterior horns image and the adjacent inverted meniscal fragment, and; 3 - meniscal fragment at intercondylar notch, better identified at coronal plane.<sup>4,5</sup> In the present study, we could see double delta next to the anterior horn of both menisci, the double posterior cruciate sign, and the presence of meniscal fragments at intercondylar region.

Brammer and cols. published the first case of “bucket handle” tear on medial and lateral menisci associated to an anterior cruciate ligament rupture, and named that finding as “Jack and Jill lesion”.<sup>6</sup> As the magnetic resonance test was carried out 22 months after trauma, we could not determine if the injuries occurred at the same time. Similarly, in the present study, we could not infer if the injuries were acute or not, because resonance was performed 12 months after trauma. Bugnone and cols. reported a case of simultaneous “bucket handle” tear of medial and lateral menisci in a 22 year-old patient after a motorcycle accident, also associated to anterior cruciate ligament rupture, where the “quadruple cruciate sign” (presence of anterior cruciate ligament, posterior cruciate ligament, and fragments of medial and lateral menisci located at intercondylar notch on coronal magnetic resonance images).<sup>4</sup> In our study, we didn’t find this sign, but the “triple cruciate sign” due to the absence of the anterior cruciate ligament, which was chronically ruptured. Tecklenburg and cols. described the first case in a professional athlete (skier), with documented mechanism in



**Figure 2** – Oblique coronal (A) and axial (B) images weighted on T2 with fat saturation showing meniscal fragments migrated to the intercondylar region. Thick white arrow: medial meniscus fragment; thin white arrow: lateral meniscus fragment; white dot: posterior cruciate ligament. Please, note that the ruptured anterior cruciate ligament is not identified. At C, an arthroscopic correlation is noticed.

which the patient fell with the knee slightly rotated and at maximum flexion, at a high speed. Their findings also pointed out to anterior cruciate ligament rupture and "bucket handle" tear of medial and lateral menisci.<sup>7</sup> Our case is the second to be described associated to sport-related injury, and the first in which sports practice was for recreational purposes only, corresponding to the vast majority of patients submitted to tests in clinical practice.

## CONCLUSION

Although rare, combined "bucket handle" tears on both menisci of a same knee can occur and may be diagnosed by magnetic resonance tests using the signs described for unicompartmental meniscal injuries. The association with full anterior cruciate ligament rupture is described in all cases reported by literature, including this one, and should be sought for in suspicious cases, helping on providing a surgical/ therapeutic planning for these patients.

## REFERENCES

1. Kaplan PA, Helms CA, Dussalt R, et al. Knee, In: Lisette Bralow ,Musculoskeletal MRI. 1st ed. Philadelphia: Elsevier Saunders; 2001;372-6.
2. Resnick D, Kransdorf MJ. Internal derangements of joints, In: Resnick D, Kransdorf MJ, Bone and joint imaging. 3rd ed. Philadelphia: Elsevier Saunders; 2005. p.945-74.
3. Cetik O, Cirpar M, Eksioğlu F, Uslu M. Simultaneous bucket handle tear of both medial and lateral menisci of a knee with chronic anterior cruciate ligament deficiency. *Knee Surg Sports Traumatol Arthrosc.* 2006;14:356-9.
4. Bugnone AN, Ramnath RR, Davis SB, Sedaros R. The quadruple cruciate sign of simultaneous bicompartamental medial and lateral bucket handle meniscal tears. *Skeletal Radiol.* 2005;34:740-4.
5. Dorsay TA, Helms CA. Bucket handle meniscal tears of the knee: sensitivity and specificity of MRI signs. *Skeletal Radiol.* 2003;32:266-72.
6. Brammer H, Sover E, Erickson S, Stone J. Simultaneous identification of medial and lateral bucket handle tears: the Jack and Jill lesion. *AJR Am J Roentgenol.* 1999;173:860-1.
7. Tecklenburg K, Schoepf D, Hoser C, Fink C. Anterior cruciate ligament injury with simultaneous locked bucket handle tears of both medial and lateral meniscus in a 19 year old female professional ski racer: a case report. *Knee Surg Sports Traumatol Arthrosc.* 2007;15:1125-9.