

COMPARATIVE HISTOLOGICAL EVALUATION OF TIBIAL BONE REPAIR IN RABBITS TREATED WITH XENOGRAFTS

MÓNICA DIJANA CALASANS-MAIA¹, FÁBIO OLIVEIRA ASCOLI², ADRIANA TEREZINHA NEVES ALVES NOVELLINO³,
ALEXANDRE MALTA ROSSI⁴, JOSÉ MAURO GRANJEIRO^{1,5}

ABSTRACT

Objective: Xenografts are an alternative to autogenous grafts and must be osteoconductive and biocompatible. A recent study has demonstrated that the physical and chemical characteristics of commercially available hydroxyapatites do not fit the manufacturers' descriptions. This study evaluates the biocompatibility and osteoconduction of a xenograft derived from bovine medullary bone. **Methods:** Fifteen adult rabbits weighing between 2,500 g and 3,000 g each were anesthetized and subjected to surgical procedures to create three perforations in the tibia, with a diameter of 2 mm. These were filled with blood clot,

Osseus® and Bio-Oss®. The animals were euthanized after 7, 14 and 28 days. **Results:** Histopathological analysis of the interface between the bone and the biomaterial showed a slight inflammatory response after 7 days, which was absent in the subsequent periods. Both materials were partially replaced by bone tissue directly in contact with the surface of the materials, without the occurrence of fibrosis. **Conclusion:** We concluded that both materials are biocompatible and absorbable, allowing for progressive bone apposition on the surface throughout the evaluation period.

Keywords: Bone transplantation. Rabbits. Materials testing.

Citation: Calasans-Maia MD, Ascoli FO, Novellino ATN, Rossi AM, Granjeiro JM. Comparative histological evaluation of tibial bone repair in rabbits treated with xenografts. *Acta Ortop Bras.* [online]. 2009; 17(6):340-3. Available from URL: <http://www.scielo.br/aob>

INTRODUCTION

Repairing large bone defects continues to be a challenge for orthopedists that use traditional autologous bone grafts because of their osteogenic properties and easier incorporation than alloplastic and xenogenic grafts.¹

Transplanted materials can be classified according to their origin as autologous (autografts), homologous (allografts), heterologous (xenografts) and alloplastic (consisting of inorganic or synthetic material). Autografts are taken from the patient and act by mechanisms called osteogenesis, osteoconduction (bone regeneration) and osteoinduction.² The insertion of autografts entails risks for the patient, including additional surgical procedures, an increase in postoperative morbidity, debilitation of the donor region and an often unsatisfactory

quantity of autograft tissue available.¹ Allografts may be obtained from human cadavers or from live donors, and are processed under sterile conditions and stored in human bone banks. The advantage of using homologous materials is that only one site of surgery is needed, thus involving less surgical time and morbidity. Osteoinduction of allografts occurs through bone morphogenetic proteins (BMPs) responsible for differentiating mesenchymal stem cells into osteoblasts.³ The disadvantages of using tissue from another individual are the possibility of transmitting diseases and the limited availability of grafts.⁴ Xenografts are obtained from a species different from that of the receptor⁵ and are predominantly made from the inorganic portion of animal bone tissue, being classified as osteoconductors.^{2,3} Synthetic materials for bone regeneration,

All the authors declare that there is no potential conflict of interest referring to this article.

1 – Post-Graduation Program in Pathology and College of Dentistry, Universidade Federal Fluminense, Niterói, Rio de Janeiro, Brazil

2 – Department of Physiology and Pharmacology, Biomedical Institute, Universidade Federal Fluminense, Niterói, Rio de Janeiro, Brazil

3 – College of Dentistry, Universidade Gama Filho, Rio de Janeiro, Brazil

4 – Biomaterial Laboratory - LABIOMATAT / MCT, Brazilian Physical Research Center, RJ, Brazil

5 – Cell Therapy Center and Biology Institute, Biology Institute, Universidade Federal Fluminense, Niterói, Rio de Janeiro, Brazil

Study conducted in the Cell Therapy Center and Biology Institute, Biology Institute, Universidade Federal Fluminense, Niterói, Rio de Janeiro, Brazil Study conducted at Laboratório de Cirurgia Experimental Firmino M. Filho, Faculdade de Medicina Veterinária da Universidade Federal Fluminense (UFF), Rio de Janeiro, Brazil.
Mailing Address: Av. Rui Barbosa, 582/501 - Flamengo - Rio de Janeiro - RJ - E-mail: monicacalasans@terra.com.br

Article received on 02/10/09 and approved on 05/08/09

classified as osteoconductors,⁵ are an alternative to existing limitations and difficulties in obtaining autografts, and to the possibility of disease transmission by allografts.

Processing bovine bone can result in two distinct types of material: inorganic and organic (predominantly collagen type I). Inorganic material is free of proteins and cells because it consists only of hydroxyapatite. Proteins are removed by heat treatment at temperatures above 300°C but the higher the temperature the lower the probability of bioabsorption of these materials.⁶ Heat treatment interferes directly with the material's crystallinity level, increasing calcination (1000°C) or sinterization (1250°C).⁶⁻⁸ On the other hand, treatment of bovine bone with organic solvents, alkalis and acids under controlled concentration and temperature, permits removal of cells, cellular debris and various non-collagenic proteins as well as the mineral portion, leaving a protein structure basically made up of collagen type I and a small amount of growth factors, such as bone morphogenetic proteins.⁹ Treatment above 300°C or with alkalis followed by neutralization eliminates the risk of disease transmission.¹⁰ In fact, Brazil is still in an enviable position in this regard because its cattle is free of spongiform encephalopathy (BSE or mad cow disease).⁹ Previous studies have demonstrated the viability of xenografts in bone defects of rat femur,¹¹ with different results depending on the experimental defect used.^{12,13}

A recent study showed that of the six particulate hydroxyapatites tested from those available in the Brazilian market, only one matched the manufacturer's specifications.¹⁴ This means that the quality of the material is not predictable for use in clinical applications and that there is a need for standards, important in evaluating the manufacturing quality in the search for suitable materials.

This study compares by histologic analysis the biocompatibility, biodegradation and osteoconduction of two bovine xenografts - Osseus® and Bio-Oss®.

MATERIALS AND METHODS

Fifteen adult white New Zealand rabbits, each weighing between 2,500 g and 3,000 g, were randomly split into three groups: Osseus®, Bio-Oss® and blood clot. This project received approval from the Animal Research Ethics Committee (#0003/07). The animals received a pre-anesthetic (20mg/kg of ketamine and 1 mg/kg of xylazine IM) followed by a general anesthetic (1% isoflurane by inhalation) and 0.3 mg/kg of lidocaine plus 0.1 mg/kg of morphine for spinal anesthesia. Topical chlorhexidine was used for disinfection, the hair was shaved around the animals' tibias and a 4cm incision was made in the skin of the hind legs. After exposing the tibia surface (Figure 1A) and with continuous saline solution irrigation, three 2 mm holes were drilled 1 cm apart (Figure 1B) in each tibia. A low speed drill was used with a 2 mm round surgical bur. Two

holes in the right and left tibias were immediately filled with bovine hydroxyapatites (A-Osseus® and B-Bio-Oss®) and the third holes were filled with a blood clot. The animals were euthanized with an overdose of general anesthetic at periods of 7, 14 and 28 days after surgery. Three tissue fragments were collected and placed in 10% buffered formaldehyde for 48 hours and demineralized in a decalcification solution (All-kimia®) for 24 hours. Histological sections 5 µm thick were stained with hematoxylin and eosin (H&E) and examined by light microscopy. The reaction of the cells to the xenograft was observed, focusing on the intensity and nature of the inflammatory response, and the presence of necrosis, fibrous connective tissue and neoformed bone in direct contact with the graft.

RESULTS

The biomaterials tested were easy to handle during the surgical procedures. The control group was completely filled with new bone and no adverse inflammation was observed. Macroscopic observations showed no morphological differences between the xenografts. (Figure 2) Microscopic analysis showed very similar patterns for both biomaterials. Light inflammatory infiltrates were present at 7 days. (Figure 3) and absent at 14 days. No multinucleated giant cells were noticed. A repair process predominated after 14 days. Osteogenesis started at 7 days at the margins of the lesion and increased throughout the experimental period filling the bone defect. Subjective analysis

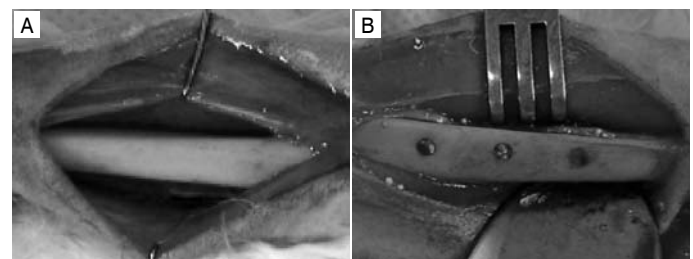


Figure 1: Surgical procedure: .A. View of the tibia after incision and detachment. B. Holes filled with biomaterials and blood.




Figure 2: Macroscopic aspect of the xenografts used. A) Bio-Oss® and B) Osseus®.

suggested a decrease in the size of the particles that were fully incorporated into the bone tissue after 28 days. (Figure 4)

DISCUSSION

White New Zealand rabbits (*Oryctolagus cuniculus*) are frequently used as an animal model in orthopedic and craniomaxillofacial experiments because of the similarity between the bone density and resistance to fractures in these animals and humans.¹⁵

Osteoconductive materials must have a three dimensional structure and a large number of interconnected pores that permit cellular and vascular proliferation, and the formation of granulation tissue within them.¹⁶ They must be biocompatible and absorbable, with slow and controllable degradation, and must possess favorable physico-chemical surface properties that favor cell proliferation. The xenografts tested presented all these characteristics during our experiments, including some degree of material absorption and cell and bone ingrowth. This is probably due to their favorable geometry with their biologically designed pores.

Bone repair depends on an adequate vascular supply with osteoblasts working in the regions adjacent to the blood vessels, where the formation of highly organized bone tissue requires a mechanically stable and solid surface upon which the newly formed bone can be laid.¹⁷ This aspect was demonstrated by microscopic analysis where, at all stages of the experiment,

there was new bone formation originating from the edge of the basophilic devitalized bone and extending over the surface of the biomaterial along with evidence of resorption. This shows the adequacy of the xenograft in providing an adequate framework for revascularization and ossification.¹⁸

A biomaterial is considered biocompatible when it shows a high capacity for inducing the appropriate response in the host for a specific application.^{19,20}

Histopathologic observations confirmed the post-operative clinical evaluation of the animals. There were no negative signs such as suppuration, pain or weight loss. It is worth noting that although the defects in the rabbits' tibia were not of critical size, they were fully repaired with bone in direct contact with the biomaterials, confirming their biocompatibility and osteoconduction. An ideal biomaterial should be osteoconductive, resorbable and susceptible to osteoclastic action so as to permit bone replacement in the grafted area.²⁰ In this study we observed clear evidence that the materials were partially absorbed and replaced with bone tissue at the edge of the biomaterials. (Figure 3B and 3C)

One of the disadvantages of xenografts cited by some authors is the risk of disease transmission, but it is known that anorganic materials such as those used in our experiments offer a lower risk in this regard compared with fresh frozen

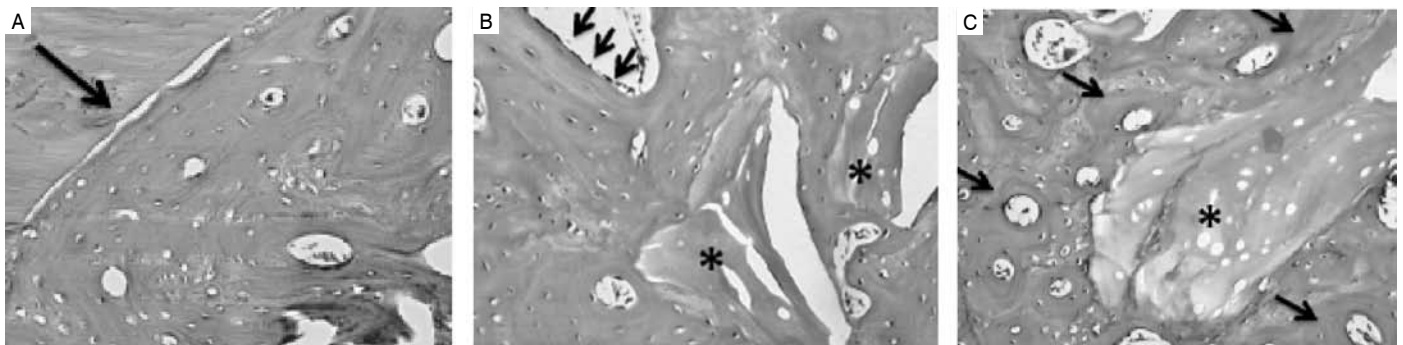


Figure 3: Photomicrograph of bone defect 7 days after surgery. Control group (blood clot): osteogenesis starting at the edge of lesion (arrows, A). Bio-Oss® group: with osteogenesis evident (arrows, B). Osseus® group: osteogenesis involving biomaterial particles (asterisks, C). H&E. Magnifications: A, B: x12.5; C: x25.

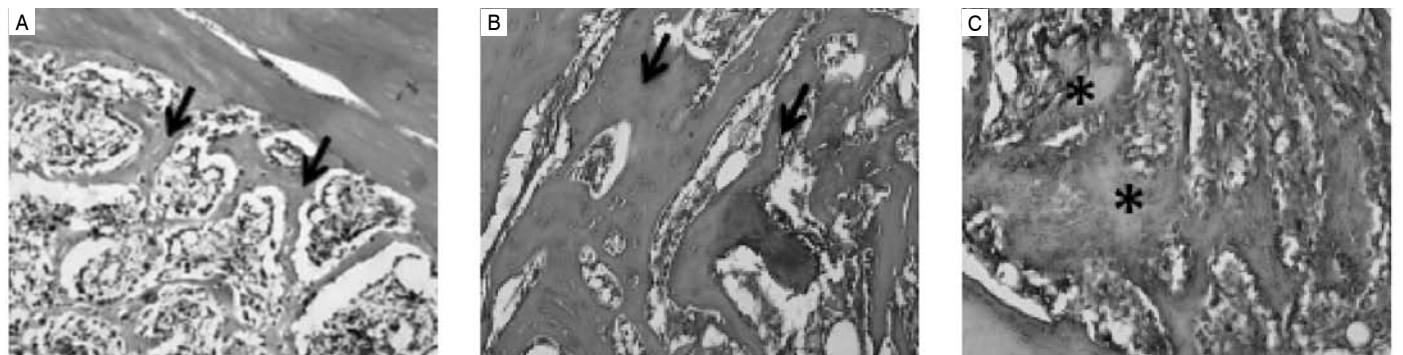


Figure 4: Photomicrograph of bone defect 28 days after surgery. A. Control group (blood clot); the arrow shows the edge of the defect. B. Bio-Oss® group, with arrows showing a layer of osteoblasts and biomaterial. C. Osseus® group. The asterisks show the biomaterial (Osseus®). H&E. Magnification: x12.5.

tissue because of the manner in which they are processed. When the control group (blood clot) was compared with the experimental groups, it always showed better bone neoformation. We attribute this to the slower evolution of bone repair when bone grafts are utilized in a bone cavity or defect, an observation previously made by others.^{3,12,13}

CONCLUSION

Clinical and microscopic observations lead us to conclude that particles of both biomaterials used (Bio-Oss® and Osseus®) are biocompatible, permit direct bone tissue deposition in

contact with the material and are apparently absorbable.

ACKNOWLEDGMENTS

This study was partially financed by SIN – Implant System, Sao Paulo, Brazil, but without any influence on its execution and analysis. Dr. Granjeiro and Dr. Rossi were partly financed by the National Council for Scientific and Technological Development (CNPQ), Fundação Carlos Chagas Filho de Amparo à Pesquisa do Estado do Rio de Janeiro (Cientista do Nosso Estado) and the Department of Science and Technology of the Ministry of Health (DECIT/MS).

REFERENCES

1. Finkemeier CG. Bone grafting and bone graft substitutes. *J Bone Joint Surg Am.* 2002;84:454-65.
2. Misch C. Contemporary Implant dentistry. St. Louis: Mosby; 1999.
3. Granjeiro JM, Oliveira RC, Bustos-Valenzuela JC, Sogayar MC, Taga R. Bone morphogenetic proteins: from structure to clinical use. *Braz J Med Biol Res.* 2005;38:1463-73.
4. Pruss A, Seibold M, Benedix F, Frommelt L, von Garrel T, Gurtler L et al: Validation of the 'Marburg bone bank system' for thermosinfection of allogenic femoral head transplants using selected bacteria, fungi, and spores. *Biologicals.* 2003;31:287-94.
5. Eid K, Zelicof S, Perona BP, Sledge CB, Glowacki J. Tissue reactions to particles of bone-substitute materials in intraosseous and heterotopic sites in rats: discrimination of osteoinduction, osteocompatibility, and inflammation. *J Orthop Res.* 2001;19:962-9.
6. Rosa AL, Shareef MY, Noort RV. Efeito das condições de preparação e sinterização sobre a porosidade da hidroxiapatita. *Pesqui Odontol Bras.* 2000;14:273-7.
7. Yoshikawa T, Ohgushi H, Nakajima H, Yamada E, Ichijima K, Tamai S et al. In vivo osteogenic durability of cultured bone in porous ceramics: a novel method for autogenous bone graft substitution. *Transplantation.* 2000;69:128-34.
8. Macedo CAS, Galia CR, Silva ALB, Cesar PC, Sanches PRS, Duarte LS. Comparação da resistência à compressão do osso bovino congelado e liofilizado. *Rev Bras Ortop.* 1999; 34:529-534.
9. Sanada JT, Canova GC, Cestari TM, Taga EM, Taga R, Buzalaf MAR. Análise histológica, radiográfica e do perfil de imunoglobulinas após a implantação de enxerto de osso esponjoso bovino desmineralizado em bloco em músculo de ratos. *J Appl Oral Sci.* 2003;11:209-15.
10. Wentz B, Oesch B, Horst M. Analysis of the risk of transmission bovine spongiform encephalopathy through bone grafts derived from bovine bone. *Biomaterials.* 2001;22:1599-606.
11. Torricelli P, Fini M, Rocca M, Giavaresi G, Giardino R. Xenogenic demineralized bone matrix: osteoinduction and influence of associated skeletal defects in heterotopic bone formation in rats. *Int Orthop.* 1999;23:178-81.
12. Torricelli P, Fini M, Giavaresi G, Rimondini L, Giardino R. Characterization of bone defect repair in young and aged rat femur induced by xenogenic demineralized bone matrix. *J Periodontol.* 2002;73:1003-9.
13. Calasans-Maia MD, Fernandes GVO, Rossi AM, Dias EP, Almeida GDS, Mitri FF et al. Effect of hydroxyapatite and zinc-containing hydroxyapatite on osseous repair of critical size defect in rat calvaria. *Biocerâmico* 2007; 20 273-6.
14. Conz MB, Granjeiro JM, Soares GA. Physicochemical characterization of six commercial hydroxyapatites for medical-dental applications as bone graft. *J Appl Oral Sci.* 2005;13:136-40.
15. Wang X, Mabrey JD, Agrawal CM. An interspecies comparison of bone fracture properties. *Biomed Mater Eng.* 1998;8:1-9.
16. Hutmacher DW. Scaffolds in tissue engineering bone and cartilage. *Biomaterials.* 2000;21:2529-4
17. Sverzut CE, Lucas MA, Sverzut AT, Trivellato AE, Beloti MM, Rosa AL et al. Bone repair in mandibular body osteotomy after using 2.0 miniplate system--histological and histometric analysis in dogs. *Int J Exp Pathol.* 2008;89:91-7.
18. Sicca CM, Oliveira RC, Silva TL, Cestari TM, Oliveira DT, Buzalaf MAR. Avaliação microscópica e bioquímica da resposta celular a enxertos de osso cortical bovino em subcutâneo de ratos. Efeito do tamanho da partícula. *Rev Fac Odontol Bauru.* 2000;8:1-10.
19. Zambuzzi WF, Oliveira RC, Piozzi R, Cestari TM, Taga R, Buzalaf MAR et al. Avaliação histológica do implante do osso fetal bovino acelular e desmineralizado em subcutâneo de ratos. *Rev Bras Ortop.* 2006;41:227-32.
20. Williams DF. Definitions in biomaterials. In: Proceedings of a consensus conference of the European Society for Biomaterials., New York: Elsevier; 1986.