

# SURGICAL TREATMENT OF PLANOVALGUS FOOT IN CEREBRAL PALSY BY PISANI'S ARTHROEREISIS

LUIZ ANTONIO ÂNGELO DA SILVA, PATRÍCIA MARIA MORAIS DE BARROS FUCS

## ABSTRACT

**Objective:** The goal of this study is to retrospectively evaluate the treatment of the spastic pes planus valgus with the technique presented by Pisani, also the behavior of 12 radiographic parameters. **Methods:** Between February 1992 and December 2002, 29 children (57 feet) with spastic Cerebral Palsy were submitted to surgical treatment, the mean age was six years. The mean follow-up period was eight years and nine months. **Results:** They presented 65% (37 feet) of satisfactory and 35% (20 feet) of unsatisfactory results, according to exclusive clinical criteria at the final revision. From the 12 radiographic parameters studied eight showed statistical significant differences

between the satisfactory and unsatisfactory groups at the final revision with significant correlations. **Conclusion:** Considering that the clinical evaluation was stricted, the severity and the degree of involvement of the patients, the author concluded that Pisani's technique is still a good option when comparing with osteotomies and arthrodesis in the treatment of the still flexible deformities. Among the radiographic angles the mean preoperative value of the talar declination angle of 52° was associated with unsatisfactory result.

**Keywords:** Flatfoot/surgery. Cerebral palsy. Subtalar joint. Orthopedic procedures.

**Citation:** Silva LAA, Fucs PMMB. Surgical treatment of planovalgus foot in cerebral palsy by Pisani's arthroereisis. *Acta Ortop Bras.* [online]. 2010;18(3):162-5. Available from URL: <http://www.scielo.br/aob>

## INTRODUCTION

Planovalgus foot is one of the most frequent deformities and most subject to controversies in cerebral palsy, and is predominant in spastic diplegia, with progressive and debilitating tendency. The deformity has multifactorial etiology and the primary cause appears to be inadequate support of the talus head, influenced by local factors or at proximal level.<sup>1</sup> In actual fact, the primary pathology has been described as a movement of the foot in valgus, external rotation and dorsiflexion relatively to the talus by factors such as: genetic predisposition, ligament laxity, muscular imbalance, delay in the acquisition of normal reactions of balance or persistence of the fetal angulation of the talus neck. The "bowstring" effect of the calcaneal tendon is considered more of a complicating factor than the primary factor of the deformity.

Arthroereisis appears as one of the treatment options and can be defined as a surgical procedure for temporary limitation of joint movements considered excessive, without provoking articular lesion. Historically Chambers<sup>2</sup> was responsible for the first limitation of movement in pronation of the calcaneus inserting a bone wedge below its posterior facet. Lelièvre<sup>3</sup> used the term lateral arthroereisis for the first time. His method is based on the insertion of a metallic staple in the tarsal sinus laterally. In the 80's, Pisani

presented an arthroereisis technique with screw with the following modifications: change of screw (from cortical to cancellous bone), system for introduction and covering by silastic or polypropylene dome of high molecular weight.<sup>4</sup> Fucs et al.<sup>5</sup> utilized the technique proposed by Pisani for the treatment of 18 children (36 feet) with planovalgus foot deformities and spastic cerebral palsy, recommending subsequent studies and revaluations as this technique proves a good alternative to osteotomies and arthrodesis. The aim of this study is to evaluate planovalgus foot treatment in spastic cerebral palsy by Pisani's arthroereisis. The mean follow-up time was above eight years. It is also possible to study the behavior of 12 radiographic parameters, measured at three different times.

## CASUISTRY AND METHODS

In the period from February 1992 to December 2002, in the Department of Orthopedics and Traumatology of Irmandade da Santa Casa de Misericórdia de São Paulo - "Pavilhão Fernandinho Simonsen", 32 children with spastic cerebral palsy were operated with the surgery proposed by Pisani for the treatment of planovalgus feet. Twenty-nine children (57 feet) met the requirements for inclusion in the study and were assessed by the authors in the final revision.

All the authors declare that there is no potential conflict of interest referring to this article.

Faculdade de Ciências Médicas da Santa Casa de São Paulo

Study conducted in the Department of Orthopedics and Traumatology of Irmandade da Santa Casa de Misericórdia de São Paulo. São Paulo, Brazil  
Luiz Antonio Ângelo da Silva - Praça Maurício Curi, 120 sala 02 - Centro Médico Rui Dória - Centro - São José dos Campos, SP, Brazil. CEP 12 210-120 - Email: [luiz\\_ortoinfantil@terra.com.br](mailto:luiz_ortoinfantil@terra.com.br)

Article received on 04/09/08 and approved on 01/23/09

### Inclusion criteria for indication of surgical treatment:

- Children aged  $\leq 8$  years
- Diagnosis of spastic cerebral palsy
- Planovalgus feet correctable by manipulation
- Progressive deformities, despite the conservative treatment.

For inclusion in this study, it was necessary for the operated patients to have: follow-up time  $> 2$  years, complete radiographic sequence and attendance at the final clinical evaluation.

As regards gender, 14 were female and 15 male; as regards skin color, 14 were white (48%) and 15 not white (52%), while as regards the clinical kind of paralysis, 23 were diparetic (79%) and six tetraparetic (21%). Mean age at the time of surgery was 6 years, ranging from 3 years and 9 months to 8 years and 8 months. The mean postoperative follow-up time was 8 years and 9 months (minimum of 2 ½ and maximum of 14 years). The mean time of use of the screw  $\pm$  SD was 4 years and 7 months  $\pm$  2 years and 9 months, with removal in 80% of the feet. There was a description in the medical records of association of deformities at 54%, and frequency of 79% of surgeries performed at other levels during the follow-up time.

### Surgical technique

The patient is placed in the supine position, applying a pneumatic tourniquet on the thigh root. The incision is made on the tarsal sinus, parallel to Langer's cutaneous lines, with dissection by planes, proximal desinsertion of the extensor digitorum brevis muscle, exposure of the upper surface of the calcaneus, perforation of this bone with a 4-mm drill and insertion of a Pisani screw. A 2, 2.5 or 3 mm screw is positioned in the dorsoplantar, lateromedial and proximal-distal direction, with the calcaneus in forced varus and ankle in neutral position, covered by a polyethylene dome of high molecular weight. The correct positioning of the rear foot in relation to the leg axis in the preoperative period is of crucial importance, as the system does not allow another type of postoperative adjustment. By introducing the screw further one achieves less correction of valgism, and a smaller introduction leads to greater correction. (Figure 1) A routine medial procedure is performed at this stage, consisting of the removal of a spindle and suture under tension of the talonavicular joint (capsuloplasty), as well as reinsertion under tension of the tibialis posterior muscle. If necessary the tendons of

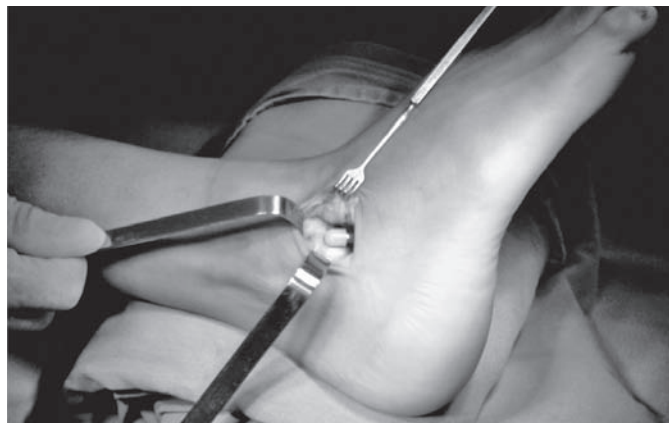


Figure 1 – Intra-operative aspect of the placement of the Pisani screw.

the triceps surae and fibular muscles are elongated. The wounds are sutured by planes and the limb is immobilized in a plaster boot for 4 weeks (or for 6 weeks in cases with elongation of the calcaneal tendon).

A Clinical Evaluation Sheet was drawn up containing a questionnaire, data from the medical record and from the physical exam. The operated feet were classified as satisfactory and unsatisfactory results in the final revision, based exclusively on clinical criteria. Figures 2 and 3 show an example of feet with satisfactory result. To consider a foot clinically satisfactory it was necessary to fulfill all the following criteria, without exception: correction of rearfoot valgism (0 to 10°) and of the medial arch flattening, satisfaction of the patient and/or relatives, absence of additional surgery indication due to consideration of failure of method, absence of complications such as pain or extrusion of screw and absence of hypercorrection.

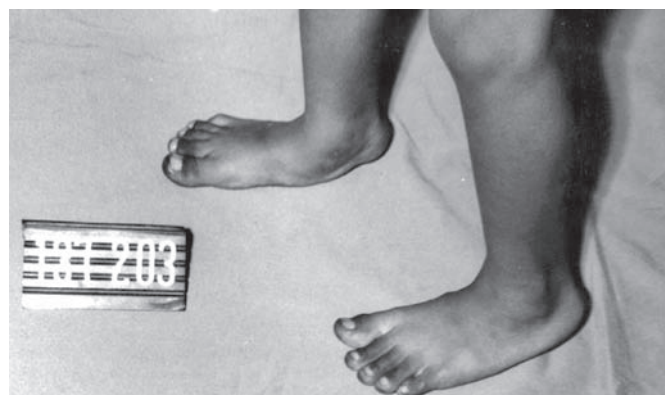

Figure 2 – Case 2, preoperative clinical aspect, medial view.

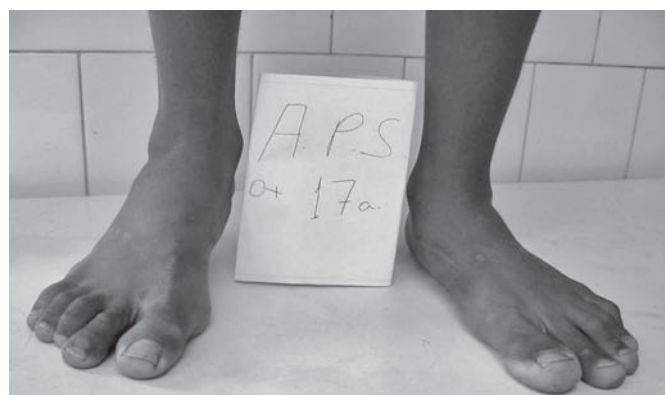


Figure 3 – Case 2, postoperative clinical aspect, viewed from the front.

Twelve radiographic parameters were measured at the following times: preoperative (RX PRE), up to one year postoperative (RX PO) and in the final revision (RX final). In AP incidence – talocalcaneal angle ( $\hat{\alpha}$ T CAP), talar head coverage percentage (%cover), cuboid abduction angle ( $\hat{\alpha}$ abdcub), talo-1st metatarsal angle ( $\hat{\alpha}$ TM), talonavicular angle ( $\hat{\alpha}$ TN) and screw-calcaneal angle ( $\hat{\alpha}$ PC-intersection of the lines traced along the axis of the screw and of the calcaneus); and in lateral - talocalcaneal angle ( $\hat{\alpha}$ TCP), talo-1st metatarsal angle ( $\hat{\alpha}$ TML), talus inclination angle ( $\hat{\alpha}$ i Talus), calcaneal inclination angle ( $\hat{\alpha}$ i Calc), screw inclination angle ( $\hat{\alpha}$ i Screw-intersection of the lines tra-

ced between the axis of the screw and the line parallel to the ground) and Meary's line (LM-line of the long axes of the talus, 1st metatarsal and line perpendicular to the axis vertical to the navicular bone). Figures 4 and 5 show AP and lateral views at the different times.

Statistical analyses were conducted on the qualitative and quantitative data with application of the ANOVA, Mann-Whitney and Fisher's exact tests. The significance level was 5% for all the tests.

## RESULTS

Of the 57 feet submitted to Pisani's arthroereisis technique, 37 (65%) had satisfactory result and 20 (35%) unsatisfactory. No statistically significant association was found between result and age at the time of surgery, duration of presence and removal or not of the screw, proximal deformities by torsion, angulation or in flexion of the knee, clinical types of paralysis, associated calcaneal tendon elongation or acquisition of independent gait. There were complications in 6 feet (11%) due to screw extrusion.

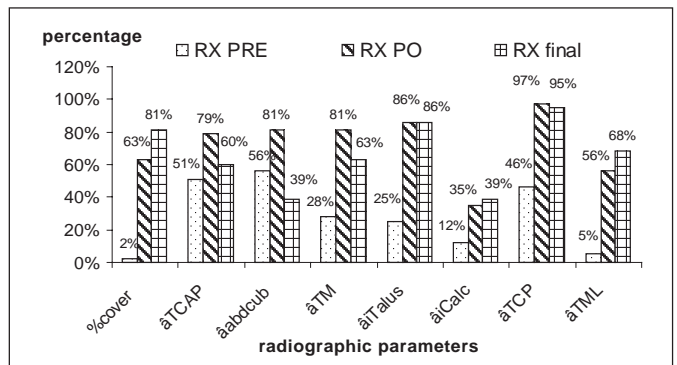
Statistically significant differences were found between the values of the radiographic parameters and the satisfactory and unsatisfactory groups measured at the different evaluation times. In the initial X-ray a higher mean value of  $\hat{\alpha}$ Talus ( $52^\circ$ ) was associated with unsatisfactory result ( $p=0.0036$ ). No statistically significant associations were observed between result and preoperative collapse of the isolated talonavicular joint ( $p=0.4519$ ) or in combination with the naviculocuneiform joint ( $p=0.3653$ ). The range of normality considered, the mean values of the radiographic parameters and their absolute differences, as well as the p values (descriptive level of the ANOVA/Mann-Whitney tests) at the different evaluation times are included in Table 1.

The parameters with defined standards of normality were also categorized as normal or altered. Figure 6 shows the percentage of normality for each parameter at the different times.

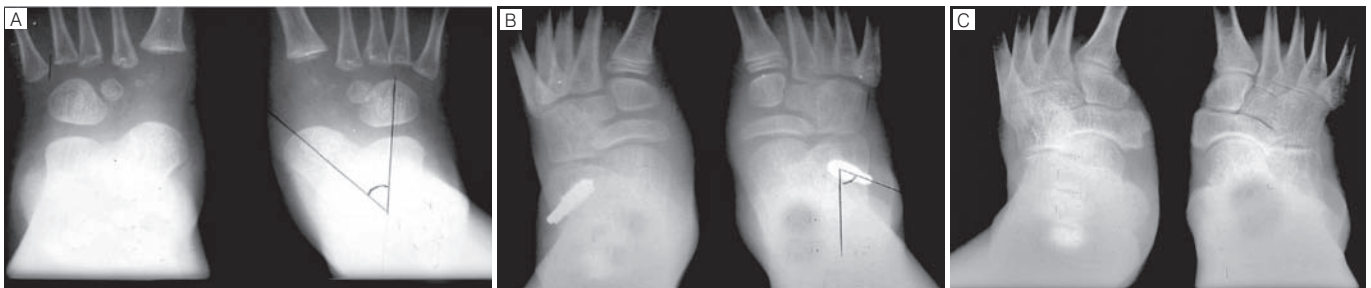
**Table 1** – Normal values, mean values in the preoperative period, up to 1 year postoperative and in the revision, absolute differences between the final RX and the PRE and p values (descriptive level of the ANOVA/Mann-Whitney tests) for the various radiographic parameters, at the different times.

Parameter	Normal Value	Mean I	Mean II	Mean III	Difference	p I	p II	P III.
%cobert	75 to 100%	37%	78%	86%	59%	0.0195	0.2597	0.0000
$\hat{\alpha}$ TCAP	15 a 25°	27°	20°	17°	10°	0.0765	0.0217	0.7699
$\hat{\alpha}$ abd cub	0 a 5°	9°	4°	11°	2°	0.1651	0.0052	0.0090
$\hat{\alpha}$ TN		35°	12°	10°	16°	0.0087	0.3262	0.0132
$\hat{\alpha}$ PC			63°	53°			0.1907	0.4936
$\hat{\alpha}$ TM	0 a 10°	21°	4°	7°	14°	0.0168	0.0270	0.0017
$\hat{\alpha}$ i Talus	$\leq 35^\circ$	45°	28°	28°	17°	0.0036	0.0181	0.0000
$\hat{\alpha}$ i Calc	15 a 30°	6°	11°	13°	8°	0.0007	0.0008	0.0011
$\hat{\alpha}$ TCP	20 a 45°	47°	35°	34°	13°	0.0283	0.3544	0.0004
$\hat{\alpha}$ TML	0 a -15°	-38°	-15°	-15°	23°	0.0050	0.0091	0.0000
$\hat{\alpha}$ i Paraf			92°	103°			0.0395	0.0784

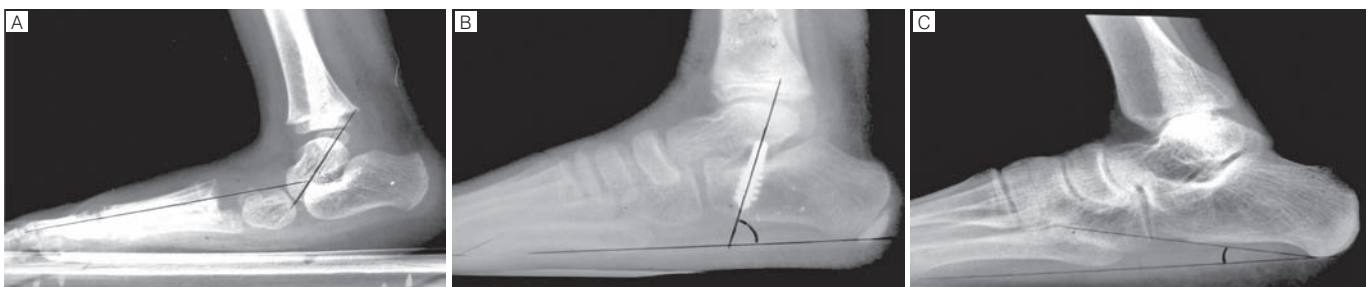I = RX PRE; II = RX PO; III = RX final; p = descriptive level of ANOVA / Mann-Whitney; Difference = RX final - RX PRE.



**Figure 6** – Percentage of normality of the radiographic parameters at the different times, pre- and postoperative periods and final revision.



**Figure 4** – Radiographs of case 2 in AP view, in the preoperative period (a), in the postoperative period (b) and in the final revision (c).



**Figure 5** – Radiographs of case 2 for the left foot in orthostatic position, lateral view in the preoperative period (a), in the postoperative period (b) and in the final revision (c).

## DISCUSSION

There is no consensus at present on several aspects of flat feet in cerebral palsy, such as the type of treatment and the ideal age for its application. Spastic type flat feet, secondary to cerebral palsy, impose additional difficulties due to the interference of proximal biomechanical factors, muscular imbalance, delay in the acquisition of balance reactions or persistence of primitive reflexes.<sup>6,7</sup> There is also difficulty in identifying the most useful preoperative factor that might be related to the type of result, thus offering guidelines for indication and prognosis. There is absence of correlation between the clinical and radiographic results<sup>5,8,9</sup> and a comprehensible quantitative analysis on radiographic measurements has not yet been described. We identified the mean value of the  $\hat{\text{a}}\text{Talus}$  angle in the RX PRE of  $52^\circ$  associated with the unsatisfactory group. The radiographic aspect of "verticalized" talus associated with the unsatisfactory result corresponds to reports from literature.<sup>10</sup>

Crawford et al.<sup>11</sup> believe that arthroereisis serves to bridge a gap that exists between orthoses and arthrodesis for the feet in which angulation in valgus is in the subtalar joint, and is more suitable below the age of 6 years. In an earlier study, Fucs et al.<sup>5</sup> published the result of treatment with Pisani's surgery for 18 patients with spastic cerebral palsy (36 planovalgus feet), encountering 80.5% of satisfactory results (based on clinical and radiographic criteria), and mean follow-up time of 2 years and 9 months. They recommend studying and reevaluating the technique with a longer follow-up time, as it has proven a good option for the treatment of planovalgus foot in cerebral palsy. The clinical type was not an exclusion criterion on account of the age bracket and of the need to potentialize the children's functional gains by good foot alignment.<sup>7</sup> Calcaneal tendon elongation by zetaplasty (in cases of shortening) can interfere negatively in the patient's function. This procedure is questionable in light of the current recommendations.

The authors have reported a lack of parallelism between their clinical and radiographic results, preferring exclusively clinical criteria of evaluation of results.<sup>8,9</sup> The satisfactory result of only 65% of the feet in this study (based on exclusively clinical criteria) was influenced by factors such as: longer follow-up time, feet more subject to deformations, greater acquisition of weight of the child in the growth spurt period, need to meet all the criteria for satisfactory result, high degree of implication by paralysis in the patients studied (reflected by the percentage of associated deformities and of surgeries performed during the follow-up time). There is recommendation for screw removal between 2 and 4 years of age, when permanent alignment is normally maintained.<sup>4</sup> Six feet (11%) presented screw extrusion (considered a complication and unsatisfactory result). This complication can be reduced by the learning curve with the technique.

We encountered statistically significant differences between the result and the following parameters in the final revision: percentage of talar head coverage, cuboid abduction angle, talo-1st metatarsal angle in AP and lateral views, talocalcaneal angle in lateral view, talonavicular angle and inclination angles of the talus and of the calcaneus. (Table 1) We encountered greater sensibility of the % cover, and of the angles  $\hat{\text{a}}\text{TML}$ ,  $\hat{\text{a}}\text{Talus}$  and  $\hat{\text{a}}\text{TN}$  in detecting the changes that occurred after treatment, translated by their higher values in the absolute differences. (Table 1) We suggest studying the normal values of the  $\hat{\text{a}}\text{TN}$  angle in the children, as this angle translates well the relation between the talus and the calcaneus in the AP view, and presents sensibility in recording the changes obtained.

Considering that all the factors influenced the result obtained, we concluded that the arthroereisis procedure with Pisani's screw is a good alternative to osteotomies and arthrodesis for treatment of reducible planovalgus feet in spastic cerebral palsy. The positive factors of the technique are: ease of execution, little or no interference with the osteoarticular tissue of the tarsal sinus, does not hinder other surgical options in the future, lower surgical morbidity, faster return to rehabilitation and stabilization of the subtalar joint (in conformity with the principle of correction of the initial deformity in planovalgus foot). The procedure is very effective on feet with reasonable muscular balance.<sup>12</sup> This study on arthroereisis with screw for treatment of planovalgus foot deformity in cerebral palsy implies a significant follow-up time, follows the same technical standard and was carried out on a group of patients with the same pathology. There is a limited number of publications about arthroereisis in literature and little understanding of aspects of the technique, as well as in relation to planovalgus foot deformity in cerebral palsy.<sup>13,14</sup> For this very reason, we consider it appropriate to measure the 10 radiographic parameters cited most often by literature, and to suggest the measurement of 2 new angles referring to relations of the screw.

## CONCLUSION

Pisani's arthroereisis surgery exhibited 65% of satisfactory and 35% of unsatisfactory result for the treatment of planovalgus foot, evaluated by exclusively clinical criteria. Eight radiographic parameters presented statistically significant differences between the satisfactory and unsatisfactory groups at the time of the final revision ( $\hat{\text{a}}\text{abd cub}$ , %cobert,  $\hat{\text{a}}\text{TM}$ ,  $\hat{\text{a}}\text{TN}$ ,  $\hat{\text{a}}\text{Talus}$ ,  $\hat{\text{a}}\text{Calc}$ ,  $\hat{\text{a}}\text{TCP}$  and  $\hat{\text{a}}\text{TML}$ ). The mean value of the talus inclination angle of  $52^\circ$  in the preoperative period was associated with the unsatisfactory result.

## ACKNOWLEDGMENT

We are grateful to Núcleo de Apoio à Publicação da Faculdade de Ciências Médicas da Santa Casa de São Paulo - NAP-SC for their technical and scientific support to the publication of this manuscript.

## REFERENCES

1. Harris RI, Beath T. Hypermobile flat-foot with short tendo Achillis. *J Bone Joint Surg Am.* 1948;30:116-40.
2. Chambers EFS. An operation for correction of flexible flat feet of adolescents. *Western J Surg.* 1946;54:77-86.
3. Lelievre J. Current concepts and correction in the valgus foot. *Clin Orthop Relat Res.* 1970;70:43-55.
4. Pisani G. *Trattato di chirurgia del piede.* Torino: Edizioni Minerva Medica; 1990.
5. Fucs PMMB, Svartman C, Kertzman P, Kusabara A, Bussolaro FA, Rossetti FTR. Tratamento do pé plano-valgo espástico pela artrorese de Pisani. *Rev Bras Ortop.* 1997;32:145-52.
6. Gunsolus P, Welsh C, Houser C. Equilibrium reactions in the feet of children with spastic cerebral palsy and of normal children. *Dev Med Child Neurol.* 1975;17:580-91.
7. Bleck EE. Spastic diplegia. In: Bleck EE. *Orthopaedic management.* In: *Cerebral palsy.* London: MacKeith Press; 1987. p 359-91.
8. Vedantam R, Capelli AM, Schoenecker PL. Subtalar arthroereisis for the correction of planovalgus foot in children with neuromuscular disorders. *J Pediatr Orthop.* 1998;18:294-8.
9. Andreacchio A, Orellana CA, Miller F, Bowen TR. Lateral column lengthening as treatment for planovalgus foot deformity in ambulatory children with spastic cerebral palsy. *J Pediatr Orthop.* 2000;20:501-5.
10. Bennet GC, Rang M, Jones D. Varus and valgus deformities of the foot in cerebral palsy. *Dev Med Child Neurol.* 1982;24:499-503.
11. Crawford AH, Kucharzyk D, Roy DR, Bilbo J. Subtalar stabilization of the planovalgus foot by staple arthroereisis in young children who have neuromuscular problems. *J Bone Joint Surg Am.* 1990;72:840-5.
12. Smith PA, Millar EA, Sullivan RC. Sta-Peg arthroereisis for treatment of the planovalgus foot in cerebral palsy. *Clin Podiatr Med Surg.* 2000;17:459-69.
13. Vora AM, Tien TR, Parks BG, Schon LC. Correction of moderate and severe acquired flexible flatfoot with medializing calcaneal osteotomy and flexor digitorum longus transfer. *J Bone Joint Surg Am.* 2006;88:1726-34.
14. Schon LC. Subtalar arthroereisis: a new exploration of an old concept. *Foot Ankle Clin.* 2007;12:329-39.