

# VIABILITY OF FETAL CENTRAL NERVOUS SYSTEM CELLS IN THE TREATMENT OF SPINAL CORD INJURY IN RATS

ALEXANDRE FOGAÇA CRISTANTE, MARCELO LOQUETTE DAMASCENO, RAPHAEL MARTUS MARCON, REGINALDO PERILO DE OLIVEIRA, TARCÍSIO ELOY PESSOA DE BARROS FILHO

## ABSTRACT

**Objective:** To propose an experimental model for transplantation of fetal cells from the nervous system of Wistar rats to the site of spinal cord injury in adult rats, to enable their survival and integration for research protocols that identify other factors of regeneration and functional recovery following spinal cord trauma. **Methods:** Twenty adult rats were submitted to laminectomy and a 5mm incision was made, using an optical microscope. In fifteen of these rats, the site of the spinal cord lesion was transplanted

with cells from the fetal rat central nervous system; the rats were monitored for two days, then the spinal cord was removed for histological analysis. **Results:** In 60% of cases, the transplanted cells remained viable in the site of the lesion; the inflammatory response in the transplanted group was always greater than in the control group. **Conclusion:** This study demonstrates the potential use of this research model for use in the transplantation of fetal cells that remain viable two days after their implantation.

**Keywords:** Spinal cord injury. Fetal cells. Rats.

**Citation:** Cristante AF, Damasceno ML, Marcon RM, Oliveira RP, Barros Filho TEP. Viability of fetal central nervous system cells in the treatment of spinal cord injury in rats. *Acta Ortop Bras.* [online]. 2010;18(5):284-90. Available from URL: <http://www.scielo.br/aob>.

## INTRODUCTION

Traumatic spinal cord injury consists of one of the most incapacitating lesions that human beings can suffer and has aroused a great deal of interest in the knowledge of histopathological, biochemical and functional changes, and particularly, in the search for prevention and treatment methods.

Considered an untreatable disease in the past, acute spinal cord injuries<sup>1</sup> originating from spinal traumatism can be minimized with the use of drugs, providing they are administered in a short space of time after the trauma.<sup>2,3</sup> Such advance was mainly due to histological observations that allowed a better understanding of the sequence of events involved in spinal injury.<sup>4</sup>

The first experiments involving the physiopathology of spinal injury were conducted at the beginning of this century. Nevertheless, these studies were only resumed last decade by investigators that started to value time-dependent changes in the pathology of spinal cord trauma.

The immense neurological deficit resulting from spinal cord injury originates from the combination of two different events: the initial mechanical lesion and the secondary endogenous lesion as a consequence of the first.<sup>5,6</sup> The primary lesion is produced by the actual trauma, with death of cells and release of electrolytes,

metabolites and enzymes, therefore representing a mechanical process that is not dependent on cellular control. The secondary lesion of the spinal cord involves complex biochemical changes, appearing as a sequence of events involving edema, inflammation, ischemia, reperfusion, growth factors, calcium metabolism and lipid peroxidasis where scientific efforts are concentrated to enable their control.<sup>7-9</sup> Pharmacologically, drugs that modulate endogenous responses to the primary lesion are being progressively introduced in order to limit tissue damage and to improve the potential for functional recovery of these patients. These drugs aim to interrupt the physiopathological mechanisms of secondary neuronal injury.<sup>10</sup>

Clinical and scientific advances indicate that acute spinal cord injuries can be manipulated by pharmacological therapeutic approaches used in a short space of time. Methylprednisolone administered within the first 8 hours after trauma is the first pharmacological agent to demonstrate significant improvement in the recovery from spinal trauma in human beings.<sup>11-13</sup> Other drugs, such as tirilizade<sup>14</sup> and GM-1,<sup>15,16</sup> still under clinical investigation, present promising preliminary results. These advances can represent a substantial improvement in the quality of life of patients with spinal cord injury, providing they are adopted by clinical practice.

All the authors declare that there is no potential conflict of interest referring to this article.

Medical Research Laboratory of the Musculoskeletal System - LIM41, Department of Orthopedics and Traumatology, FMUSP.

Mailing address: Rua Ovídio Pires de Campos, 333 - 3rd. Floor - CEP: 05403-010, Cerqueira César, São Paulo, SP, Brazil. E-mail: [aacristante@uol.com.br](mailto:aacristante@uol.com.br)

Article received on 8/21/09, approved on 9/25/09

After injuries to the central nervous system there is a deficit period followed by a time of variable functional recovery. Such recovery is mainly due to changes in the uninjured circuits, but the exact recovery process has not yet been completely elucidated. The transplantation of neural cells has helped in studies for the understanding of the development of the CNS and its response to injuries. More recently, such transplantations have been employed in the attempt to optimize post-injury functional recovery. The specific mechanism whereby such transplantations act have not been elucidated either, but there are theories ranging from trophic action through to release of hormones and neurotransmitters and even reinnervation of the host cells by transplanted cells.<sup>17</sup> Current surveys seek to determine which degree of recovery can be achieved with these transplants.

The possibility of fetal nervous system cell use for the treatment of a wide range of pathologies of the Nervous System gave rise to a growing number of studies on the physiology of the survival and integration of the transplant. Today it is known that the transplantation of fetal cells potentiates motor recovery both of immature and of adult individuals; but the mechanism responsible for such an observation remains unknown.<sup>18</sup>

Several fetal nervous system cell transplantation protocols were described, but there is not yet any consensus regarding the best method.<sup>18</sup>

## OBJECTIVE

The aim of this study is to evaluate the viability of a transplantation of cells from the fetal nervous system of rats that allows their survival and integration to enable research protocols that will identify other post-spinal trauma regeneration and functional recovery factors.

## MATERIAL AND METHODS

### Model of spinal cord injury and preparation of the donor tissue

Following the protocol of Barros Filho<sup>19</sup> in his study, sets of one male rat and two female rats were grouped in five cages, and after 12h, vaginal swaps were collected from the female rats then analyzed under an optical microscope for verification of the presence of spermatozoa. The female rats whose vaginal swaps contained sperm cells were considered pregnant and separated in other cage. The process was repeated until four pregnant rats were obtained.

The donor tissue was obtained through cesarean section on pregnant rats on the 14<sup>th</sup> day of gestation with day 0 as the fertilization day. Immediately after the cesarean section, each fetus had its central nervous system removed for inoculation in the spinal cord defect produced in the adult rats.

The injuries produced in 15 rats were analyzed at first. These injuries were produced through laminectomy at T10 and aspiration and gentle microdissection of 5mm of hemispinal cord of the rat.

The donor tissue was then inoculated at the injury site through micropipettes and the injury site was duly sutured. A control group of five rats that underwent the same spinal cord injury as the experimental group, but that had their injury site inoculated with saline solution alone, was analyzed jointly.

Two days after the implant, the rats were euthanized, had their spinal cords surgically excised and submitted to histological analysis to examine the viability of the transplanted cells.

### Rats

The study subjects were Wistar rats from a single supplier. The age of the rats should be 20 weeks and the weight  $240 \pm 40$ g for the females and 270-315g for the males. The rats were obtained one week before the surgery, to allow them to be acclimatized and to become used to handling. The rats should be guaranteed free of pathogens. If more than one rat are kept together after the surgery, attention must be paid to the identification of the rats from the same cage and an attempt be made to keep rats that are related or from the same litter together.

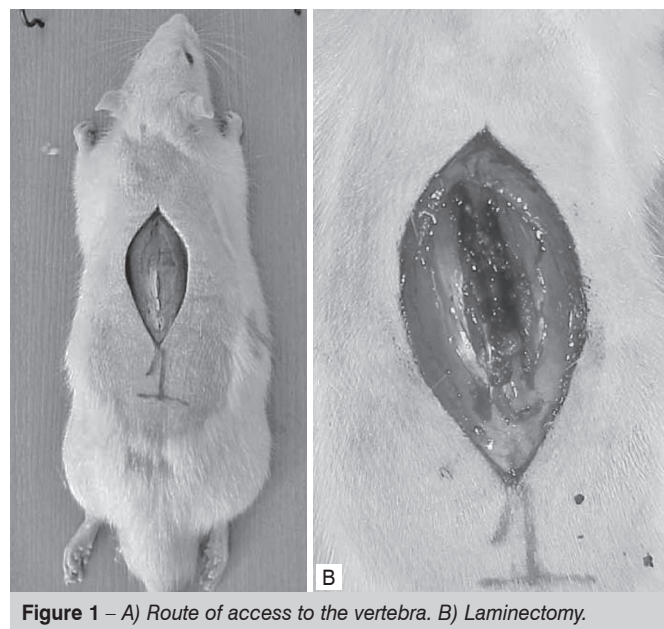
### Anesthetic procedures

The rats are anesthetized with intraperitoneal pentobarbital. The females receive a dose of 35-55 mg/kg and the males a dose of 55-75 mg/kg. The optimal dose should vary depending on many factors. But the rats should start to be anesthetized in 5 minutes. The dose of 35 mg/kg is recommended for females and 55 mg/kg for males. If the initial dose does not anesthetize the rat, no more pentobarbital should be administered. This dose of pentobarbital should anesthetize the rat for approximately 2 hours. Supplementary doses are not recommended. If a rat becomes unacceptably wakeful during the surgery, the experiment should be suspended.

### Laminectomy

The spinal cord is exposed with a laminectomy for the contusion.

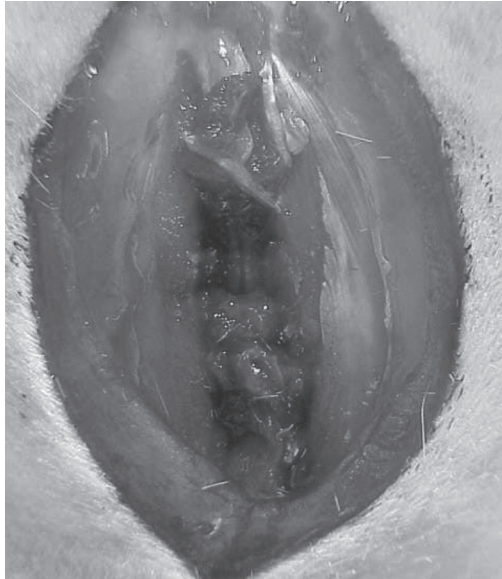- An opening is made in the skin of the mid-dorsal line to expose T10 of the spinal column. (Figure 1A)



**Figure 1** – A) Route of access to the vertebra. B) Laminectomy.

- The muscles inserted in the spiny processes of T9-11 are cut and separated, using a bipolar coagulator to stanch hemorrhages if necessary.

- T10 and the distal half of the spinous process of T9 are removed with a micropunch. The procedure starts from the caudal edge of T10, delicately removing small fragments along the lamina with the micropunch pointing in the direction of the head up to the caudal half of the T9 lamina (Figure 1B). The spinal cord is not injured. (Figure 2)



**Figure 2** – Exposure of the spinal cord.

#### Production of spinal cord injury

- A segment of around 5mm of the hemispinal cord of the rat is removed through aspiration and microdissection with the aid of a microscope.
- The rat is removed and placed on a heated surface. The contusion site is inspected. Any hemorrhage is stanchied. The contusion site is washed with saline solution.

#### Implant material

- The female rats at 14 days of gestation were anesthetized and then underwent laparotomy and hysterectomy. (Figure 3A) The fetuses were removed individually and dried with the aid of a microsurgical technique to isolate embryonic cells from the CNS (Central Nervous System). (Figure 3B) The material obtained was sectioned crosswise in 5mm segments for implant at the injury site.

#### Implant of fetal cells at the injury site

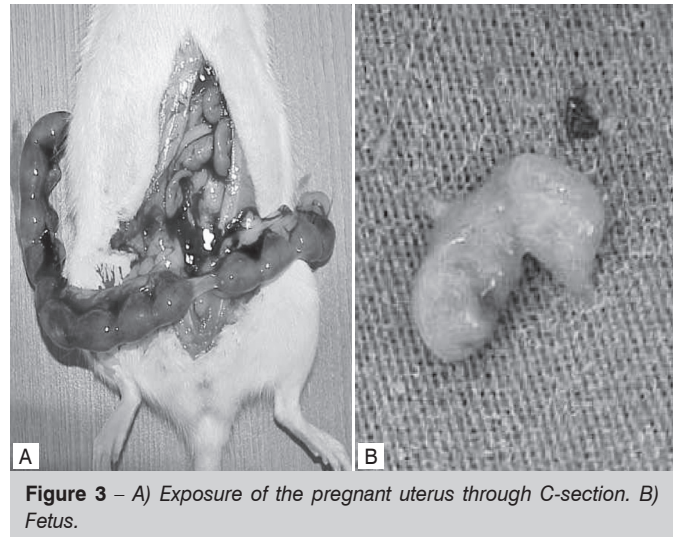
- The segment of fetal CNS already sectioned was implanted at the spinal cord injury site in the adult rats.
- After the implant the dural sac was closed with fibrin glue and the muscular and subcutaneous planes and skin were closed.

#### Control group

Five rats underwent the same procedures as the experimental group, but instead of having their injury sites inoculated with fetal cells, were inoculated with saline solution.

#### Post-injury procedures

For two days after the injury, the rats were observed and had their deficits recorded.

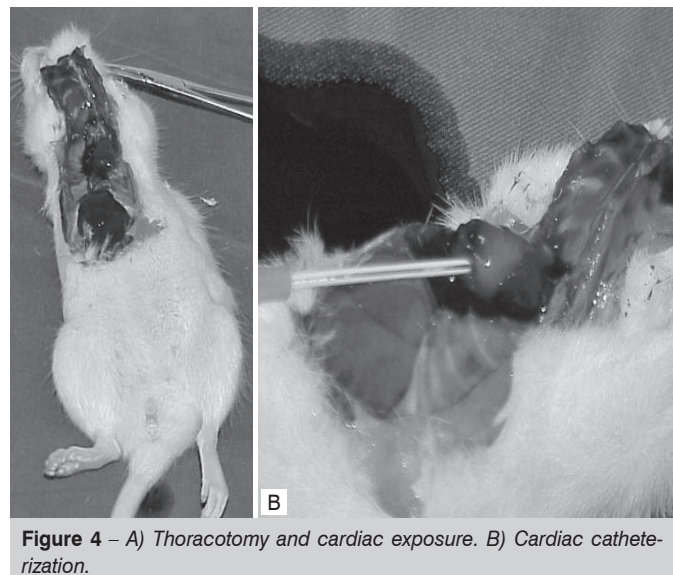


**Figure 3** – A) Exposure of the pregnant uterus through C-section. B) Fetus.

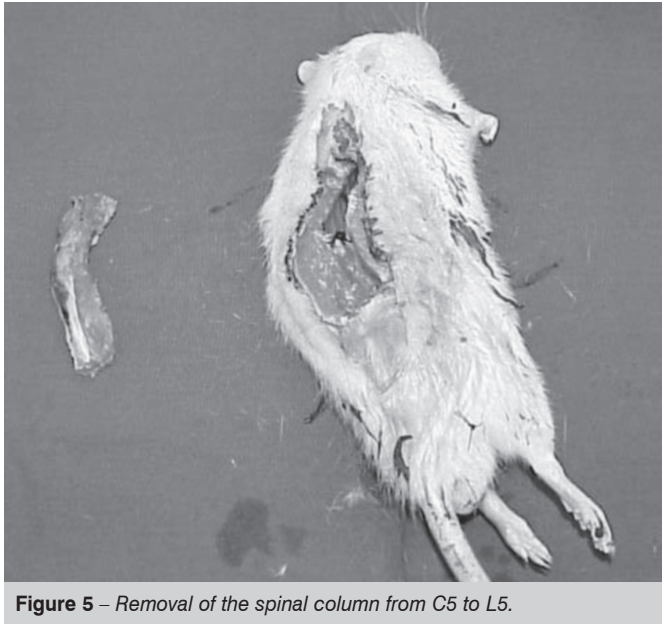
#### Euthanasia and Tissue Samples for Acute Experiments

Euthanasia was performed 2 days after the injury. The procedures for euthanasia and the removal of tissue samples were as follows.

- The rat is weighed to obtain the body weight upon “sacrifice”.
- The rat is anesthetized with a dose of 40 mg/Kg of pentobarbital administered intravenously.
- The rat’s aorta artery was catheterized through thoracotomy to allow the rat to be perfused with a solution of paraformaldehyde. (Figure 4 A,B)
- Sample of the spinal cord.
- The spinal column is quickly removed from C5 to L5, taking off most of the muscles; (Figure 5)
- The column is placed in a centrifugal tube, which is plugged and sealed with Parafilm;
- The tube is labeled with the identification of the rat (experiment, number, etc.).



**Figure 4** – A) Thoracotomy and cardiac exposure. B) Cardiac catheterization.



**Figure 5** – Removal of the spinal column from C5 to L5.

### Necropsy

The following procedures and information should be used and grouped with all the rats.

- The animal is weighed and its identity and sex are confirmed.
- The spinal column and cord are removed.
- The presence of gross abnormalities is checked and noted down. In particular,
  - cystitis or hemorrhagic cystitis;
  - renal, hepatic or myocardial infarction, whether visible or palpable;
  - infection at the surgical site;
  - hemorrhage in the abdominal cavity;
  - pulmonary edema.
- The body is disposed of according to the rules and regulations of the Institutional Review Board of our department.

### Histological analysis of the transplanted spinal cord

The transplanted spinal cord was submitted to histological cuts and had the magnitude of the injury caused, presence and location of the implanted cells and their viability analyzed.

### RESULTS

Through the pairing of one male rat and two female rats, four female rats had vaginal swabs positive for spermatozoa. These all become pregnant and on the 14<sup>th</sup> day of gestation underwent a caesarian section and were sacrificed.

After the spinal cord injury, all the rats exhibited neurological deficits, which ranged from complete monoplegia to complete paraplegia. The clinical finding can subsequently be correlated with the histological finding of the magnitude of spinal cord injury produced according to Table 1:

Two days after the fetal cell implant, all twenty rats survived, with no cases of autophagia, pressure ulcers or infection found.

The histological analysis of spinal cord cuts corresponding to the injury site revealed that the spinal cord injury resulting from microdissection was not uniform, varying from lesions of 40% of the

**Table 1** – Correlation between the spinal cord and histological injuries and the neurological deficit clinically observed in the postoperative period.

RAT	POSTOPERATIVE PERIOD	HISTOLOGICAL SPINAL CORD INJURY
1	monoplegia	40%
2	paraplegia	50%, with hematoma
3	monoplegia	50%
4	paraplegia	50%
5	paraplegia	subtotal
6	paraplegia	subtotal
7	monoplegia	40%
8	paraplegia	subtotal
9	paraplegia	50%
10	monoplegia	40%
11	monoplegia	40%
12	paraplegia	subtotal
13	monoplegia	50%
14	monoplegia	50%
15	paraplegia	70%
16	paraplegia	subtotal
17	monoplegia	40%
18	monoplegia	40%
19	paraplegia	subtotal, with hematoma
20	paraplegia	50%

spinal cord to subtotal lesions. (Figure 6) Hematoma was found at the site of the injury resulting from the injury of the anterior spinal artery in three cases. (Figure 7 A,B and Table 2)

In all the cases in which there was fetal cell implant at the injury site, the analysis of histological cuts of the injury site after 48 hours revealed the presence of the implanted fetal cells. However, in 40% of the cases no fetal cells were identified at the injury site, but only on the lesion path. (Table 3) (Figure 8 A,B and Figure 9 A,B)

Comparing the histological cuts of the spinal cords in which there was transplantation of fetal cells with the cuts of those cords where there was not, we verified the presence of a clearly more intense inflammatory process in the spinal cords where there was transplantation of fetal cells. Such an inflammatory process in general was grouped around the implanted cells. (Table 4)

### DISCUSSION

Traumatic spinal cord injury consists of one of the most incapacitating lesions that human beings can suffer and has aroused a great deal of interest in the knowledge of histopathological, biochemical and functional changes, and particularly, in the search for prevention and treatment methods for the sequelae resulting from spinal trauma.

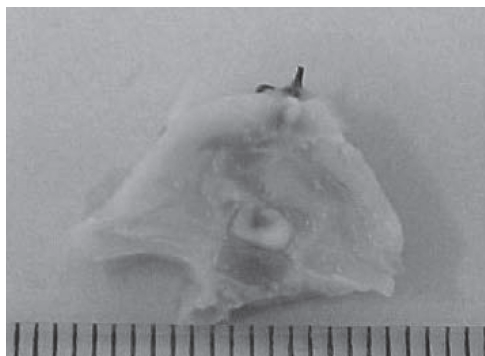
The development of the treatment of spinal cord injury in humans calls for experimental models for drug tests, surgeries and other therapeutic procedures such as the transplantation of cells to the site of the injury. There is not yet any universally accepted model of experimental spinal cord injury in literature, particularly due to the wide diversity of parameters that can be analyzed and that of therapeutic techniques tested.

**Table 2 – Histological analysis of the spinal cord injury.**

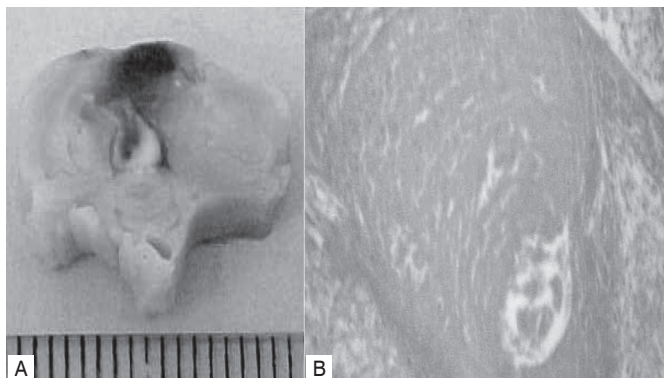
RAT	HISTOLOGICAL SPINAL CORD INJURY
1	40%
2	50%, with hematoma
3	50%
4	50%
5	subtotal
6	subtotal
7	40%
8	subtotal
9	50%
10	40%
11	40%
12	subtotal, with hematoma
13	50%
14	50%
15	70%
16	subtotal
17	40%
18	40%
19	subtotal, with hematoma
20	50%

**Table 3 – Viability and location of the fetal cell implant.**

RAT	IMPLANTATION OF FETAL CELLS	IMPLANTED CELLS
1	yes	at the site and on the path of the injury
2	yes	on the path of the injury
3	yes	at the site and on the path of the injury
4	yes	at the site and on the path of the injury
5	yes	on the path of the injury
6	yes	on the path of the injury
7	yes	at the site and on the path of the injury
8	yes	on the path of the injury
9	yes	on the path of the injury
10	yes	at the site and on the path of the injury
11	yes	at the site and on the path of the injury
12	yes	on the path of the injury
13	yes	at the site and on the path of the injury
14	yes	at the site and on the path of the injury
15	yes	at the site and on the path of the injury
16	no	
17	no	
18	no	
19	no	
20	no	



**Figure 6 – Macroscopic section of the spinal column evidencing the path of the lesion and spinal cord injury.**



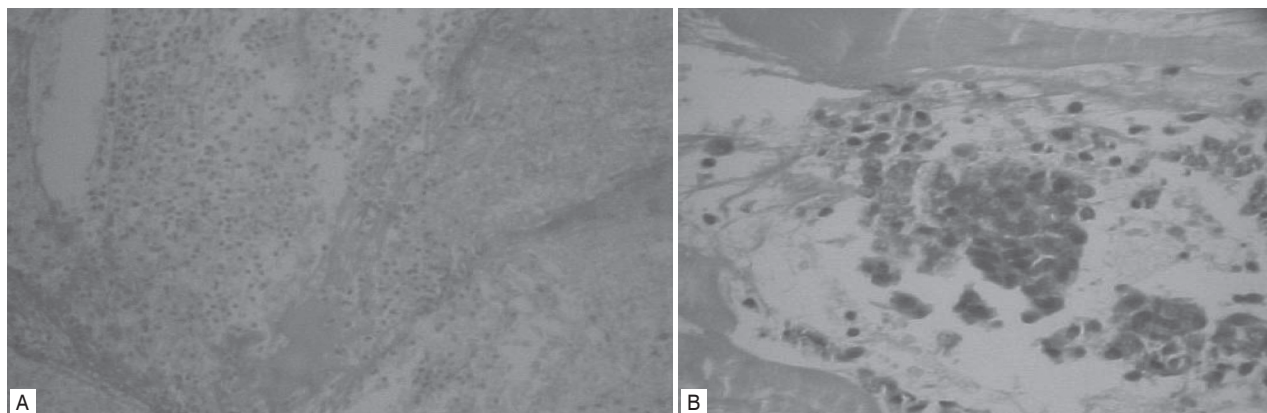
**Figure 7 – A) Macroscopic section of the spinal column evidencing spinal cord injury of 50% and hematoma on the path of the lesion. B) Microscopic section evidencing intramedullary hematoma.**

Open experimental spinal cord injuries are those that create the best conditions for study. Closed injuries produce fractures with fragments that alter the natural course subject matter of the study. Directly exposed spinal cord can be sectioned or bruised. There are experimental methods that employ impact such as fall of weight causing spinal cord injury; crushing of the spinal cord with special aneurysm forceps; extradural balloons that are gradually insufflated; injury by radiofrequency and microdissection. The model considered ideal would be one that combined the trauma mechanism generally found in humans, reproducibility and possibility of being quantifiable. However, such a model has not yet been described.

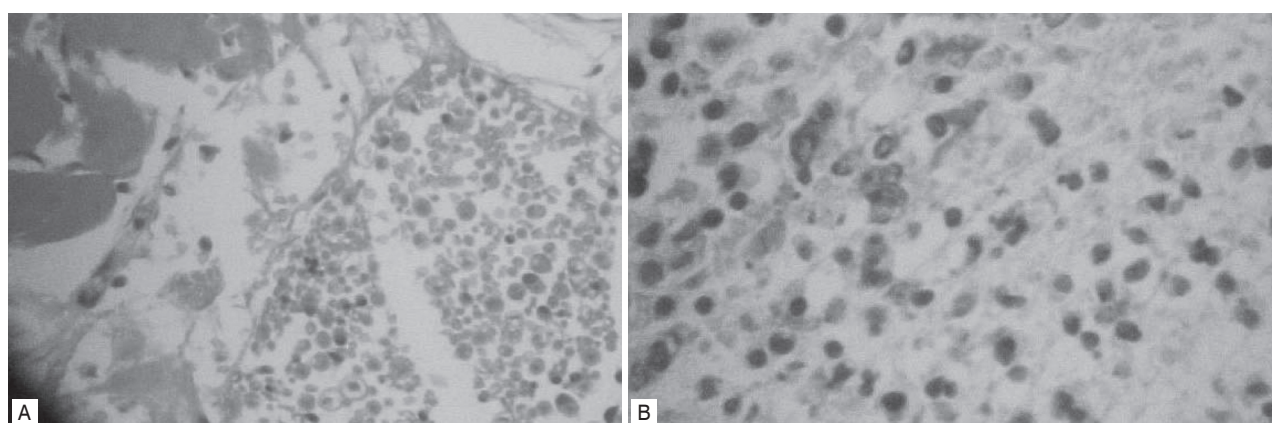
Our study employed the method of laminectomy and microdissection of 5mm of hemispinal cord to adapt to the goals of this first project of the line of research that consists of analyzing the location and viability of a segment of 5mm of fetal CNS implanted at the injury site.

The histological analysis of spinal cord injury revealed that the microdissection method, although performed with the aid of a microscope, produced unequal injuries, generally larger than 50% of the spinal cord. Such observation did not impair the goal of this study in evaluating the histological presence of fetal cells 48h after the implant, but it does require alterations for greater standardization of the injury in subsequent studies of this line of research that will include studies of the chronic phase of spinal cord injury with functional evaluations with scales for locomotion, electrophysiological and anatomopathological studies.

We opted for the use of Wistar rats due to their availability in our environment and the reduced technical difficulties in the handling of these animals. The preferential species for experi-



**Figure 8** – A) Microscopic section evidencing grouping of fetal cells on the path of the lesion and in the subarachnoid space. B) Microscopic section with less zoom evidencing grouping of fetal cells in the muscle.



**Figure 9** – A) Microscopic section evidencing grouping of fetal cells at the injury site. B) Section with less zoom of the grouping of fetal cells at the injury site.

**Table 4** – Magnitude of the inflammatory process 48 hours after the injury.

RAT	yes	at the site and on the path of the injury	discrete to moderate
1	yes	on the path of the injury	moderate to intense
2	yes	at the site and on the path of the injury	discrete
3	yes	at the site and on the path of the injury	moderate to intense
4	yes	on the path of the injury	moderate to intense
5	yes	on the path of the injury	moderate
6	yes	at the site and on the path of the injury	moderate
7	yes	on the path of the injury	moderate
8	yes	on the path of the injury	moderate
9	yes	at the site and on the path of the injury	intense
10	yes	at the site and on the path of the injury	discrete
11	yes	on the path of the injury	moderate to intense
12	yes	at the site and on the path of the injury	discrete
13	yes	at the site and on the path of the injury	discrete
14	no	at the site and on the path of the injury	moderate to intense
15	no		absent
16	no		absent
17	no		absent
18	no		absent
19	no		absent
20	não		ausente

ments with spinal cord injury should be that of the primates, but their use is limited on account of the high cost, limited availability, handling difficulties and ethical considerations.<sup>5</sup> The rat can be a good alternative in these experiments since its spinal cord has cytoarchitectonic organization and vascularization similar to that of humans.<sup>5</sup>

In our study there were no deaths, infection, autophagia or pressure ulcers due to the use of anesthetic technique with pentobarbital, aseptic surgical technique, maintenance of the rats in an environment with controlled temperature and lined cages. Such complications would probably occur if the rats were kept for longer periods.

The transplantation of cells from the central nervous system has been employed in the last twenty years and helps to increase the understanding of nervous system development and of the response of neurons to injuries. More recently, studies involving central nervous system cell transplantations have been geared toward restoring or decreasing the loss of function resulting from the injury. It was proved that transplants can decrease the deficits or even increase the functional recovery resulting from damage to the central nervous system, especially in cases of degenerative diseases. Transplantations can influence recovery of post-CNS damage function through a large variety of mechanisms: such as non-specific consequences of transplantations, trophic actions, release of hormones and transmitters, and also through more

specific mechanisms involving reinnervation of host cells and establishment of reciprocal connections between the transplanted tissue and the host tissue.<sup>17</sup>

The requisites for anatomical and functional repair after spinal cord injury are more complex than those for recovery of other types of neurological damage that generally require only restoration of the levels of neurotransmitters to allow important functional recovery.<sup>17</sup> There are several mechanisms through which the transplantation of fetal cells can affect the tissue response to injury and mediate post-injury functional recovery. The transplantation of fetal central nervous system cells can serve as a bridge between the spinal cord and the supraspinal levels through the injury site; it can supply a population of cells at the injury site that can serve as a substrate for the reestablishment of cellular communication between the supra- and infralesional levels. At the cellular level, the transplantation can provide trophic support to mature and immature neurons, inhibit glial scar formation at the injury site, and provide mechanically favorable substrate, from extracellular matrix for neuronal growth through the injury site.

Transplantation using central nervous system cells can improve the post-spinal cord injury locomotor function and provide a more

complex microenvironment than the environment provided by the transplantation of peripheral nerves, suspension of cells or of genetically modified cells.<sup>18</sup>

In our study, the histological analysis of the injury site revealed the presence of viable fetal cells at the injury site in 9 of the 15 rats (60%) submitted to the transplantation of fetal CNS cells. In 40% of the cases the fetal cells were not found at the injury site, but only on its path.

In comparison to the control group where there was no implantation of fetal cells, the histological analysis revealed more intense inflammatory process in the spinal cords submitted to the implantation of fetal cells. Said process was located around the implanted cells.

## CONCLUSIONS

This study demonstrated the viability of fetal cells of rats transplanted at the spinal cord injury site in adult rats 48 hours after their implantation. Along this line of research, studies will be conducted on the chronic phase of the spinal cord injury and of the long and medium-term viability of fetal cells with anatomopathological and functional assessments by the locomotor scale.

## REFERENCES

1. Breasted JH. *The Edwin Smith Papyrus*. Chicago: University of Chicago Press; 1930.
2. Behrmann DL, Bresnahan JC, Beattie MS. Modeling of acute spinal cord injury in the rat: neuroprotection and enhanced recovery with methylprednisolone, U-74006F and YM-14673. *Exp Neurol*. 1994;126:61-75.
3. Faden AI, Salzman S. Pharmacological strategies in CNS trauma. *Trends Pharmacol Sci*. 1992;13:29-35.
4. Behrmann DL, Bresnahan JC, Beattie MS, Shah BR. Spinal cord injury produced by consistent mechanical displacement of the cord in rats: behavioral and histologic analysis. *J Neurotrauma*. 1992;9:197-217.
5. Balentine JD. Pathology of experimental spinal cord trauma. II. Ultrastructure of axons and myelin. *Lab Invest*. 1978;39:254-66.
6. Goodkin R, Campbell JB. Sequential pathologic changes in spinal cord injury: a preliminary report. *Surg Forum*. 1969;20:430-2.
7. Holtz A, Nyström B, Gerdin B. Spinal cord blood flow measured by <sup>14</sup>C-iodo-antipyrine autoradiography during and after graded spinal cord compression in rats. *Surg Neurol*. 1989;31:350-60.
8. Noble LJ, Wrathall JR. Distribution and time course of protein extravasation in the rat spinal cord after contusive injury. *Brain Res*. 1989;482:57-66.
9. Tator CH, Fehlings MG. Review of the secondary injury theory of acute spinal cord trauma with emphasis on vascular mechanisms. *J Neurosurg*. 1991;75:15-26.
10. Faden AI, Ellison JA, Noble LJ. Effects of competitive and non-competitive NMDA receptor antagonists in spinal cord injury. *Eur J Pharmacol*. 1990;175:165-74.
11. De Ley G, Leybaert L. Effect of flunarizine and methylprednisolone on functional recovery after experimental spinal injury. *J Neurotrauma*. 1993;10:25-35.
12. Hall ED. The effects of glucocorticoid and nonglucocorticoid steroids on acute neuronal degeneration. In: Sell FJ, editor. *Advances in neurology*. New York: Raven; 1993. p.241-8.
13. Hall ED, Yonkers PA, Andrus PK, Cox JW, Anderson DK. Biochemistry and pharmacology of lipid antioxidants in acute brain and spinal cord injury. *J Neurotrauma*. 1992;9(Suppl2):S425-42.
14. Anderson DK, Braugher JM, Hall ED, Waters TR, McCall JM, Means ED. Effects of treatment with U-74006F on neurological outcome following experimental spinal cord injury. *J Neurosurg*. 1988;69:562-7.
15. Geisler FH, Dorsey FC, Coleman WP. Past and current clinical studies with GM-1 ganglioside in acute spinal cord injury. *Ann Emerg Med*. 1993;22:1041-7.
16. Young W. Recovery mechanisms in spinal cord injury: implications for regenerative therapy. In: Seil AJ, editor. *Neural regeneration and transplantation*. New York: Alan Liss; 1995. p.157-9.
17. Bregman BS, Bagden EK. Potential Mechanisms underlying transplant mediated recovery of function after spinal cord injury. In: Marwah J, Teitelbaum H, Prasad KN. *Neural transplantation, CNS neuronal injuries and regeneration*. 2nd. ed. New York: CRC Press Inc; 1994. p.81-102.
18. Horner PJ, Popovich PG, Reier PJ, Stokes BT. Fetal spinal transplant vascularity: metabolic and immunology mechanisms. In: Marwah J, Teitelbaum H, Prasad KN editors. *Neural transplantation: CNS neuronal injury, and regeneration*. New York: CRC Press Inc; 1994. p.119-40.
19. de Barros Filho TE, de Oliveira RP, Tsanaclis AM, de Barros EM, Cristante AF, Palma RM et al. An experimental model for the transplantation of fetal central nervous system cells to the injured spinal cord in rats. *Rev Hosp Clin Fac Med Sao Paulo*. 2002;57:257-64.