

# TOMOGRAPHIC ANALYSIS FOR C2 SCREW PLACEMENT IN RHEUMATOID ARTHRITIS PATIENTS

RODRIGO SCHROLL ASTOLFI, WILSON TADAO TACHIBANA, OLAVO BIRAGHI LETAIF, ALEXANDRE FOGAÇA CRISTANTE, REGINALDO PERILO OLIVEIRA, TARCÍSIO ELOY PESSOA DE BARROS FILHO

## ABSTRACT

**Objective:** A morphological analysis of the bone structure of C2 in patients with rheumatoid arthritis in order to enhance the security of the stabilization procedures for this vertebra. **Methods:** We retrospectively analyzed 20 CT scans of the cervical spine performed in patients with rheumatoid arthritis; the following parameters were measured: spinolaminar angle, thickness and length of C2 lamina. **Results:** The mean values are: 5.92mm and 5.87mm for thickness of right and left laminae

retrospectively, 27.75mm for right lamina length and 27.94mm for left lamina length, and 44.7° for spinolaminar angle. **Conclusion:** The values obtained are consistent with studies in normal subjects published by other groups, with no apparent need for change in the screw placement technique. **Level of Evidence IV, Case Series.**

**Keywords:** Axis. Arthritis, rheumatoid/radiography. Arthritis, rheumatoid/surgery. Anatomy.

**Citation:** Astolfi RS, Tachibana WT, Letaif OB, Cristante AF, Oliveira RP, Barros Filho TE. Tomographic analysis for C2 screw placement in rheumatoid arthritis patients. *Acta Ortop Bras.* [online]. 2012;21(4): 207-9. Available from URL: <http://www.scielo.br/aob>.

## INTRODUCTION

The cervical region is commonly affected in rheumatoid arthritis. The frequency of clinical and radiographic involvement is as high as 72.5%.<sup>1</sup> The physiopathology of the disease includes synovitis of the apophyseal joints, ligamentous laxity, loss of articular cartilage and bone erosion.<sup>2</sup> The three most common lesions are: atlanto-axial subluxation (C1-C2), subaxial dislocation (below C2) and the destruction of the atlanto-axial and atlanto-occipital joints, leading to settling of the skull on the odontoid.<sup>3</sup> Although cervical involvement is frequent, only a small percentage of patients have surgical indication. The indications for arthrodesis are: pain, instability and neurological deficit.<sup>4</sup>

Various techniques are used for stabilization of the upper cervical spine with laminar screws.<sup>5-7</sup> Previous anatomical and<sup>8,9</sup> tomographic studies<sup>10</sup> evaluated the bone morphology of C2 in normal individuals with the objective of optimizing the safety of these methods. Other studies investigated the morphologic alterations of this region in patients with rheumatoid arthritis, but none of them focused on characterizing laminar alterations of C2 that would jeopardize surgical procedures at this site.<sup>1-4</sup> This study addresses measurements of the bone structure of C2 in tomography scans of patients with rheumatoid arthritis.

## MATERIALS AND METHODS

We retrospectively analyzed 20 tomography scans of patients with rheumatoid arthritis acquired for diagnosis and surgical planning. The dimensions and angulations of the laminae were evaluated using the ImageJ<sup>®</sup> imaging program.

The lamina thickness was measured in millimeters. In the axial section of C2 where the greatest laminar thickness was noted, the measurement was taken at the point of least thickness of each lamina in the chosen section. The thickness of the trabecular tissue was measured in the intercortical space. (Figure 1) Each measurement was taken specifically for each side of the lamina. The length of the laminae was measured in the same axial section. The measurement was taken from the cortex opposite the lamina up to the limit of the length visible in that section. (Figure 2) The spinolaminar angle was traced for both sides, with one of the lines inside the C2 lamina parallel to the cortex of this lamina, and another line passing longitudinally through the spinous process of this vertebra. (Figure 3)

## RESULTS

Of the 20 tomography scans included in the study, 17 belonged to female patients and three to male patients. The average age of the patients from the study was 59 years for men and 60.4

All the authors declare that there is no potential conflict of interest referring to this article.

*Institute of Orthopedics and Traumatology of Hospital das Clínicas of the School of Medicine of Universidade de São Paulo.*

*Study conducted at LIM 41 – Laboratory of Medical Investigation of the Musculoskeletal System of the Department of Orthopedics and Traumatology of the School of Medicine of Universidade de São Paulo.*

*Mailing address: Rua Teodoro Sampaio, 363, apto 211. Bairro Pinheiros, 05405-000, São Paulo, SP, Brazil. Email: aacristante@uol.com.br*

Received on 8/8/2011 and approved on 8/25/2011.

*Acta Ortop Bras.* 2012;20(4): 207-9

years for women. The mean found for the spinolaminar angle was  $44.70^\circ$  (CI 95%  $41.77^\circ - 47.64^\circ$ ), while other means and their standard deviations are illustrated in Table 1. The comparative analysis between right and left sides for total lamina thickness, trabecular tissue thickness and lamina length,

did not reveal any difference between the sides ( $p = 0.852, 0.715, 0.731$  respectively). Table 2 contains the maximum and minimum limits of lamina thickness and length. Table 3 presents the values of the same parameters in healthy individuals obtained in a previous study.<sup>10</sup>

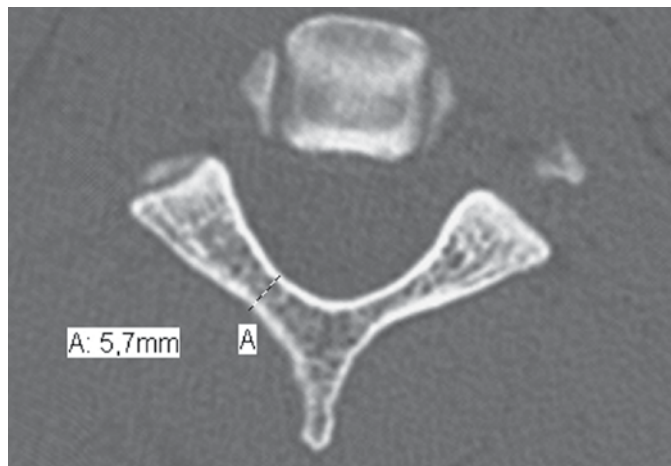


Figure 1. Measurement of the thickness of the laminae.

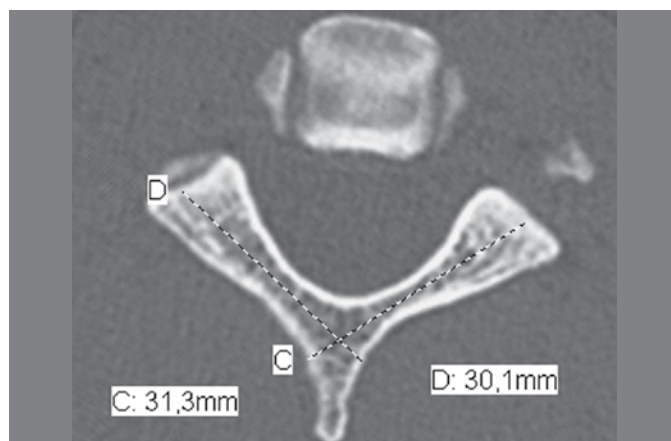


Figure 2. Measurement of the length of the laminae.

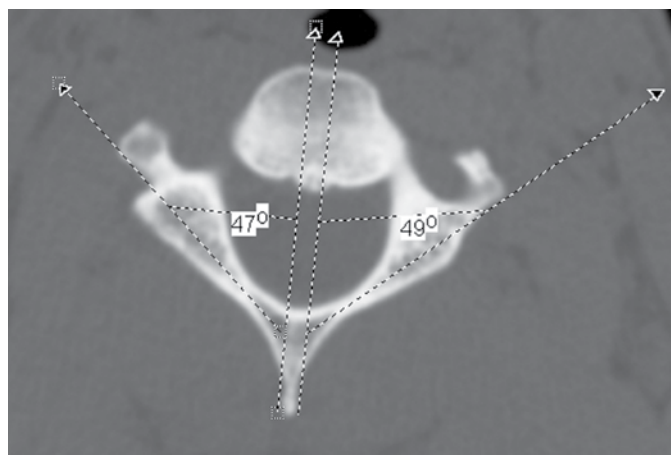


Figure 3. Measurement of the right (A) and left (B) spinolaminar angle of the vertebra.

Table 1. Means and standard deviations obtained for total lamina thickness, trabecular tissue thickness and lamina length.

	Lamina thickness	Trabecular tissue thickness	Lamina length
Right	5.92 mm ( $\pm 1.15$ )	3.29 mm ( $\pm 1.13$ )	27.75 mm ( $\pm 6.66$ )
Left	5.87 mm ( $\pm 1.01$ )	3.18 mm ( $\pm 1.10$ )	27.94 mm ( $\pm 6.51$ )

Table 2. Maximum and minimum values of thickness and length obtained.

	Laminar thickness	Laminar length
Maximum value	8.4 mm	34.6 mm
Minimum value	3.7 mm	26.6 mm

Table 3. Comparison between the means of thickness, length and spinolaminar angle obtained in healthy patients and patients with rheumatoid arthritis.

	Lamina thickness	Lamina length	Spinolaminar angle
Rheumatoid Arthritis	5.89 mm	27.84 mm	$44.7^\circ$
Healthy individuals	5.99 mm	29.60 mm	$46.8^\circ$

## DISCUSSION

In the current literature we found various studies that use imaging methods to characterize the degenerations of the atlanto-axial joint of patients with rheumatoid arthritis.<sup>1-3,11,12</sup> However, these studies are focused on the degenerative alterations of the joint and the development of instability. We do not find any study indicating the need for special precautions did the passage of intralaminar screws in patients with rheumatoid arthritis, such as passage of screws of reduced diameter or length due to deformities in the medullary canal of the C2 laminae.

It is a small study, with 20 cases, and only three male patients. Due to the disproportion between the sexes, it was not possible to conduct a comparative analysis between men and women. In the non-statistical comparison, with the results found in healthy individuals for the same parameters, published in a previous study by our group,<sup>10</sup> we realized that the values obtained are equivalent, suggesting that in spite of the multiple joint alterations that develop with the pathology, there is no significant alteration of the morphology of the C2 vertebra.

The results of this study aim to corroborate the idea that the atlanto-axial stabilization procedures currently considered safe

for healthy patients, are also safe for patients with rheumatoid arthritis, besides demonstrating that the passage of C2 intralaminar screws is safe, in observing that the minimum sizes found are larger than most of the screws used in this region (minimum thickness 3.7mm, minimum length 26.6mm).

## CONCLUSION

The results obtained in the morphological analyses of C2 in patients with rheumatoid arthritis are similar to those of healthy patients, suggesting that there is no need to alter the placement technique of C2 intralaminar screws in patients with rheumatoid arthritis.

## REFERENCES

1. Younes M, Belghali S, Kriâa S, Zrour S, Bejia I, Touzi M et al. Compared imaging of the rheumatoid cervical spine: prevalence study and associated factors. *Joint Bone Spine*. 2009;76:361-8.
2. Sorimachi Y, Iizuka H, Ara T, Nishinome M, Iizuka Y, Nakajima T et al. Atlanto-axial joint of atlanto-axial subluxation patients due to rheumatoid arthritis before and after surgery, morphological evaluation using CT reconstruction. *Eur Spine J*. 2011;20(5):798-803.
3. Yurube T, Sumi M, Nishida K, Takabatake M, Kohyama K, Matsubara T, et al. Progression of cervical spine instabilities in rheumatoid arthritis: a prospective cohort study of outpatients over 5 years. *Spine (Phila Pa 1976)*. 2011;36(8):647-53.
4. Kolen ER, Schmidt MH. Rheumatoid arthritis of the cervical spine. *Semin Neurol*. 2002;22(2):179-86.
5. Krauss WE, Bledsoe JM, Clarke MJ, Nottmeier EW, Pichelmann MA. Rheumatoid arthritis of the craniovertebral junction. *Neurosurgery*. 2010;66(3 Suppl):83-95.
6. Margel F, Seemann P. Stable posterior fusion of the atlas and axis by transarticular screw fixation. In: Kehr P, editor. *Cervical spine*. Vienna, Austria: Springer-Verlag; 1987p322-7.
7. Wertheim SB, Bohlman HH. Occipitocervical fusion. Indications, technique, and long-term results in thirteen patients. *J Bone Joint Surg Am*. 1987;69(6):833-6.
8. Xu R, Burgar A, Ebraheim NA, Yeasting RA. The quantitative anatomy of the laminae of the spine. *Spine (Phila Pa 1976)*. 1999;24(2):107-13.
9. Cassinelli EH, Lee M, Skalak A, Ahn NU, Wright NM. Anatomic considerations for the placement of C2 laminar screws. *Spine (Phila Pa 1976)*. 2006;31(24):2767-71.
10. Rocha ID, Jorge DMF, Pasqualin T, Lutaka AS, Rodrigues MB, Oliveira RP et al. Análise tomográfica para colocação de parafusos intralaminares em C2. *Coluna/Columna*. 2008;7(2):230-4.
11. Iizuka H, Nishinome M, Sorimachi Y, Ara T, Nakajima T, Iizuka Y et al. The characteristics of bony ankylosis of the facet joint of the upper cervical spine in rheumatoid arthritis patients. *Eur Spine J*. 2009;18(8):1130-4.
12. Nagayoshi R, Ijiri K, Takenouchi T, Taketomi E, Sakakima H, Komiya S. Evaluation of occipitocervical subluxation in rheumatoid arthritis patients, using coronal-view reconstructive computed tomography. *Spine (Phila Pa 1976)*. 2009;34(24):E879-81.