

# THORACOLUMBAR BURST FRACTURE: RADIOGRAPHIC EVALUATION ON DIFFERENCES BETWEEN MAGERL'S A AND B

CARLOS ALBERTO ALMEIDA DE ASSUNÇÃO FILHO, RAFAEL PARIZZI VELOSO, ROBERT MEVES, JOÃO PAULO BERGAMASCHI, MARIA FERNANDA SILBER CAFFARO, OSMAR AVANZI

## ABSTRACT

*Objective:* Evaluate incidence of Magerl's A and B group in thoracolumbar burst fracture (Denis) according to independent examiners. *Method:* According to the posterior spinous process split on the anterior posterior radiography, three independent examiners have analyzed the patients admitted from 2000 to 2009 with thoracolumbar burst fractures (according to Denis) to differentiate between Magerl's type A3 and B1.2. *Statistical evaluation* was descriptive and by using Kappa's method. *Results:* From the 72 patients, 11 patients compose the Magerl's type B group

according to examiner 1; 10 according to examiner 2; and 17 according to examiner 3. *Posterior lesion concordance* was satisfactory (good,  $\kappa=0.7$ ) between the examiners. *Conclusion:* 14 to 24% patients with thoracolumbar fractures show posterior lesion (B1.2) by using radiographic criteria. **Level of Evidence III, Diagnostic Studies Investigating a Diagnostic Test.**

**Keywords:** Spinal fractures/classification. Lumbar vertebrae. Thoracic vertebrae.

**Citation:** Assunção Filho CAA, Veloso RP, Meves R, Bergamaschi JP, Caffaro MFS, Avanzi O. Thoracolumbar burst fracture: Radiographic evaluation on differences between Magerl's A and B. *Acta Ortop Bras.* [online]. 2012;20(4): 240-2. Available from URL: <http://www.scielo.br/aob>.

## INTRODUCTION

The thoracolumbar burst fracture generally occurs in young individuals and those of productive age after high-energy trauma.<sup>1,2</sup> The thoracolumbar transition is the area most vulnerable to trauma due to the loss of stabilization afforded by the ribs and thoracic musculature; the transition from the kyphotic thoracic curvature to lordotic lumbar and the change in orientation of the articular facets from coronal in the thoracic spine to sagittal in the lumbar spine.<sup>3,4</sup> About 90% of all spinal fractures occur between T11 and L4, while from 14 to 17% are classified as burst. 44% to 60% of thoracolumbar fractures occur from T11 to L1 with presence of neurological impairment in 26% of the patients.<sup>5-8</sup> Denis<sup>1</sup> classifies vertebral fractures based on the three-column theory and on the mechanisms of trauma. Using radiographs and computerized tomography, the author describes three osteoligamentous structures: the anterior column (anterior part of the vertebral body, anterior part of the fibrous ring and the anterior longitudinal ligament), the middle column (posterior longitudinal ligament, posterior half of the vertebral body and in

the posterior part of the fibrous ring) and the posterior column (posterior osseous arch next to the supraspinal, infraspinal, yellow ligaments and articular capsules). The mechanisms of trauma identified in this classification are: compression, burst, seat-belt and fracture-dislocation.<sup>1,9</sup>

Burst fractures are characterized by the impairment of the middle column, with displacement or rotation of the posterior cortex of the vertebral body.<sup>1</sup> Characteristically, the appearance in the computerized axial tomography illustrates the bone fragment producing traumatic stenosis of the spinal canal.<sup>8,9</sup> In 1994, Magerl et al.<sup>10</sup> introduced a more comprehensive pathomorphological classification using a progressive alphanumeric scale of anatomical damage, related to fracture severity and instability.<sup>3,11,12</sup> According to this classification, the burst fracture is of the pure axial compression type (A3), not presenting, initially, distractive lesion of the posterior elements (type B).<sup>7,10,12,13</sup> However, it is verified that many fractures classified as a thoracolumbar burst fracture (Denis) by the tomographic and radiographic criterion present posterior impairment,

All the authors declare that there is no potential conflict of interest referring to this article.

Department of Orthopedics and Traumatology of Faculdade de Ciências Médicas da Santa Casa de São Paulo – FCMSCSP – São Paulo, SP, Brazil.

Study conducted in the Spine Surgery Group of Faculdade de Medicina da Santa Casa de São Paulo. Pavilhão Fernandinho Simonsen. Serviço do Prof. Dr. Osmar Avanzi. Mailing address: Robert Meves. Rua Alameda Casa Branca, 438. Apto 61 - 01408000 - São Paulo, SP, Brazil. Email: [robertmeves@hotmail.com](mailto:robertmeves@hotmail.com)

Article received on 8/18/2011 and approved on 5/3/2011.

represented by the rupture of the posterior capsuloligamentous complex. These fractures are classified as Magerl apud Rezende type B1.2.<sup>14</sup>

The objective of this study is to verify in the group of patients with thoracolumbar burst fracture (according to Denis) the incidence of Magerl's type A and B fractures according to radiographic criteria applied by three independent examiners.

### CASUISTRY AND METHODS

Radiographs and CT scans were collected from the patients hospitalized from 2000 to 2009 with thoracolumbar burst fracture according to the criteria of Denis<sup>1</sup> at the Medical Archive and Statistics Service (SAME) after approval by the Institutional Research Bureau.

We excluded the cases without complete documentation (absence of medical records, radiographs or of CAT scan), fracture over 10 days of evolution, vertebral fractures with more than one level and those caused by wounds inflicted by firearms. There was an assessment of 72 anterior-posterior radiographs, of which 47 were of male and 25 of female patients. The patients' average age at the time of the fracture was 38.9 years (12-76 years). The most common fracture level was L1 in 24 cases, followed by L2 in 17 cases, T12 in 14, L3 in 9 and L4 in 8. In 39 patients the examiners opted for conservative treatment and 33 patients underwent surgical treatment. Five patients presented initial neurological dysfunction. The data were handled by the SPSS (Statistical Package) program in Version 1.3 for Windows. The interspinous distance was measured using a transparent ruler marked in millimeters in the anterior-posterior radiograph in the supine position by three independent orthopedists. (Figure 1) We used the mean split of the adjacent levels as a normal value of reference. We categorized the fracture as a Magerl's type B when the split was 20% or higher.<sup>14</sup>

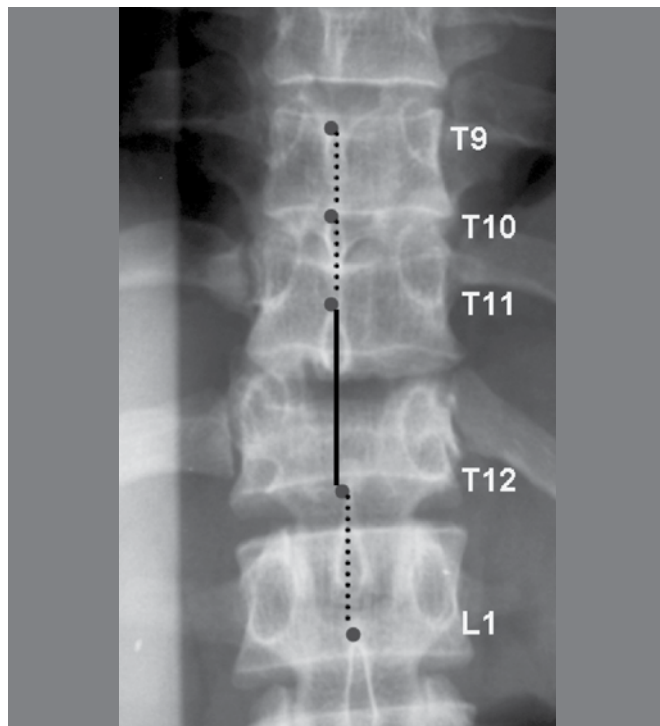
To analyze the results, we described the variables in a descriptive manner and according to the findings obtained by Kappa's method between independent examiners. (Chart 1) Kappa's method uses one examiner of reference to analyze the concordance of the results obtained by the other observers.

### RESULTS

We verified that the first examiner categorized 11 type B1.2 fractures; the second, 10; and the third, 17. Note that there was a predominance of type A fractures and the concordance of the categories (A and B) was not perfect (Table 1). For this reason, the presence of split ranged from 14 to 24% according to the examiners who analyzed the sample.

To evaluate the concordance between the measurements of the three observers we formed two groups. The first was composed of the individuals with splitting of the interspinous space (Figure 1) and the second of individuals without splitting of the interspinous space. We evaluated the relation between the observers' measurements. The concordance of the findings obtained among the examiners was good for the patients with and without spinous process splits. (Table 2)

Note that the Kappa value was higher for the patients with splitting due to the lower variability of the findings among the examiners in the patients with splitting than in the patients without interspinous splits.



**Figure 1.** Measurement of the interspinous distance. Observe the interspinous split on the continuous line between T11 and T12. Radiograph representing patient classified with B1.2 fracture.

Source: Caffaro MFS, Avanzi O. Is there a difference between narrowing of the spinal canal and neurological deficits comparing Denis and Magerl classifications? Spinal Cord 2011;49:297-301.

**Chart 1.** Kappa Interclass Coefficient Scale.

Kappa	Interpretation
<0	No association
0-0.19	Poor
0.20-0.39	Low
0.40-0.59	Moderate
0.60-0.79	Good
0.80-1	Excellent

Landis JR, Koch GG. The measurement of observer agreement for categorical data. Biometrics 1977; 33: 159-174.

**Table 1.** Distribution of patients according to Magerl's Classification.

Examiner	Fracture A	Fracture B1.2	Total
1	61 (85%)	11 (15%)	72 (100%)
2	62 (86%)	10 (14%)	72 (100%)
3	55 (76%)	17 (24%)	72 (100%)

Source: SAME.

**Table 2.** Evaluation of concordance using the Kappa method.

Magerl	Kappa
B	0.7
A	0.6

Source: SAME.

## DISCUSSION

The thoracolumbar burst fracture according to Denis presents in the computerized axial tomography comminution of the vertebral body and narrowing of the spinal canal caused by the fragment projected into the inside of the canal.<sup>1</sup> The possibility of posterior lesion can be ascertained in the trauma room by the orthopedic generalist by measuring the interspinous distance in the anterior-posterior radiograph. The radiographic determination of this split is generally accomplished subjectively by the orthopedist assisting the patient. Rezende,<sup>14</sup> in 2009, defined the split value of 20% to divide patients with Magerl's type A or B fracture in a more objective manner in this group of patients. The presence of capsuloligamentous impairment in these fractures (B1.2) is a criterion of instability and indication for surgical treatment according to some authors.<sup>11-17</sup> The matter of the importance of differentiating between A and B types in thoracolumbar burst fractures according to Denis was confirmed and discussed by Caffaro and Avanzi.<sup>8</sup>

Some limitations of this study should be mentioned. The ideal method for ascertaining posterior capsuloligamentous lesion is the finding during the surgical procedure. There is a lack of studies proving the relation between the value of the radiographic split and the anatomical impairment of the posterior structures. Moreover, magnetic resonance is the most sensitive and specific diagnostic study for ascertaining the suspicion of posterior ligamentous lesion. However, most studies infer

Margerl's classification based on pathomorphological data from the radiography and tomography. In practice few centers have routine resonance imaging available for treatment planning and for clinical research. Nonsurgical treatment is an option in neurologically intact patients, thus the gold standard information (found during surgery) on capsuloligamentous impairment is not described in the vast majority of studies. This type of analysis is not ethical in patients without surgical indication.<sup>14</sup> Future studies should be conducted to ascertain whether there is an interspinous split cutoff value that indicates this lesion, using the intraoperative finding of posterior capsuloligamentous tear as gold standard. However, our study indicates that the analysis of radiographs helps the orthopedist to suspect flexion-distraction injuries, providing a more objective and concordant evaluation parameter to categorize patients with suspected posterior distraction component (B1.2).<sup>3,9-11,13,14</sup>

## CONCLUSION

In the group of patients with thoracolumbar burst fracture according to the criteria of Denis, we verified 14 to 24% of Magerl's type B1.2 fractures. In spite of this variation, there was good concordance in the findings between independent examiners.

## ACKNOWLEDGMENTS

We are grateful for the research grant provided by FAPESP for the performance of this survey. (Project 09/52867-2).

## REFERÊNCIAS

1. Denis F. The three column spine and its significance in the classification of acute thoracolumbar spinal injuries. *Spine (Phila Pa 1976)*. 1983;8(8):817-31.
2. Vander Have KL, Caird MS, Gross S, Farley FA, Graziano GA, Stauff M, et al. Burst fractures of the thoracic and lumbar spine in children and adolescents. *J Pediatr Orthop*. 2009;29(7):713-9.
3. Knight RQ, Stornelli DP, Chan DP, Devanny JR, Jackson KV. Comparison of operative versus nonoperative treatment of lumbar burst fractures. *Clin Orthop Relat Res*. 1993;(293):112-21.
4. Heggeness MH, Doherty BJ. The trabecular anatomy of thoracolumbar vertebrae: implications for burst fractures. *J Anat*. 1997;191 ( Pt 2):309-12.
5. Riggins RS, Kraus JF. The risk of neurologic damage with fractures of the vertebrae. *J Trauma*. 1977;17(2):126-33.
6. Qureshi MA, Khalique AB, Pasha IF, Asad A, Malik AS, Shah MQ et al. Epidemiology of non-disaster spinal injuries at a spine unit. *J Coll Physicians Surg Pak*. 2010;20(10):667-70.
7. Meves R, Avanzi O. Correlation among canal compromise, neurologic deficit, and injury severity in thoracolumbar burst fractures. *Spine (Phila Pa 1976)*. 2006;31(18):2137-41.
8. Caffaro MF, Avanzi O. Is there a difference between narrowing of the spinal canal and neurological deficits comparing Denis and Magerl classifications? *Spinal Cord*. 2011;49(2):297-301.
9. Saifuddin A, Noordeen H, Taylor BA, Bayley I. The role of imaging in the diagnosis and management of thoracolumbar burst fractures: current concepts and a review of the literature. *Skeletal Radiol*. 1996;25(7):603-13.
10. Magerl F, Aebi M, Gertzbein SD, Harms J, Nazarian S. A comprehensive classification of thoracic and lumbar injuries. *Eur Spine J*. 1994;3(4):184-201.
11. Gertzbein SD. Spine update. Classification of thoracic and lumbar fractures. *Spine (Phila Pa 1976)*. 1994;19(5):626-8.
12. Anderson PA, Henley MB, Rivara FP, Maier RV. Flexion distraction and chance injuries to the thoracolumbar spine. *J Orthop Trauma*. 1991;5(2):153-60.
13. Leibl T, Funke M, Dresing K, Grabbe E. [Instability of spinal fractures--therapeutic relevance of different classifications]. *Rofo*. 1999;170(2):174-80.
14. Rezende R. Avaliação da Correlação entre a gravidade do trauma e a classificação de Magerl para as fraturas vertebrais toracolombares [tese]. São Paulo: Faculdade de Ciências Médicas da Santa Casa de São Paulo; 2009.
15. Kim NH, Lee HM, Chun IM. Neurologic injury and recovery in patients with burst fracture of the thoracolumbar spine. *Spine (Phila Pa 1976)*. 1999;24(3):290-3.
16. Khattak MJ, Syed S, Lakdawala RH. Operative management of unstable thoracolumbar burst fractures. *J Coll Physicians Surg Pak*. 2010;20(5):347-9.
17. Alpantaki K, Bano A, Pasku D, Mavrogenis AF, Papagelopoulos PJ, Sapkas GS et al. Thoracolumbar burst fractures: a systematic review of management. *Orthopedics*. 2010;33(6):422-9.