

# HALLUX VALGUS ANATOMICAL ALTERATIONS AND ITS CORRELATION WITH THE RADIOGRAPHIC FINDINGS

## ALTERAÇÕES ANATÔMICAS ENCONTRADAS NO HÁLUX VALGO E SUA CORRELAÇÃO COM OS ACHADOS RADIOGRÁFICOS

CRISTINA SCHMITT CAVALHEIRO<sup>1</sup> , MARCEL HENRIQUE ARCURI<sup>1</sup> , VÍCTOR REIS GUIL<sup>1</sup> , JULIO CESAR GALI<sup>2</sup> 

1. Pontifícia Universidade Católica de São Paulo, School of Medical Sciences and Health, Graduate Training Program in Orthopedics and Traumatology, Sorocaba, SP, Brazil.  
2. Pontifícia Universidade Católica de São Paulo, School of Medical Sciences and Health, Department of Surgery, Sorocaba, SP, Brazil.

### ABSTRACT

**Objective:** To describe the anatomical and pathological osteoarticular, muscular and tendinous variations in feet of cadavers with hallux valgus and to correlate them with the degree of radiographic deformity. **Methods:** Dissections and radiographs were conducted in the feet of 22 cadavers with hallux valgus, aged between 20 and 70 years. The feet affected were compared with 5 normal feet in order to document the anatomical and pathological, myotendinous and articular variations found. **Results:** The extensor hallucis longus and brevis tendons were arched in all degrees of deformity, causing a lateral deviation that forms the arc chord of the metatarsophalangeal angle of the hallux. We also observed a deviation to the plantar face of the abductor muscle tendon and lateral deviation of the flexor hallucis muscle tendon. In the moderate deformities, the medial deviation of the first metatarsal head was observed, sliding out of the sesamoid apparatus, pronation of this head, and formation of medial exostoses. In severe deformities, in addition to all other deformities, we found the extensor hallucis longus tendon with two distal insertions, rather than just one. **Conclusion:** The anatomical alterations found in the hallux valgus may be related to the degree of radiographic deformity. **Level of Evidence IV, Case series.**

**Keywords:** Anatomy. Hallux Valgus. Foot. Radiology.

### RESUMO

**Objetivo:** Descrever as variações anatômicas e patológicas osteoarticulares, musculares e tendíneas em pés de cadáveres portadores de hálux valgo e correlacionar com o grau de deformidade radiográfica. **Métodos:** Foram feitas dissecações e radiografias de 22 peças de pés de cadáveres portadores de hálux valgo, com idade entre 20 e 70 anos, que foram comparadas com 5 pés normais, no intuito de documentar as variações anatômicas e patológicas ósseas, miotendíneas e articulares encontradas. **Resultados:** Em todos os graus de deformidade encontramos um arqueamento dos tendões extensores longo e curto do hálux, causando um desvio lateral que forma a corda de arco do ângulo metatarsofalângico do hálux. Observamos, também, um desvio para a face plantar do tendão do músculo abductor do hálux e desvio lateral do tendão do músculo flexor do hálux. Nas deformidades moderadas foi verificado o desvio medial da cabeça do primeiro metatarso, deslizando para fora do aparelho sesamoide, pronação dessa cabeça e formação de exostoses mediais. Nas deformidades severas, além de todas as outras deformidades, encontramos o tendão extensor longo do hálux com duas inserções distais, ao invés de apenas uma. **Conclusão:** As alterações anatômicas encontradas no hálux valgo podem estar relacionadas com o grau de deformidade radiográfica. **Nível de Evidência IV, Série de Casos.**

**Descritores:** Anatomia. Hálux Valgo. Pé. Radiologia.

**Citation:** Cavalheiro CS, Arcuri MH, Guil VR, Gali JC. Hallux valgus anatomical alterations and its correlation with the radiographic findings. *Acta Ortop Bras.* [online]. 2020;28(1):12-5. Available from URL: <http://www.scielo.br/aob>.

### INTRODUCTION

The term *hallux abducto valgus* was introduced by the German surgeon Carl Heuter in 1871, who described the deformity as a lateral deviation of the hallux and its consequent distancing from the median axis of the body.<sup>1,2</sup> *Hallux* is a Latin term meaning “the largest toe” and *valgus* corresponds to the position it takes in relation to the longitudinal axis of the body, i.e. away from this axis. The hallux valgus deformity presents a familial tendency, especially in juvenile forms, which are more dependent on intrinsic factors,

and it is transmitted by autosomal dominant inheritance with incomplete penetrance.<sup>2</sup>

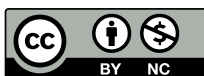The incidence of this pathology is higher in females, at a ratio of 2:1 when studying infant populations, but when assessing adult populations, this proportion changes significantly and may reach 15:1. These findings suggest that the frequency increases due to the use of shoes whose characteristics facilitate and stimulate deformity in females.<sup>2</sup>

Hallux valgus is a complex condition with a range of deformities that vary in severity, suggesting that several factors are responsible.

All authors declare no potential conflict of interest related to this article.

Article developed in the School of Medical Sciences and Health, Pontifícia Universidade Católica de São Paulo, Sorocaba, SP, Brazil.  
Correspondence: Cristina Schmitt Cavalheiro. Rua Caracas, 418, Sorocaba, SP, Brazil. 18046-718. [cristinaschmitt1@gmail.com](mailto:cristinaschmitt1@gmail.com)

Article received on 08/01/2019, approved on 08/08/2019.



Inheritance and sex are relevant, but other anatomical and biomechanical factors, such as metatarsal anatomical variants, including a long first metatarsal, a rounded joint, and metatarsus primus varus, play an important role in the evolution of the disease. These variants increase vulnerability to hypermobility of the first ray, flat foot, and ligament laxity.<sup>3</sup>

Hallux valgus does not necessarily occur in serial stages but may occur in parallel.<sup>4</sup> The medial support structures of the first metatarsophalangeal joint are the medial sesamoid and the medial collateral ligaments; when these structures fail, the so-called “initial and essential injury” occurs. The first metatarsal head can deviate medially by sliding out of the sesamoid apparatus, and an oblique or unstable joint of the tarsometatarsal joint may favor this movement.<sup>5,6</sup> The proximal phalanx moves in the valgus direction, while its base is fixed to the sesamoid, deep transverse ligament and adductor hallucis tendon. Then the extensor and flexor hallucis longus tendons arch laterally increasing the valgus displacement.<sup>7,8</sup>

As the first metatarsal head slides from the sesamoid apparatus, its pronation occurs for the muscle forces acting on it. Typically, the abductor hallucis tendon strongly resists proximal phalanx valgus, but it becomes dysfunctional as its medial and plantar insertions rotate less efficiently.<sup>3,9</sup> As the adductor hallucis tendon is inserted into the plantar surface laterally, it tends to pull the phalanx in pronation, dislocating the phalanx base. The weakened capsule of the metatarsophalangeal joint is not reinforced by any tendon, so it rotates medially with pronation, providing significant instability.<sup>10</sup> The elevation of the metatarsal head with medial movement may transfer plantar pressure to the lateral.<sup>3,11</sup> Therefore, hallux valgus is essentially a subluxation of the two great toe phalanges in the valgus sense.

According to Dykyj<sup>12</sup>, this pathology is associated with the deviation of bones from their axial position and the related destabilization of the muscle group around the joint, specifically: the hallux deviates and rotates laterally, while the first metatarsal deviates medially and also rotates laterally to some degree; deviation of the two main segments of the joint causes rupture and weakening of the medial capsular fibers and pull the sesamoid bones and metatarsal head away from their normal plantar joint; abnormal articulation of the sesamoid bones under the crest and pressure of the medial capsular wall causes erosion of both cartilage and subchondral bone in the metatarsal head; the deviation of the hallux redistributes the insertions of the tendons in relation to the articular axes of the movement, aggravating the deviation; the deviated position of the hallux and the eccentric actions of the tendons create a reaction force in the first metatarsal head, dislocating medially the first metatarsal bone.

The deformity of the first ray associated with hallux valgus is actually a triple deformity with axial, sagittal and coronal components.<sup>13</sup> Several angular parameters such as hallux valgus angles, intermetatarsal angle (between the first and second metatarsals), interphalangeal valgus angle, tarsometatarsal joint angle, degree of sesamoid subluxation, and relative length of metatarsals have been used to determine in both preoperative period (moment of surgical indication) and postoperative period (moment of results evaluation) the appropriate technique, intensity of the deformity, and intended and obtained correction.<sup>14-17</sup> We did not find studies correlating the degree of radiographic deformity with the anatomical changes found. The aim of this study was to describe the osteoarticular, muscular and tendon anatomical and pathological variations in feet of cadavers with hallux valgus and to correlate them with the degree of radiographic deformity, to create a scientific approach to assist the decision of the appropriate treatment for each patient.

## MATERIALS AND METHODS

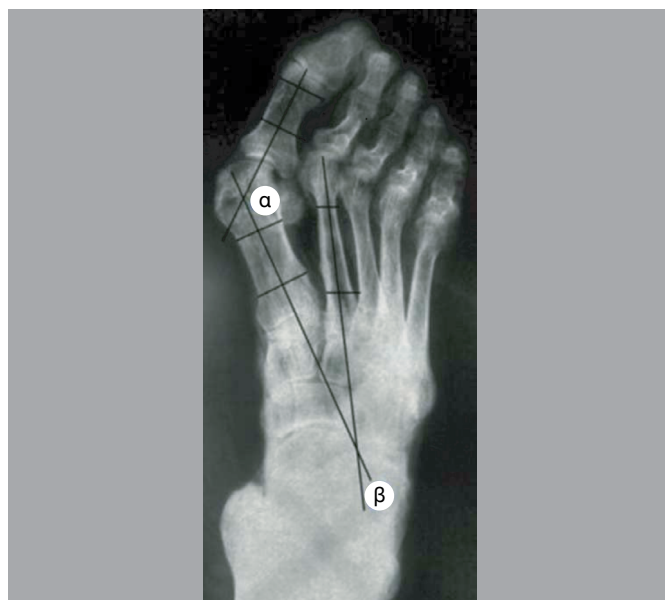
The study was approved by the Research Ethics Committee of our Institution (02282718.7.0000.5373). Dissections were performed on 22 feet of cadavers with hallux valgus, aged between 20 and

70 years (mean age 45 years), 18 of them were female (81.8%) and 4 were male (18.1%), to document the anatomical and pathological, myotendinous and articular variations; five feet without changes were dissected for comparative purposes. Radiographs were obtained in the anteroposterior view of these cadavers. Inclusion criteria for hallux valgus feet were intermetatarsal radiographic angles higher than 15° and hallux valgus higher than 9°. The feet were considered without deformities when the hallux valgus angle was lower than 15° and the intermetatarsal angle was lower than 9°.

The dissections assessed the intrinsic and extrinsic muscles of the foot, also observing its tendon insertions. The procedure was started with a first radius dorsal incision to assess the insertion of the tendon of the extensor hallucis longus muscle, and dissection of deep planes, with resection of all adjacent tissue. The same process was used with the tendon of the extensor hallucis brevis muscle. A medial incision was carried out to assess the insertion of the tendon of the abductor hallucis muscle and the tendon of the tibialis anterior muscle. Finally, a plantar incision was executed for direct visualization of the tendons of the adductor, flexor hallucis longus and brevis muscles. Thus, the osteoarticular assessment process started with the soft tissues following denudation procedures. After dissections, the pieces were treated with 2.5% formaldehyde and, subsequently, the samples were glycerinated for fixation and better photographic record. The radiographic study followed the technical standardization described in previous studies.<sup>10,18</sup>

The angles were assessed on the printed radiographs of the feet using a goniometer. The angles were measured between the first and second metatarsals — formed by the intersection of the longitudinal axes of the diaphyses of these two bones — and hallux valgus angle — formed by the intersection of the longitudinal axes of the first metatarsal diaphysis and the proximal phalanx diaphysis<sup>2,11,19</sup>. (Figure 1)

Radiographic hallux valgus was classified according to Mann and Coughlin<sup>20</sup> standards: mild deformities were those with hallux valgus angle between 15 and 20° and intermetatarsal angle between 9 and 11°; deformities with hallux valgus angle between 21° and 40° and intermetatarsal angle between 11° and 16° were classified as moderate. The severe deformities were those with hallux valgus angle higher than 40° and intermetatarsal angle higher than 16°.



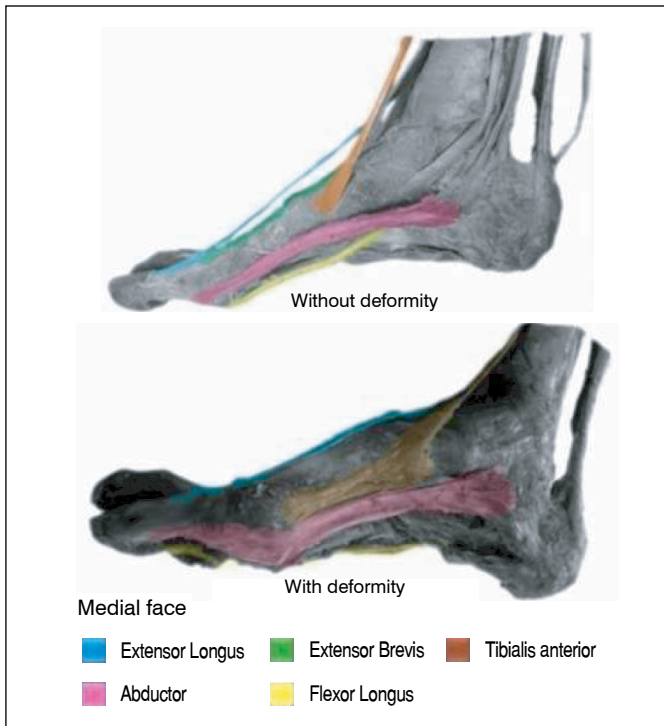
**Figure 1.** Anteroposterior radiograph of a deformed foot, showing the lines drawn for angle measurements.  $\alpha$  = hallux valgus angle and  $\beta$  = intermetatarsal angle.

## RESULTS

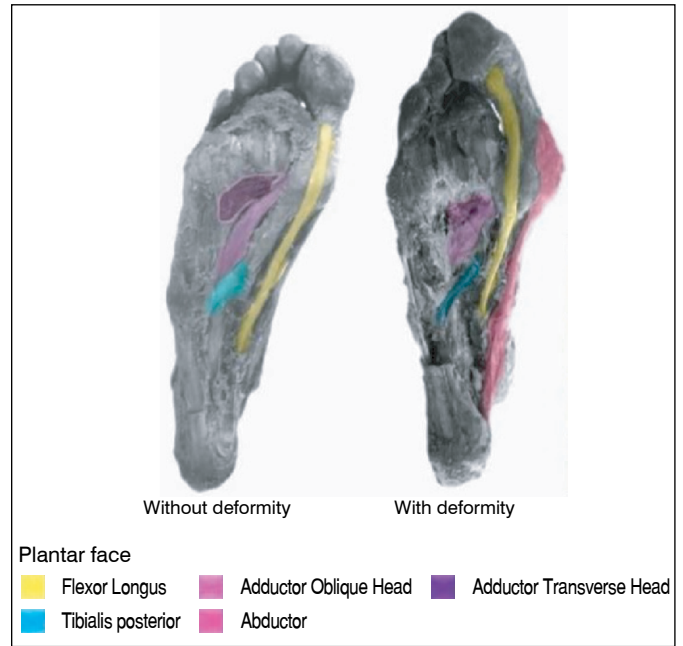
According to the classification of radiographs by Mann and Coughlin<sup>20</sup>, nine feet presented mild deformity (40.9%), seven feet had moderate deformities (31.8%) and six feet presented severe deformities (27.2%). In all degrees of deformity, an arch of the extensor hallucis longus and brevis tendons were found, causing a lateral deviation that formed the curvature of the hallux phalangeal metatarsal angle. We also observed a deviation to the plantar face of the tendon of the abductor hallucis muscle (Figure 2) and lateral deviation of the tendon of the flexor hallucis muscle (Figure 3). Regarding the moderate deformities, in addition to what has been described for mild deformities, the first metatarsal head was found medially deviated, sliding out of the sesamoid apparatus, pronation of this metatarsal head, and formation of medial exostoses (Figure 4). In severe deformities, added to the changes shown in mild and moderate deformities, the extensor hallucis longus tendon was found with two distal insertions instead of one (Figure 5). In the radiographic assessment, the mean value for the measurements of intermetatarsal angles was 27.3° (ranging between 17 and 53°) and for the hallux valgus was 18.6 (ranging between 9 and 26°). We verified exostoses formations and sesamoid complex deviation in moderate and severe deformities, as well as increased intermetatarsal angle — in all degrees of deformity.

## DISCUSSION

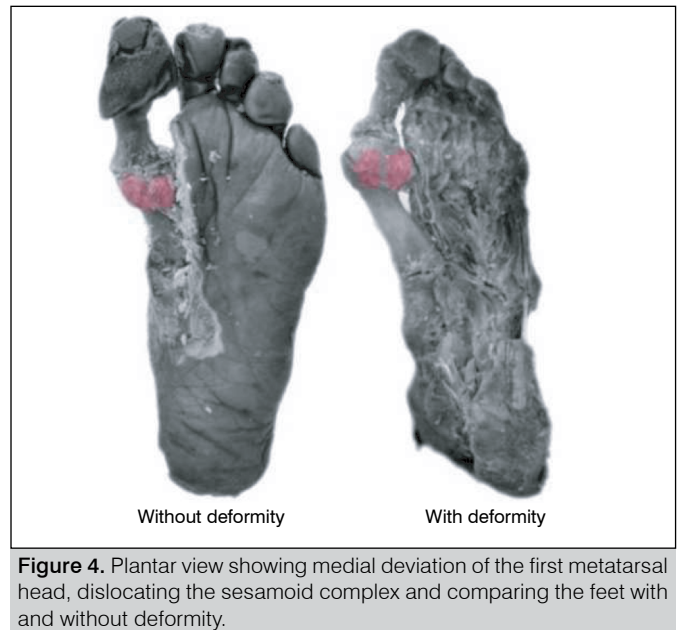
The main result of our study was to verify that the anatomical and pathological bone variations present in hallux valgus may be related to the degree of radiographic deformity. Henning<sup>4</sup> suggests hallux valgus deformities may occur sequentially and simultaneously. In fact, our study showed that the common denominator in all degrees of radiographic deformity was an arch of the extensor hallucis longus and brevis tendons, a deviation to the plantar face of the abductor hallucis tendon, and lateral deviation of the flexor hallucis tendon.



**Figure 2.** Medial view of the dissection, showing plantar deviation of the abductor hallucis muscle and the comparison between the feet with and without deformity.



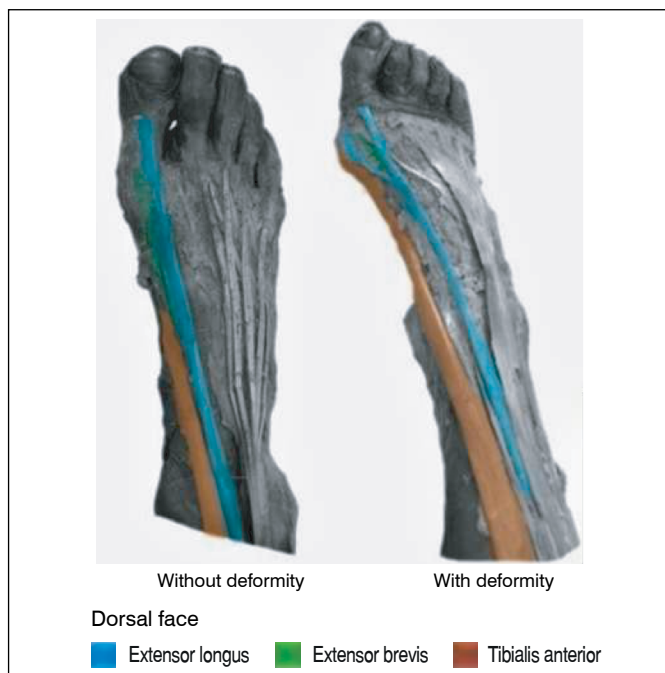
**Figure 3.** Plantar view of the dissection, showing the plantar deviation of the abductor hallucis muscle, hypotrophy of the oblique and transverse head of the adductor hallucis muscle, medial deviation of the flexor hallucis longus muscle and the comparison between the feet with and without deformity.



**Figure 4.** Plantar view showing medial deviation of the first metatarsal head, dislocating the sesamoid complex and comparing the feet with and without deformity.

The moderate deformities characteristic were presented as the medial deviation of the first metatarsal head, located outside the sesamoid apparatus, pronation of the head, and the presence of medial exostoses (Figure 3). The severe deformities were characterized by the presence of two distal insertions of the extensor hallucis longus tendon (Figure 4). The literature does not show studies corroborating the anatomical changes presented in hallux valgus with the degree of radiographic deformity.

Aseyo and Nathan<sup>21</sup> assessed 200 hallux: 100 of those hallux by dissections and 100 radiographs of hallux valgus patients. In 40 hallux of cadavers and in 100 patients with this deformity, the sesamoids were displaced laterally in varying degrees.



**Figure 5.** Dorsal view of the dissection, showing double proximal insertion of the tendon of the extensor hallucis longus muscle, insertion of the tibialis anterior tendon, and comparison between the feet with and without deformity.

Kim<sup>22</sup> dissected 15 feet with hallux valgus to assess changes in tendon insertions in the proximal and distal phalanges of the first toe. The 15 cadavers presented the following alterations: deviation of the tendon of the abductor hallucis muscle to the plantar face, lateral displacement of the tendons of the adductor muscles and flexor brevis hallucis. Kim verified that the rotation angle of the proximal phalanx varied according to the degree of the pathology severity and that the tendon of the extensor hallucis longus muscle and the tendon of the flexor hallucis longus muscle were laterally deviated.

Therefore, to establish a relationship between the degree of radiographically deformity measured and the morphological changes may be a fundamental tool for the planning of hallux valgus treatment, including possible surgical interventions. Based on the knowledge of the anatomical changes that occur in the different degrees of radiographic deformity, the surgical planning can be more effective.

Our study has some limitations. Our sample of 22 feet with hallux valgus may be considered small, although larger than Kim's<sup>22</sup> sample. Furthermore, the radiographs of the cadavers' feet were obtained without load, as recommended in the assessment of this pathology. On the other hand, the anatomical parts were already rigid, which would possibly not be influenced by the load in the production of radiographic images.

## CONCLUSIONS

Anatomical changes found in hallux valgus may be related to the degree of radiographic deformity.

**AUTHORS' CONTRIBUTIONS:** Each author contributed individually and significantly to the development of this article. JCG, VRG (0000-0001-5648-1921)\* and MHA: bibliographic survey and aid in anatomical dissections; CSC: analysis of the results and writing of the article; MHA: writing of the article and photographic documentation. VRG: aid in anatomical dissections and photographic documentation; JCG and CSC: were present in all dissections, writing and review of the article, results analysis, intellectual concept of the article and preparation of the entire research project.

## REFERENCES

- Ferrari J, Malone-Lee J. A radiographic study of the relationship between metatarsus adductus and hallux valgus. *J Foot Ankle Surg.* 2003;42(1):9-14. <https://doi.org/10.1053/jfas.2003.50006>
- Nery CA. Hálux valgo. *Rev Bras Ortop.* 2001;36(6):183-200.
- Perera AM, Mason L, Stephens MM. The pathogenesis of hallux valgus. *J Bone Joint Surg Am.* 2011;93(17):1650-61. <https://doi.org/10.2106/JBJS.H.01630>
- Henning EE. Hallux valgus e aprimoramento de técnica cirúrgica reparadora [tese]. Porto Alegre: Faculdade de Medicina, Universidade Federal do Rio Grande do Sul; 1974.
- Thomas S, Barrington R. Hallux valgus. *Curr Orthop.* 2003;17(4):299-307. [https://doi.org/10.1016/S0268-0890\(02\)00184-6](https://doi.org/10.1016/S0268-0890(02)00184-6)
- Nery C, Ballerini FJ, Kobata SI. Hálux valgo em homens – parte II: avaliação do tratamento cirúrgico. *Rev ABTPé.* 2009;3(2):81-8.
- Nery CAS, Apostólico Netto A, Benevento M, Réssio C. Avaliação radiográfica do hálux valgo: estudo populacional de novos parâmetros angulares. *Acta Ortop Bras.* 2011;9(2):41-8. <http://dx.doi.org/10.1590/S1413-78522001000200005>
- Coughlin MJ, Shurnas PS. Hallux valgus in menpart II: first ray mobility after bunionectomy and factors associated with hallux valgus deformity. *Foot Ankle Int.* 2003;24(1):73-8. <http://dx.doi.org/10.1177/107110070302400112>
- Menz HB, Fotoohabadi MR, Wee E, Spink MJ. Validity of self-assessment of hallux valgus using the Manchester scale. *BMC Musculoskelet Disord.* 2010;11:215. <http://dx.doi.org/10.1186/1471-2474-11-215>
- Ignácio H, Chueire AG, Carvalho Filho G, Nascimento LV, Vasconcelos UMR, Barão GTF. Estudo retrospectivo da osteotomia de base do primeiro metatarso com tratamento do hálux valgo. *Acta Ortop Bras.* 2006;14(1):48-52. <http://dx.doi.org/10.1590/S1413-78522006000100011>
- Dayton P, Feilmeier M, Hirschi J, Kauwe M, Kauwe JSK. Observed changes in radiographic measurements of the first ray after frontal plane rotation of the first metatarsal in a cadaveric foot model. *J Foot Ankle Surg.* 2014;53(3):274-8. <http://dx.doi.org/10.1053/jfas.2014.01.002>
- Dykyj D. Pathologic anatomy of hallux abducto valgus. *Clin Podiatr Med Surg.* 1989;6(1):1-15.
- Deland JT, Sung II H. The medial crossover toe: a cadaveric dissection. *Foot Ankle Int.* 2000;21(5):375-8. <https://doi.org/10.1177/107110070002100503>
- Wülker N. [General operative technique of the foot and ankle]. *Orthopade.* 2011;40(5):378-80.
- Jastifer JR, Coughlin MJ, Schutt S, Hirose C, Kennedy M, Grebing B, et al. Comparison of radiographic and anatomic distal metatarsal articular angle in cadaver feet. *Foot Ankle Int.* 2014;35(4):389-93. <https://doi.org/10.1177/1071100714522027>
- Mays SA. Paleopathological study of hallux valgus. *Am J Phys Anthropol.* 2005;126(2):139-49. <https://doi.org/10.1002/ajpa.20114>
- Cohen BE. Hallux sesamoid disorders. *Foot Ankle Clin.* 2009;14(1):91-104. <https://doi.org/10.1016/j.fcl.2008.11.003>
- Castro AP, Rebelatto JR, Aurichio, TR. A relação do ângulo da articulação metatarsofalangeana e de medidas antropométricas com a postura dos pés de idosos. *Rev Bras Fisioter.* 2009;13(1):59-64. <http://dx.doi.org/10.1590/S1413-35552009005000004>
- Natsis K, Konstantinidis GA, Symeonidis PD, Totlis T, Anastasopoulos N, Stavrou P. The accessory tendon of extensor hallucis longus muscle and its correlation to hallux valgus deformity: a cadaveric study. *Surg Radiol Anat.* 2017;39(12):1343-7. <http://dx.doi.org/10.1007/s00276-017-1881-4>
- Mann RA, Coughlin MJ. Hallux valgus: etiology, anatomy, treatment, and surgical considerations. *Clin Orthop Relat Res.* 1981;(157):31-41.
- Aseyo D, Nathan H. Hallux sesamoid bones. Anatomical observations with special reference to osteoarthritis and hallux valgus. *Int Orthop.* 1984;8(1):67-73. <http://dx.doi.org/10.1007/bf00267743>
- Kim PW. Review of anatomical changes in the musculature of the foot as seen in the cadavers study with hallux valgus. *FASEB J.* 2016;30(1):1043-7.