

THREE-DIMENSIONAL PRINTING IN ORTHOPEDICS: WHERE WE STAND AND WHERE WE ARE HEADING

IMPRESSÃO 3D NA ORTOPEDIA: ONDE ESTAMOS E AONDE PODEMOS CHEGAR

LEANDRO EJNISMAN^{1,2} , CAMILO PARTEZANI HELITO^{3,4} , ANDRÉ FERRARI DE FRANÇA CAMARGO^{1,4,5} ,
BRUNO ARAGÃO ROCHA^{4,6,7} , ANDRÉ MATHIAS BAPTISTA¹ , OLAVO PIRES DE CAMARGO¹ 

1. Hospital das Clínicas da Faculdade de Medicina da Universidade de São Paulo, Institute of Orthopedics and Traumatology, São Paulo, SP, Brazil.

2. Hospital Israelita Albert Einstein, São Paulo, SP, Brazil.

3. Hospital das Clínicas da Faculdade de Medicina da Universidade de São Paulo, Institute of Orthopedics and Traumatology, Knee Group, São Paulo, SP, Brazil.

4. Hospital Sirio Libanês, São Paulo, SP, Brazil.

5. Hospital Santa Paula, São Paulo, SP, Brazil.

6. Hospital das Clínicas da Faculdade de Medicina da Universidade de São Paulo, Institute of Radiology, São Paulo, SP, Brazil.

7. Grupo Fleury, São Paulo, SP, Brazil.

ABSTRACT

Three-dimensional printing is a technology in expansion in the medical field. It also presents many applications in orthopedics. Our review article aims to describe 3D printing, types of 3D printers, and its use in the orthopedic field. 3D models can be created using tomography scans. Those models can then be manipulated, even simulating surgeries. It is possible to print biomodels, which will help us understand deformities and plan surgeries. Orthopedic surgeons must be updated in these disruptive technologies that may help their daily practice. **Level of Evidence V, Expert opinion.**

Keywords: Orthopedics. Printing, Three-Dimensional. Models, Anatomic.

RESUMO

A impressão 3D é uma tecnologia em expansão na medicina, possuindo diversas utilidades na ortopedia. O objetivo deste artigo de revisão é descrever o que é a impressão 3D, seus tipos e suas aplicações na ortopedia. Modelos em 3 dimensões podem ser criados a partir da tomografia computadorizada. Estes modelos podem ser manipulados em softwares específicos, onde inclusive cirurgias podem ser simuladas. Utilizando impressoras 3D podemos criar biomodelos que nos ajudam a compreender deformidades e planejar cirurgias. É importante que o ortopedista se mantenha atualizado nestas novas tecnologias disruptivas que podem auxiliar muito no seu dia a dia. **Nível de Evidência V, Opinião do especialista.**

Descritores: Ortopedia. Impressão Tridimensional. Modelos Anatômicos.

Citation: Ejnisman L, Helito CP, Camargo AFF, Rocha BA, Baptista AM, Camargo OP. Three-dimensional printing in Orthopedics: where we stand and where we are heading. Acta Ortop Bras. [online]. 2021;29(4):223-227. Available from URL: <http://www.scielo.br/aob>.

INTRODUCTION

Additive manufacturing, whose main representatives popularly known as 3D printing (3DP), is a class of technologies developed in the 1980s that has gained popularity only in the last decade with the cheapness of the machines and the technology involved in the process of creating 3-dimensional (3D) models. Three-dimensional printing has several applications in the most different industries such as jewelry, automotive, aviation and food.

In the area of health, 3DP has applications in Dentistry, reconstructive plastic surgery, Cardiology, among others. Since it involves bone structures and computed tomography (CT), Orthopedics is an expanding field for the use not only of 3DP, but also of all 3D technology.¹ For a better understanding of orthopedic deformities and surgical planning, often the use of 3D models in the computer

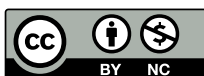(virtual environment) is enough, not requiring the impression of a physical model. Thus, the use of this technology becomes even more accessible, since most of the computer programs used for this purpose are free of charge. However, when the objective involves the treatment of complex deformities that require unconventional implants or patients with non-normal sizes, in which it is not known whether the implants available in will be suitable for treatment, the 3D printing of bone anatomy extracted from a computed tomography examination (also known as Biomodel) represents a huge performance gain.² Although we already have this technology available in our specialty, its use is not yet widespread on a large scale and many centers are not even aware of its existence and possible applicability. Thus, our article aims to show practical examples of current applications of 3DP and to discuss future perspectives of this technique in Orthopedics.

All authors declare no potential conflict of interest related to this article.

The study was conducted at the Institute of Orthopedics and Traumatology, Hospital das Clínicas, Universidade de São Paulo.

Correspondence: Leandro Ejnisman. Rua Dr. Ovídio Pires de Campos, 333, Cerqueira César, São Paulo, SP, Brazil, 05403010. leandro.ejnisman@gmail.com

Article received on 11/25/2020, approved on 03/16/2021.



3D Printing Method

The creation of a 3D printed bone model (Biomodel) begins with an imaging exam, usually a CT, which stores the data in DICOM (Digital Imaging and Communications in Medicine) format. Various software, both commercial, such as Mimics®, Syngo.via Siemens® and Carestream®, or free ones such as Horos®, Osirix®, 3D Slicer® and Invesalius® allow you to create a 3D file that can be printed from an image scan (Figure 1). This step in the process of selecting the region of interest within the exam is called “Image Segmentation.” These programs work in a similar way. CT uses the Hounsfield scale to assign a radiodensity value to each pixel of the evaluated structure and represents it in a gray graduation when we see the exam cuts.

Using tools that detect pixel intensity thresholds, the software can select the desired structure, such as a bone that stands out from the rest of the structures. Besides tools for detecting pixel thresholds, there are tools such as pixel selection by similarity, which are useful for separating one bone from another in a joint (for example, separating the tibia from the femur in one knee). Manual selection tools from the region of interest, such as in a drawing program, can also be used. By combining these tools with more complex ones, the desired structure can be limited (Figure 2) and the geometry of that region exported in a graphic file, of which the most famous is the STL (“stereolithography”). This type of graphic file represents a region in space by a mesh of triangles, so they can also be called “meshes.”

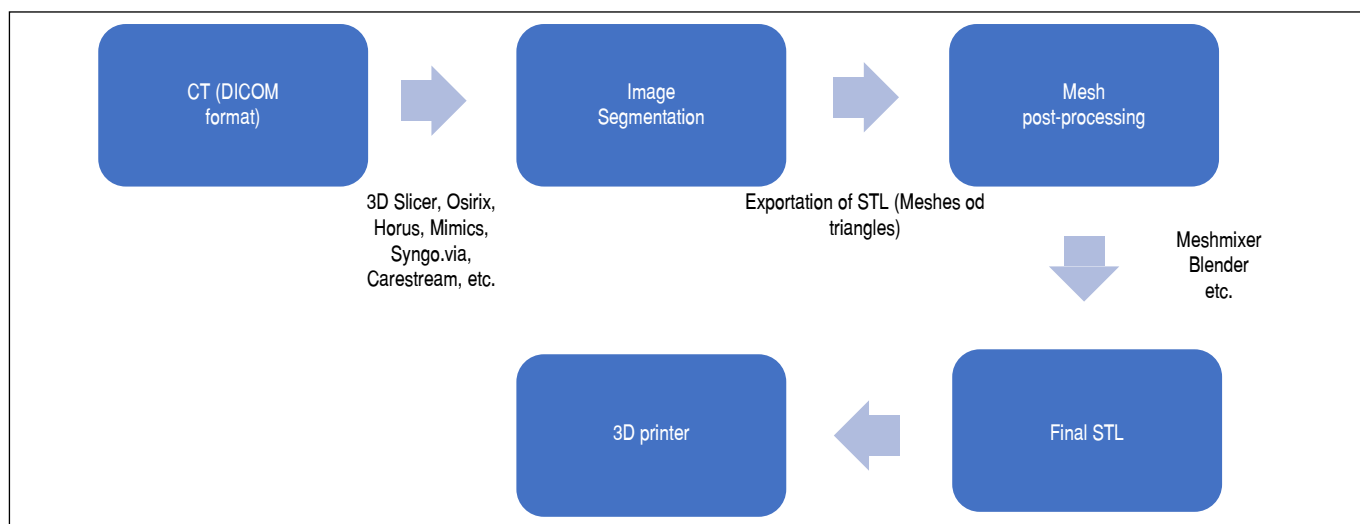


Figure 1. Schema demonstrating the steps for creating a 3D Biomodel.

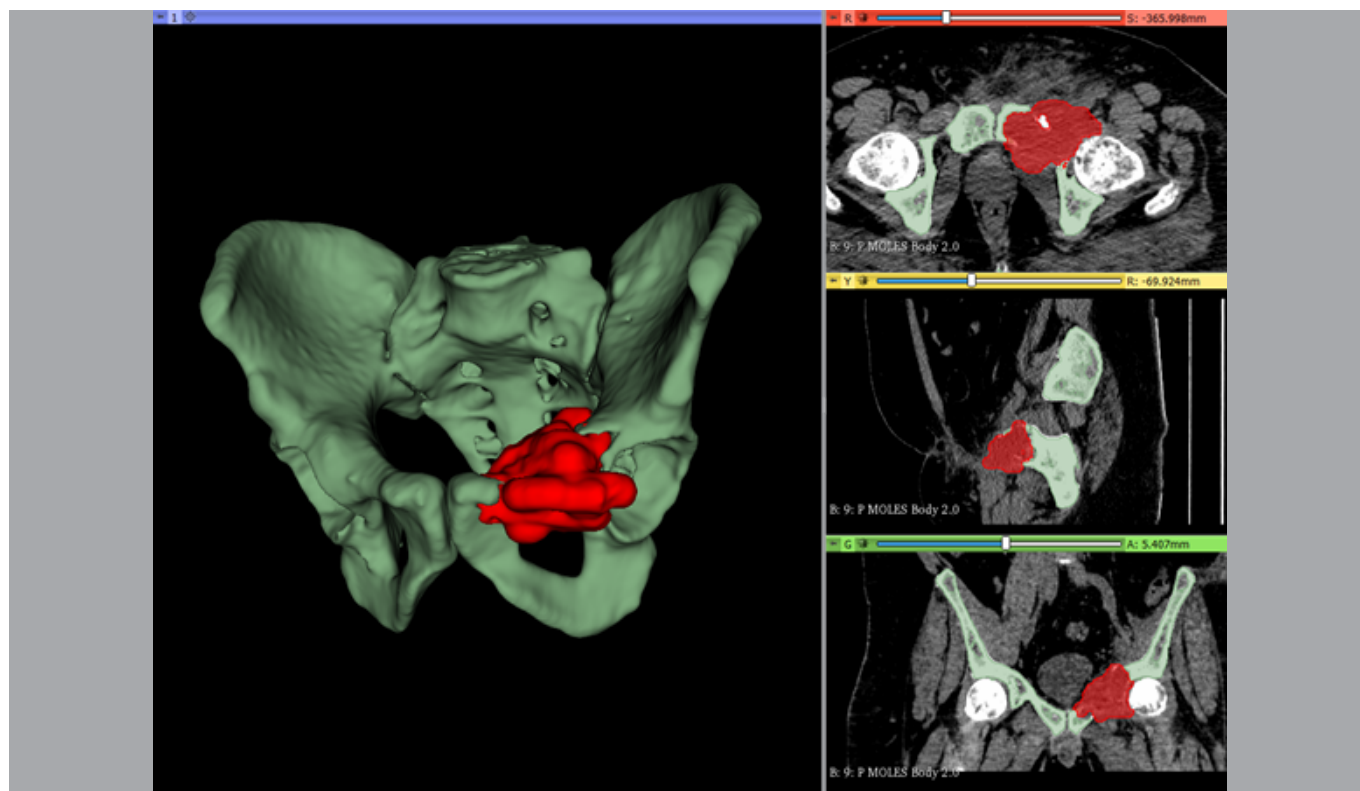


Figure 2. Example of segmentation performed in the 3D Slicer®. The patient's pelvis is selected in green, the region of interest is selected in red.

We can notice 3D reconstruction and visualization in the 3 planes (axial, sagittal and coronal).

At this time, the STL file can be directly sent to the software that controls the 3D printer; however, some other graphical manipulation software is used (several free of charge, such as Meshmixer® or Blender®), so that a post-processing is done for mesh improvements. In these programs we can erase regions that are not of interest (the ribs on a shoulder exam, for example), refine the image ("clean" artifacts), soften pixelating effect, make localized adjustments, add supports or bases, combine different STL files and even simulate corrective surgeries such as osteotomies and create custom surgical guides. After this virtual post-processing step over the generated mesh is completed, the file is again exported in STL format to be printed.

There are several types of 3D Printers, which are based on very different technologies and materials, each with advantages and disadvantages. In this article, we will mention some of the most used in orthopedic surgeries:

- FDM (fused deposition modeling) printers are the most popular printers for home use. These printers use plastic polymers that come on a roll as material in filament form. The filament is pulled by an engine to a hot extruder nozzle that melts the plastic and deposits it sequentially in layers, forming the 3D object. There are several types of materials that can be used in this type of machine in the shape of filament, such as PLA (polylactic acid), PETG (polyester type), nylon and ABS (styrene butadiene acrylonitrile). A great advantage of this type of printer are the great availability and low cost of the material, which make it a great option for printing large structures. On the other hand, its slightly coarser finish compared to other technologies and a high rate of printing failures in the cheaper models are some disadvantages.
- SLA (Stereolithography Apparatus) or DLP (digital light processing) printers print from photosensitive liquid resins. Printing occurs by a laser beam (SLA) or a light source (DLP) that is directed onto a given region, solidifying a photopolymer. The process works in layers, just like FDM. These machines that many years ago had a high cost, more recently became affordable (prices close to that of FDM) and home use. The SLA/DLP has the advantage of producing more accurate parts with greater detail. The fact that they usually have a small printing area, that the handling of resins is more complex (resins have a strong odor) and the that parts require post-processing, such as washing in isopropyl alcohol and curing, are disadvantages. In practice, we see that this type of technology has been used in the printing of surgical guides or very small parts that require great detailing.
- Electron beam melting (EBM) printers are industrial and used especially in the production of metal implants. In this process, a layer of metallic powder is subjected to a beam of electrons inside a vacuum chamber under high temperature. In each layer, the powder is deposited and the electron beam "draws" the structure in that two-dimensional cut, thus solidifying the powder only in the desired locations, layer by layer. At the end of the process, all residual powder (which has been outside the area of action of the electron beam) should be mechanically removed. This technology allows the production of orthopedic implants in titanium, with complex and customizable structures.

Orthopedic uses

Medical training

Understanding bone anatomy and disease deformities is not simple for medical students, residents, graduate students, and even our patients. Commonly, two-dimensional schematic drawings are used to teach orthopedics. However, anatomical structures are three-dimensional, often limiting the understanding of simplified drawings.

The possibility of printing the individual anatomy opens several opportunities for teaching.³ Patients could better understand their deformity when holding a model of their own skeleton in their hands, and can still compare with a model of a bone without alterations. Moreover, a resident can print a bone with complex fracture to better understand the deviations, fragmentations and bone impacts, thus being able to understand and properly classify the case.

Bockhorn et al.⁴ studied the application of 3DP in preoperative planning in hip preserving surgeries. CT of 16 patients with femoro-acetabular impingement were used to create 3D models. Resident physicians and patients considered that the printed model helped them to understand the deformity. Wang et al.,⁵ in turn, evaluated the use of a 3D model in the teaching of total hip arthroplasty in developmental dysplasia. Surgeons were randomized to a group that used traditional the teaching technique and group that used a teaching technique with 3DP model. The use of the 3DP model presented better performance in learning according to individual questionnaires. In our country, Cocco et al.⁶ showed that the use of printing helped to choose the best treatment in cases of proximal humerus fracture, being more efficient than radiography, tomography and holography.

Surgery planning

3D technology is very useful in planning surgical procedures. Based on the STL file it is possible to plan osteotomies, simulate corrections and even fixation. The orthopedist is used to planning surgeries aided by two-dimensional techniques such as transparencies and vegetable leaves for radiographs on a light panel. However, deformities and lesions are three-dimensional, which makes 3D planning more faithful to reality.

In planning, knowledge of anatomy and surgical technique is essential. Without knowledge about anatomy and the technique that will be used, the planning can be inaccurate or even unfeasible. This is one of the reasons why it is important that the orthopedist knows 3D technologies and actively participates in this process. If it is delegated to an engineer or to a physician from another specialty that does not know the surgical steps, the planning may seem appropriate on the computer, but may not be feasible due to access difficulties or the presence of soft parts that are not considered in the creation process. Patients with complex deformities or those with unconventional sizes, such as individuals with dwarfism, also benefit from preoperative planning and surgical simulation in the 3D printed model (Figure 3). In these situations, often the largest or smallest implant may not be suitable for the bone in question, making surgery with conventional implants unfeasible – without adequate preoperative planning, the surgeon could reach this conclusion only in the intraoperative period, already with the surgical route performed. In these situations, the identification of an anatomical particularity of the patient still in the planning period gives the surgeon the opportunity to develop a customized implant, specifically suitable for the case in question.

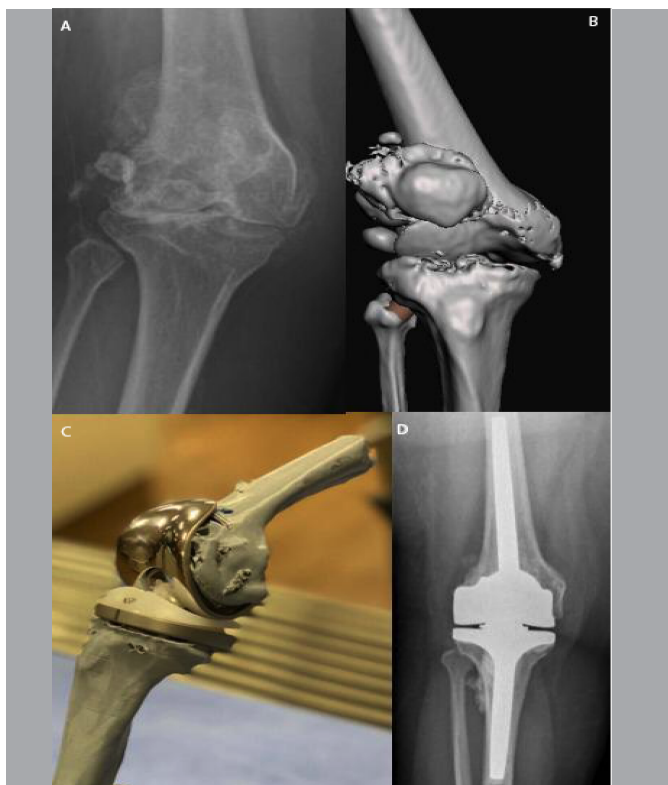

Figure 3. Example of using 3D printing for surgical planning in a patient of very short stature (1.38m). A) Anteroposterior knee radiography showing advanced osteoarthritis of the knee; B) 3D model developed from computed tomography; C) Biomodel printed from the model of Figure 2B, in which a total knee arthroplasty was performed; D) Post-operative radiography demonstrating a result similar to the biomodel.

Another interesting possibility with 3D technology is the manufacture of surgical guides, through a 3D object manipulation software (such as the aforementioned Meshmixer® or Blender®). The patient's bone anatomical repairs (such as an iliac spine, an epicondyle, a supracondylar crest, a process, or a tuberosity) are used to create a negative on the contact surface of the guide with the bone. Thus, the guide fits perfectly into the anatomical structures used as a reference – we should not plan a guide that is positioned on a flat bone surface, or without prominence, because in this case it would not be possible to ensure the exact positioning of the guide. The guide can present holes for Kirschner wires with predetermined inclinations that can give the osteotomy plane, or even channels through which it is possible to perform osteotomy with the use of oscillating saws or chisels.

Although this type of tool is still little used in clinical practice in Brazil, its use is widespread abroad. Shen et al.⁷ conducted a study on the use of preoperative 3D planning in patients with complex tibial plateau fractures. The patients (42 in total) were divided into 2 groups: conventional planning and planning using 3D printing. Surgical time, blood loss and fluoroscopy use were shorter in the group in which 3D planning was performed. Moreover, an excellent postoperative reduction was obtained in 75% of the cases of 3D planning, and in only 45% of the traditional planning, a statistically significant difference.

Custom implants

In orthopedics, we use implants already available. When performing a surgery we have access to pieces of various sizes and with some possibilities of formats. This dynamic works for the performance of

most of the procedures. However, when reconstruction of unusual anatomical regions or with large deformities is required, customization of implants can be extremely useful and is often mandatory for an adequate result.

Non-usual cases occur more frequently in arthroplasty revision surgeries, in musculoskeletal diseases associated with large joint deformities, and in cases of tumor resection. In reviews, osteolysis caused by debris presents unique characteristics in each patient. To solve this difficulty, the surgeon usually uses wedges and/or grafts to fill the bone defect as in a puzzle. The 3D technology allows the digital treatment of the model created based on CT, with the virtual removal of the previous implant, displaying in a more accurate way the existing bone defect. From this 3D model without the implant, an implant suitable for the case, respecting its unique characteristics, can be manufactured.⁸ Bone tumors also have unique characteristics, and often require non-standard resections. Most of cases the cases of resections involving long bones can be reconstructed using the modular endoprotheses available on the market. With several available combinations of meta-epifysary, articular and diaphysary parts of various sizes, long bones can be reconstructed from the femoral head to the distal third of the tibia, including an articulated knee, or from the humerus head to the elbow, without the need for customization. These locations cover most of bone tumors; however, bone tumors can also affect the distal bones to the elbow (forearm, wrist and hand), distal tibia and bones of the foot, axial skeleton and pelvic and scapular girdles (Figure 4). In these sites, the three-dimensional structure is very complex and with significant variation among patients (much larger than in long bones), and the osteotomies planned for tumor resection should follow oncological guidelines to obtain safe margins – and not to allow the subsequent placement of an existing implant. In these cases, the possibility of customization of implants suitable for planned oncological resection represents a major advance in orthopedics, because until recently the surgeon's only option was simple resection without reconstruction, often leading to a patient's large functional impairment. With the use of 3D technology, the orthopedist can now create the three-dimensional model of the affected area based on the patient's CT, virtually perform resection surgery (and creation of osteotomy guides) and, with the bone defect created, can plan and develop a most appropriated implant.

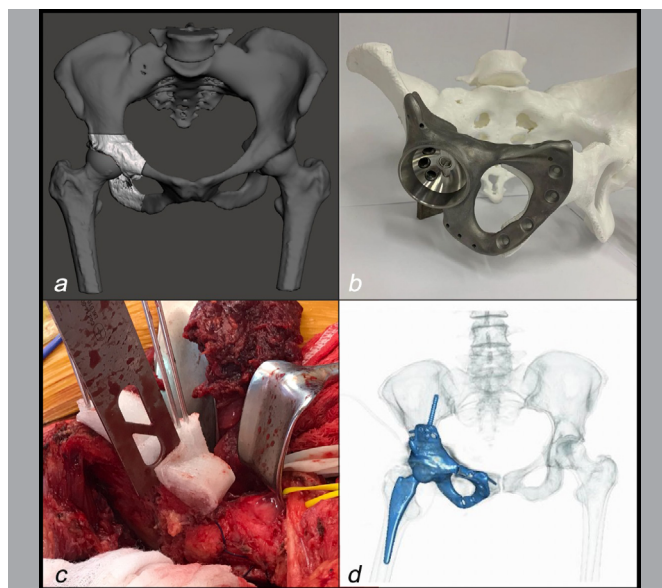


Figure 4. Stages of making a customized implant. A) Creation of a 3D model of the affected area and planning of osteotomy cuts using CAD; B) With the bone defect created virtually, the implant can be designed and a test model is printed; C) Intraoperative aspect of the guide used to perform iliac osteotomy; D) Final tomographic result.

Orthotics and prosthetics

The use of 3D technology in orthotics manufacture is growing rapidly in the past decade – by definition, devices applied externally to modify the structural and functional characteristics of the neuromuscular and skeletal system. The manufacture of orthotics and prostheses is still largely manual and therefore totally dependent on the individual.⁹ The advantages of manufacturing orthotics using 3D technology (such as spinal vests, knee orthotics, wrist, ankle-foot, insoles, etc.) include lower cost, easier modifications and adaptations, and faster manufacturing (after the design phase is finished). Patients often report greater comfort with printed prosthetic shims than traditional handmade ones.^{9,10}

Custom orthotics for foot and ankle have been made with 3D technology for over a decade with satisfactory effectiveness.¹¹ This technology

was also applied for the production of customized insoles for sports shoes,¹² for plantar fasciitis or for diabetic foot.

A recent study evaluated a 3D printed immobilizer for Colles fracture; 13 wrist radiographs were performed periodically to observe the palmar inclination angle, ulnar deviation angle and radio height. All these parameters were significantly better in the experimental group than in the control group (conventional splint).

CONCLUSION

Three-dimensional printing is becoming an extremely useful tool for orthopedics. In our article, we describe what is the 3DP, its types and the different uses of this disruptive technology that will be part of the routine of orthopedists.

AUTHORS' CONTRIBUTIONS: Each author contributed individually and significantly to the development of this article. LE: study conception, writing and critical review; CPH: study conception, writing and critical review; AFFC: study conception, writing and critical review; BAR: study conception, writing and critical review; AMB: study conception, writing and critical review; OPC: study conception, final approval of the manuscript.

REFERENCES

1. Ejnisman L, Gobbato B, Camargo AFF, Zancul E. Three-dimensional printing in orthopedics: from the basics to surgical applications. *Curr Rev Musculoskelet Med.* 2021;14(1):1-8.
2. Bagaria V, Chaudhary K. A paradigm shift in surgical planning and simulation using 3Dgraphy: Experience of first 50 surgeries done using 3D-printed bio-models. *Injury.* 2017;48(11):2501-8.
3. Chytas D, Johnson EO, Piagkou M, Tsakotos G, Babis GC, Nikolaiou VS, et al. Three-dimensional printing in anatomy teaching: current evidence. *Surg Radiol Anat.* 2020;42(7):835-41.
4. Bockhorn L, Gardner SS, Dong D, Karmonik C, Elias S, Gwathmey FW, et al. Application of three-dimensional printing for pre-operative planning in hip preservation surgery. *J Hip Preserv Surg.* 2019;6(2):164-9.
5. Wang C, Ouyang Y, Liu H, Xu C, Xiao H, Hu Y, et al. Surgery simulation teaching based on real reconstruction aid versus traditional surgical live teaching in the acquisition of an adult total hip arthroplasty surgical technique for developmental dysplasia of the hip: a randomized comparative study. *BMC Med Educ.* 2020;20(1):228.
6. Cocco LF, Aihara AY, Franciozi C, Dos Reis FB, Luzo MVM. Three-dimensional models increase the interobserver agreement for the treatment of proximal humerus fractures. *Patient Saf Surg.* 2020;14:33.
7. Shen S, Wang P, Li X, Han X, Tan H. Pre-operative simulation using a three-dimensional printing model for surgical treatment of old and complex tibial plateau fractures. *Sci Rep.* 2020;10(1):6044.
8. Tserovski S, Georgieva S, Simeonov R, Bigdeli A, Röttinger H, Kinov P. Advantages and disadvantages of 3D printing for pre-operative planning of revision hip surgery. *J Surg Case Rep.* 2019;2019(7):rjz214.
9. Barrios-Muriel J, Romero-Sánchez F, Alonso-Sánchez FJ, Rodríguez Salgado D. Advances in Orthotic and Prosthetic Manufacturing: A Technology Review. *Materials.* 2020;13(2):295.
10. Herbert N, Simpson D, Spence WD, Ion W. A preliminary investigation into the development of 3-D printing of prosthetic sockets. *J Rehabil Res Dev.* 2005;42(2):141.
11. Wei D, Li C, Xu Y. Research progress of three-dimensional printing technique in foot and ankle surgery. *Zhongguo Xiu Fu Chong Jian Wai Ke Za Zhi.* 2017;31(7):880-4.
12. Salles AS, Gyi DE. An evaluation of personalised insoles developed using additive manufacturing. *J Sports Sci.* 2013;31(4):442-50.
13. Zeng T, Gao D-W, Wu Y-F, Chen L, Zhang H-T. Small splint external fixation combined with 3D printing brace for the treatment of Colles fractures. *Zhongguo Gu Shang.* 2019;32(6):513-8.