

## Cerebral Infarction Related to Cryptococcal Meningitis in an HIV-Infected Patient: Case Report and Literature Review

Andréa Gurgel Batista Leite, José E. Vidal,  
Francisco Bonasser Filho, Roberta Schiavon Nogueira  
and Augusto César Penalva de Oliveira

*Emílio Ribas Institute, São Paulo, SP, Brazil*

Neurological dysfunction as the first manifestation of AIDS has been found in 10 to 20% of symptomatic human immunodeficiency virus infections. However, stroke has rarely been reported in AIDS patients. The most common causes of cerebral infarction in AIDS are central nervous system infections: toxoplasmosis, cryptococcal meningitis and tuberculosis. Potential vascular mechanisms for cerebral infarction and transient neurological deficits among AIDS patients include deposition of antigen-antibody complexes with vasculitis and infarction, and a direct toxic effect of a viral antigen or infectious agent on vascular endothelium. The role of cryptococcal meningitis in vasculopathy is still not clear. We report a case of cerebral infarction in an HIV-infected patient, with cryptococcal meningitis as the first manifestation of AIDS.

**Key Words:** AIDS, cerebral infarction, stroke, cryptococcal meningitis.

The incidence of AIDS neurological complications varies according to the stage of the disease. Neurological dysfunction as the first manifestation of AIDS has been found in 10% to 20% of symptomatic human immunodeficiency virus (HIV) infections. However, neurological disease may be present in 75 to 90% of cases, based on pathological findings of patients with advanced stages of AIDS [1,2].

Stroke has not often been reported in AIDS patients. Pinto [2] found 40% of AIDS patients to have neurological complications, while only 1.3% suffered stroke [2-7]; cerebral infarction was found in 68% and intracerebral hemorrhage in 32% [2-7].

The most common causes of cerebral infarction in AIDS are central nervous system (CNS) infections: toxoplasmosis, cryptococcal meningitis and tuberculosis [8,9]. The vascular mechanisms of these agents causing cerebral infarction and transient

neurological deficits (TND) in AIDS patients include deposition of antigen-antibody complexes, with vasculitis and infarction [9,10], and a direct toxic effect of a viral antigen or infectious agent on the vascular endothelium [9,11,12]. However, the role of cryptococcal meningitis, particularly in vasculopathy, is not still clear [9,13-15]. We report a case of cerebral infarction in an HIV-infected patient, with cryptococcal meningitis as the first manifestation of AIDS.

### Case Report

A 43-year-old heterosexual man, without any history of intravenous drug use, first diagnosed HIV infected in 1997, presented with a history of headache for 10 days, accompanied by fever and sudden onset of weakness on the right side of the body. He was irregularly using stavudine, lamivudine and nelfinavir, and had no previous history of smoking, systemic arterial hypertension, diabetes mellitus or hyperlipidemia. On examination, he was disarthric and hemiplegic on the right side, with right-side facial palsy. On admission, hemoglobin was 14.6 g/dL, with a blood cell count of  $4.0 \times 10^9$  cells/L and 121,000 platelets/

Received on 10 October 2003; revised 13 February 2004.

Address for correspondence: Dr. Andréa Gurgel Batista Leite. Cardeal Arcoverde Street, 201/136, Pinheiros, São Paulo-SP. Zip code: 05407-000, Brazil. E-mail: aglg1te@uol.com.br.

**The Brazilian Journal of Infectious Diseases** 2004;8(2):175-179  
© 2004 by The Brazilian Journal of Infectious Diseases and Contexto Publishing. All rights reserved.

mm<sup>3</sup>. Lumbar puncture at the day of admission yielded 78 cells (87% lymphocytes, 10% monocytes, 3% neutrophils), with 87 mg/dL protein, 32 mg/dL glucose, a positive India ink preparation, 18 torulas and 3% gemulation, with a positive culture for *Cryptococcus neoformans*. His CD<sub>4</sub><sup>+</sup> count was 2 cells/mL (1%). Antiphospholipid and anticardiolipin antibodies, C and S proteins, and VDRL serology for syphilis were negative. Amphotericin B and antiretroviral therapy (zidovudine, lamivudine, ritonavir, saquinavir) was started, and empiric encephalitic toxoplasmic treatment (dapsona, pyrimethamine, folinic acid) was also applied.

Two days after admission, the patient showed expression aphasia. A computed tomography (CT) scan demonstrated cerebral atrophy, probably due to HIV encephalopathy. Cryptococcal meningitis was treated with 1400 mg of amphotericin B (during five weeks), which was stopped after three negative cultures for *Cryptococcus neoformans*, and secondary prophylaxis was continued with 200 mg of fluconazole, once a day. Due to clinical stabilization, without improvement of hemiplegia and aphasia, another CT (Figure 1) was performed three days after the first one; it revealed a left basal ganglia infarction. At this occasion, the empiric encephalitic toxoplasmic treatment was terminated. After treatment with amphotericin B, the patient remained with hemiplegic and aphasic. Upon leaving the hospital he continued to use antiretroviral drugs, as well as prophylactic treatment with dapsone and azithromycin, and he was placed on motor and phonoaudiologic rehabilitation.

At follow-up nine months later, the patient presented with mild dysarthria and right-side hemiparesis.

## Discussion

Autopsy reports indicate that the frequency of cerebral infarction in AIDS patients is between 19% and 34% [9,18,19], with clinical frequency between 0.5% and 7% [9,20,21]. Engstrom et al. [9], in a five year retrospective study, recorded 12 strokes in 1600 AIDS patients (0.75%). When they compared this finding with

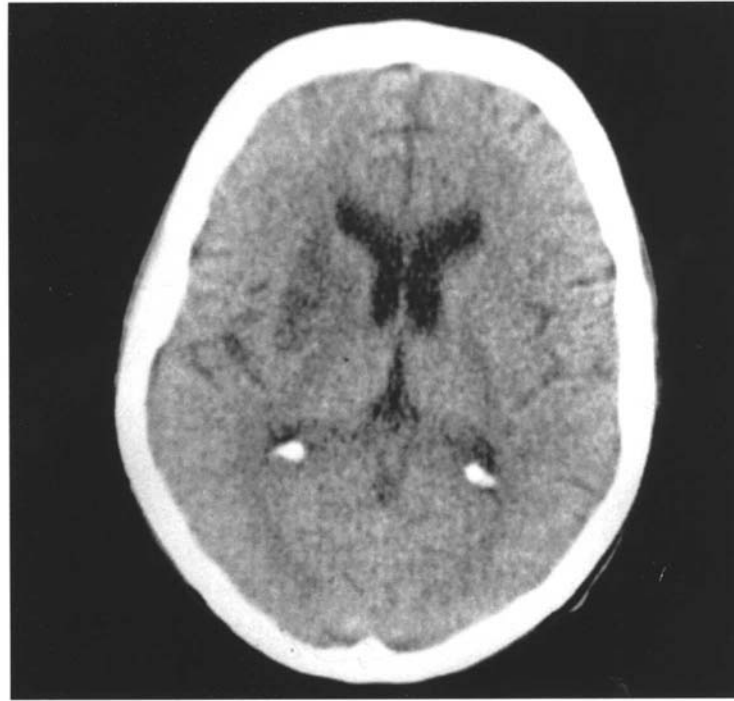
the annual incidence of stroke among young adults (aged 35-45 years) in the general population (0.025%), they concluded that patients with AIDS seem to be at substantially higher risk for stroke. In a case-control study, Qureshi et al. [22] also demonstrated an increased likelihood of cerebral infarction in HIV-infected patients compared with HIV-seronegative individuals. On the other hand, Berger et al. [5], in an autopsy case-control study, found more frequent pathological evidence of cerebral infarction in young adults without AIDS (23%) than in AIDS cases (8%). Comparing clinical and neuropathological findings among those with or without cerebral infarction in the postmortem examination, Mizusawa et al. [19] observed that subacute encephalitis and opportunistic CNS infections were more frequent in the cerebral infarction group (50% and 37.5%, respectively) than in the non-cerebral infarction group (37.3% and 30%, respectively).

The cause of cerebral infarction or TND in AIDS patients has been found in approximately 50% of cases in one study [16]. In another series, 30% of the cases had no identifiable cause and the pathogenesis remained unclear [17].

Autoantibodies to phospholipids, including anticardiolipin antibodies, occur with an elevated frequency in HIV-infected patients [2, 23]. However, there is no consensus on the significance of autoantibodies in the context of HIV infection. The role of antiphospholipid antibodies, including anticardiolipin antibodies, as a pathogenic mechanism of stroke in AIDS patients, remains unclear. Qureshi et al. [22] also suggest that the increased risk of cerebral infarctions in HIV-infected patients results from protein S deficiency; they found an association of 20%. Although protein S deficiency has been associated with cerebral infarction in non-HIV-infected individuals, its role in predisposing HIV-infected patients to cerebral infarctions is not well established [22,24-26].

The frequency of both intravenous drug abuse and cocaine/crack use in this patient population also contributes to other potential causes of cerebral infarctions, including vasoconstriction, vasculitis, increased platelet aggregations, emboli of foreign material, and infective endocarditis [20].

**Figure 1.** Brain computerized tomography scan of an AIDS patient, showing a left basal ganglia lacunar infarction, probably secondary to cryptococcal meningitis



Pinto [2] indicated that nonbacterial thrombotic endocarditis and opportunistic infections in CNS are the most common causes of cerebral infarction during AIDS. Some infections, such as cytomegalovirus [9, 27, 28], herpes zoster [9, 29-31] and tuberculosis [9, 32, 33], are known to produce vasculitis and infarction in the CNS. Gillams et al. [20] found strong evidence of opportunistic infection as a cause of cerebral infarction. In addition, there is increasing evidence of primary HIV vasculitis of the CNS [9]. The role of cryptococcal meningitis in vasculopathy is uncertain [15,22,34].

Several mechanisms are implicated in the development of cerebral infarctions in chronic meningitis: 1) strangulation of the vessels that transverse the exudates at the base of the brain, and development of vasculitis with inflammation, spasms, constriction, and eventually, thrombosis [35-37]; 2) meningeal inflammatory exudate involving the adventitia, which progressively spreads, affecting the entire vessel wall, leading to necrotizing panarteritis, with secondary thrombosis and occlusion [38]; and 3) dilated ventricles stretching the already-compromised vessel, and

possibly developing an infarction [39]. The basal exudates of chronic meningitis are usually most severe at the circle of Willis, which might explain why cerebral infarctions are frequently located in this area [40,41].

Cryptococcus neoformans infection, although it has maximum affinity for the CNS, rarely results in infarction, when compared with other fungal diseases [42-45]. On the other hand, cerebral infarction is more common than TND in AIDS patients with cryptococcal meningitis [9]. To our knowledge, there are six known cases of cerebral infarction and two cases of TND related to cryptococcal meningitis in HIV-infected patients [9,19,46]. In the pre-AIDS era, patients with cryptococcal meningitis occasionally presented stroke [44]. Lan et al. [35] related 28 cases of cerebral infarction secondary to chronic meningitis, 17 with tuberculosis meningitis and 11 with cryptococcal meningitis. Of the 28 cases, six had underlying diseases, but only one had acquired immune deficiency syndrome; they did not specify the type of chronic meningitis in this case. Tjia et al. [47] found an incidence of 4% cerebral infarction secondary to cryptococcal meningitis in HIV-seronegative patients.

Some isolates of *Cryptococcus neoformans* have a propensity to induce either vasculitis or cerebral infarction. A typical mesencephalic cryptococcal lesion with a soap bubble appearance was observed in an autopsy study [34]. Cutaneous cryptococcal infections, suggesting vasculitis, have also been reported [48]. Evidence of arteritis on angiography has also been observed in a patient with cryptococcal meningitis [47]. Histopathologically, a dense perivascular infiltrate has been reported in both AIDS and non-AIDS patients with cryptococcal meningitis [19].

Cerebral infarction related to HIV and/or opportunistic diseases should be an important consideration in the differential diagnosis of stroke of unknown origin, especially in young adults without another risk factor. Cryptococcosis of the central nervous system should be also considered in the differential diagnosis of stroke in patients with AIDS.

## References

- McGuire D., So Y.T. Neurological dysfunction: overview. In: Cohen P.T., Sande M.A., Volberding P.A., eds. The AIDS Knowledge Base. 2nd ed. Boston, Mass: Little Brown & Co; **1994**:5.6-1.,5.6-2.
- Pinto A.N. AIDS and Cerebralvascular Disease. *Stroke* **1996**;27(3):538-43.
- Snider W.D., Simpson D.M., Nielsen S., et al. Neurological complications of the acquired immunodeficiency syndrome: analysis of 50 patients. *Ann Neurol* **1983**;14:403-18.
- Koppel B.S., Wormser G.P., Tuchman A.J., et al. Central nervous system involvement in patients with acquired immunodeficiency syndrome (AIDS). *Acta Neur Scand* **1985**;71:337-53.
- Berger J.R., Moskowitz L., Fischl M., Kelley R.E. Neurological disease as the presenting manifestation of acquired immunodeficiency syndrome. *South Med J* **1987**;80:683-6.
- McArthur J.C. Neurological manifestations of AIDS. *Medicine* **1987**;66:407-37.
- Levy R.M., Bredesen D.E. CNS dysfunction in AIDS. *J Acquir Immune Defic Syndr* **1988**;1:41-64.
- Picard O., Brunereau L., Pelosse B., et al. Cerebral infarction with vasculitis due to varicella zoster virus in patients infected with the human immunodeficiency virus. *Biomed Pharmacother* **1997**;51:449-54.
- Engstrom J.W., Lowenstein D.H., Bredesen D.E. Cerebral infarctions and transient deficits associated with acquired immunodeficiency syndrome. *Am J Med* **1989**;86:528-32.
- Yoshiki T., Hayasaka T., Fukatsu R., et al. The structural proteins of murine leukemia virus and the pathogenesis of necrotizing arteritis and glomerulonephritis in SL/Ni mice. *J Immunol* **1979**;122:1812-20.
- Yoshiki T., Mellors R.C., Strand M., August J.T. The viral envelope glycoprotein of murine leukemia virus and the pathogenesis of immune complex glomerulonephritis of New Zealand mice. *J Exp Med* **1974**;140:1011-27.
- Holland G.N., Kreiger A.E. Neurophthalmology of acquired immunodeficiency syndrome. In: Rosenblum M.L., ed. AIDS and the nervous system. New York: Raven Press **1988**:103-20.
- Cho E.S., Sharer L.R., Little B. Intimal proliferation of leptomeningeal arteries and brain infarcts in subjects with AIDS [abstr]. *J Neuropathol Exp Neurol* **1987**;46:385.
- Weenik H.R., Bruyn G.W. Cryptococcosis of the nervous system. In: Vinken P.J., Bruyn G.W. [eds]. Handbook of Clinical Neurology. New York: North Holland Publishing Company **1978**;22:459-502.
- Freeman W. Fungus infections of the central nervous system. *Ann Intern Med* **1986**;6:595-607.
- Saul R.F., Gallagher J.G., Mateer J.E. Sudden hemiparesis as the presenting sign in cryptococcal meningoencephalitis. *Stroke* **1986**;17:753-4.
- Brew B.J., Miller J. Human immunodeficiency virus type I related transient neurological deficits. *Am J Med* **1996**;101:257-61.
- Levy R.M., Janssen R.S., Bush T.J., Rosenblum M.L. Neuroepidemiology of acquired immunodeficiency syndrome. In: Rosenblum M.L., ed. AIDS and the nervous system. New York: Raven Press **1988**;13-28.
- Mizusawa H., Hirano A., Llana J.F., Shintaku M. Cerebrovascular lesions in acquired Immunodeficiency syndrome (AIDS). *Acta Neuropathol* **1988**;76:451-7.
- Gillams A.R., Allen E., Hrieb K., et al. Cerebral Infarction in Patients with AIDS. *AJNR* **1997**;18:1581-5.
- Levy R.M., Bredesen D.E., Rosenblum M.L. Neurological manifestations of acquired immunodeficiency syndrome (AIDS) at UCSF and review of the literature. *J Neurosurg* **1985**;62:475-95.
- Qureshi A.I., Janssen R.S., Karon J.M., et al. Human Immunodeficiency Virus Infection and Stroke in Young Patients. *Arch Neuro* **1997**;54:1150-3.
- Maclean C., Flegg P.J., Kilpatrick D.C. Anti-cardiolipin antibodies and HIV infection. *Clin Exp Immunol* **1990**;81:263-6.
- Davous P., Horellou M.H., Conard J., Samama M. Cerebral infarction and familial protein S deficiency. *Stroke* **1990**;21:1760.

25. Gomez-Aranda F., Lopez Dominquez J.M., Rivera Fernandez V., Martin Garcia E. Stroke and familial protein S deficiency. *Stroke* **1992**;23:299.
26. Stahl C.P., Wideman C.S., Spira T.J., et al. Protein S deficiency in men with long-term human immunodeficiency virus infection. *Blood* **1993**;81:1801-7.
27. Koeppen A.H., Lansing L.S., Peng S., Smith R.S. Central nervous system vasculitis in cytomegalovirus infection. *J Neurol Sci* **1981**;51:395-410.
28. Weigand D.A., Burgdorf W.H., Tarpay M.M. Vasculitis in cytomegalovirus infection. *Arch Dermatol* **1980**;116:1174-6.
29. MacKenzie R.A., Forbes G.S., Karnes W.E. Angiographic findings in herpes zoster arteritis. *Ann Neurol* **1981**;10:458-64.
30. Morgello S., Block G.A., Price R.W., Petito C.K. Varicella-zoster virus leukoencephalopathy and cerebral vasculopathy. *Arch Pathol Lab Med* **1988**;112:173-7.
31. Eidelberg D.E., Sotrel A., Horoupian D.S., et al. Thrombotic cerebral vasculopathy associated with herpes zoster. *Ann Neurol* **1986**;19:7-14.
32. Molavi A., LeFrock J.L. Tuberculous meningitis. *Med Clin North Am* **1985**;69:315-31.
33. Tandon P.N. Tuberculous meningitis. In: Vinken P.J., Bruyn G.W. [eds]. *Handbook of Clinical Neurology*. New York: North Holland Publishing Company **1978**;33:195-262.
34. Weenink H.R., Bruyn G.W. Cryptococcosis of the nervous system. In: Vinken P.J., Bruyn G.E. [editors]. *Handbook of Clinical Neurology*. Amsterdam: North Holland **1978**;459-502.
35. Lan S.-H., Chang W.-N., Lu C.-H., et al. Cerebral infarction in chronic meningitis: a comparison of tuberculosis meningitis and cryptococcal meningitis. *Q J Med* **2001**;94:247-53.
36. Hosoglu S., Ayaz C., Geyik M.F., Kökçü Ö.F., Ceviz A. Tuberculous meningitis in adults: an eleven-year review. *Int J Tuberc Lung Dis* **1998**;2:553-7.
37. Ahujá G.K., Mohan K.K., Behari P.M. Diagnostic criteria for tuberculous meningitis and their validation. *Tuberc Lung Dis* **1994**;75:149-52.
38. Rich A.R., McCordock H.Á. The pathogenesis of tuberculous meningitis. *Bull Johns Hopkins Hosp* **1933**;52:5-37.
39. Bhagwati S.N. Ventriculolateral shunt in tuberculous meningitis with hydrocephalus. *J Neurosurg* **1971**;35:309-13.
40. Palur R., Rajshekhar V., Chandy M.J., et al. Shunt surgery for hydrocephalus in tuberculous meningitis: a long-term follow-up study. *J Neurosurg* **1991**;74:64-9.
41. Sheller J.R., Des Prez R.M. CNS tuberculosis. *Neurol Clin* **1986**;4:143-57.
42. Kalita J., Bansal R., Ayagiri A., Misra U.K. Midbrain infarction: a rare presentation of cryptococcal meningitis. *Clin Neurol Neurosurg* **1999**;101:23-5.
43. Perfect J.R., Dioracle D.T. Fungal meningitis. In: Scheld W.M., Whitley R.J., Durack D.T. [editors]. *Infections of the Central Nervous System*. 2<sup>nd</sup> ed. Philadelphia: Lippincott Raven **1997**:721-39.
44. Gerber O., Roque C., Coyle P.K. Vasculitis owing to infections. In: Younger D.S. [editor]. *Neurologic Clinics, Vasculitis and The Nervous System*. Philadelphia: Saunders **1997**:903-25.
45. Dalal P.M., Dalal K.P. Cerebrovascular manifestations of infectious disease. In: Vinken P.J., Bruyn G.W., Klawans H.A.L., Toole J.F. [editors]. *Handbook of Clinical Neurology Amsterdam*: Elsevier, **1989**:411-41.
46. Rafal R.D., Friedman J.H. Rostral Basilar Reversible Ischemic Neurologic Deficit in an HIV-infected Patient with Cryptococcal Meningitis. *Am J Med* **1990**;89:248-9.
47. Tjia T.L., Yeow Y.K., Tan C.B. Cryptococcal meningitis. *J Neurol Neurosurg Psychiatry* **1985**;48:853-8.
48. Shrader S.K., Watts J.C., Dancik J.Á., Band J.Á. Disseminated cryptococcosis presenting with cellulitis with necrotising vasculitis. *J Clin Microbiol* **1996**;24:860-2.