

Toxoplasma gondii Infection in Pregnancy

Fabiana Maria Ruiz Lopes¹, Daniela Dib Gonçalves¹, Regina Mitsuka-Breganó²,
Roberta Lemos Freire³ and Itamar Teodorico Navarro³

¹Post-graduate School, Animal Science, Department of Preventive Veterinary Medicine; State University of Londrina (UEL); ²Professor of Department of Pathological Science, UEL; Professor of Department of Preventive Veterinary Medicine, UEL; Londrina, PR, Brazil

Toxoplasmosis is caused by an intracellular protozoan, *Toxoplasma gondii*, which has a wide geographical distribution. The main infection routes are ingestion of cysts from raw or badly-cooked meat, ingestion of oocysts from substrates contaminated with the feces of infected felines and congenital transmission by tachyzoites. The congenital form results in a severe systemic disease, because if the mother is infected for the first time during gestation, she can present a temporary parasitemia that will infect the fetus. Many of the clinical symptoms are seen in congenitally-infected children, from a mild disease to serious signs, such as mental retardation. Early diagnosis during the pregnancy is highly desirable, allowing prompt intervention in cases of infection, through treatment of pregnant women, reducing the probability of fetal infection and consequent substantial damage to the fetus. Conventional tests for establishment of a fetal diagnosis of toxoplasmosis include options from serology to PCR. Prevention of human toxoplasmosis is based on care to avoid infection, understanding the disease and serological exams during gestation. Pregnant women should be tested serologically from three months gestation, until one month after childbirth. Inclusion of serology for congenital toxoplasmosis along with the basic Guthrie test for PKU is of fundamental importance for early diagnosis of infection and so that treatment is initiated, in order to avoid possible sequels in the infant.

Key-Words: Toxoplasmosis, *Toxoplasma gondii*, congenital transmission, pregnant women.

Toxoplasmosis is a widely-distributed zoonosis caused by *Toxoplasma gondii* protozoa [1]. Although there is a high prevalence of unapparent infections, toxoplasmosis can develop into a severe systemic illness when in its congenital form, in which the mother, when infected for the first time during pregnancy, can present a temporary parasitemy with focal lesions generated within the placenta, thereby infecting the fetus [2].

The parasite reaches the fetus transplacentally, causing various degrees of damage, depending on the virulence of the parasite, on the immune response of the mother and on the pregnancy period of the woman when infected, resulting in fetal death or in severe clinical symptoms [3]. It can also develop during the birth of normal children that later presents retinochoroiditis alterations, provoking mental and psychomotor disorders [2]. According to Meenken et al. [5], approximately 80% of children diagnosed with sub-clinical toxoplasmic infection present ocular sequels at some point in their lives. Lesions to the retina are the most frequent sequels, and they can be easily detected in ophthalmological examinations. These signs indicate that there neurological symptoms are possibly involved [5]. A classical study by Sabin [6] describes the tetrad of clinical symptoms of congenital toxoplasmosis: microcephaly or anencephaly, intracranial calcification, mental abnormalities and chorioretinitis [7].

Initially, *T. gondii* enters through the intestinal epithelium, spreading to tissues and breaking through biological barriers, such as the placenta and hematocephaly barriers [8], reaching immunologically-deprived sites where the parasite can cause even more severe pathologies, such as disseminated congenital toxoplasmosis [9], acute neurological complications in immunologically-compromised individuals [10] and ocular pathologies in healthy individuals [11].

Although the severity of the fetal illness is inversely proportional to gestational age, the vertical transmission rate is directly proportional to the pregnancy stage of the mother when acquiring the infection for the first time [12] (Table 1).

Alterations in the mother's immunity during pregnancy were analyzed as a risk factor for toxoplasmosis-sera conversion by Avelino et al. [13], in a study of 3,564 women between 12 and 49 years of age, in the state of Goiânia, Goiás, in central Brazil. The risk of toxoplasmosis seroconversion in pregnant mothers was 2.2 times higher than in women who were not pregnant, in the same age group. This risk increased to 7.7 in adolescents (12 to 20 years old) [13].

Among all women who were first infected by *T. gondii* during pregnancy, 61% will not transmit the illness to the fetus, 26% of the conceptions will present subclinical infection and in 13% there will be a clinical infection (7% in an acute form and 6% in a mild form) [14]. In different countries, the prevalence of toxoplasmosis acquisition during pregnancy varies from one to 14 cases in every 1,000 pregnancies. However, congenital infection occurs in 0.2 to 2.0 newborns in every 1,000 births [15].

Sáfadi et al. [12] studied, during a period of at least five years, 43 children with congenital toxoplasmosis at Santa Casa de São Paulo Hospital from March 1990 until January 1999. They found a prevalence of subclinical infections at birth (88%). Among the 43 children, 22 (51%) developed neurological manifestations, 41 (95%) presented ocular

Received on 6 February 2007; revised 11 August 2007.

Address for correspondence: Dr. Itamar Teodorico Navarro, Universidade Estadual de Londrina (UEL), Departamento de Medicina Veterinária Preventiva, Centro de Ciências Agrárias. Zip code: 86051-990, Londrina, Paraná, Brazil. PO BOX: 6001. Phone/Fax: (43) 3371 4766. E-mail: itamar@uel.br.

The Brazilian Journal of Infectious Diseases 2007;11(5):496-506.
© 2007 by The Brazilian Journal of Infectious Diseases and Contexto Publishing. All rights reserved.

Table 1. Transplacental transmission of toxoplasmosis during pregnancy

Pregnancy age when seroconversion occurred (weeks)	Transplacental transmission* (%)	Risk of the child developing clinical symptoms prior to three years of age (%)
12	6	75
16	15	55
20	18	40
24	30	33
28	45	21
32	60	18
36	70	15
40	80	12

Pinard, Leslie e Irvine, 2003. (Adapted from Dunn et al., 1999). * Fetal infection diagnosis was based on amniocentesis examinations four weeks after the mother's seroconversion.

alterations; among these 36 (88%) were bilateral alterations. Three children, initially presenting normal ocular results, developed chorioretinitis years after the diagnosis, despite being treated during their first year of live. Five other children with delayed diagnosis, and therefore not treated within their first year of life, had reactivation of ocular lesions. The main neurological sequel observed was a delay in neural-psychomotor development. Ophthalmological findings were: chorioretinitis (95%), strabismus (49.0%), nystagmus (47.0%), microphthalmia (9.3%) and cataracts (2.3%). Among the mothers, 19 (44%) had cats in their houses, six (14%) had ingested meat that was not thoroughly cooked, four (9.3%) had contact with sand and soil and 18 (42%) did not know their status in relation to such risk factors [12].

Chorioretinitis is the lesion most frequently associated with congenital toxoplasmosis. Approximately 30 to 60% of uveitis occurs due to *T. gondii* infection. Two kinds of lesion are found: acute retinitis, with severe inflammation, and chronic retinitis, with progressive visual impairment, sometimes progressing to blindness [16].

Despite its low prevalence, there are reports in the literature of cases of congenital transmission in children born from women who had been infected by *T. gondii* prior to conception, whether presenting immunodeficiency or normal immune status [17]. Silveira et al. [18] reported a case of congenital toxoplasmosis in which an immunocompetent mother presented a chorioretinitis scar due to toxoplasmosis diagnosed 20 years previous to the pregnancy. That mother had already had two other pregnancies in which the children were born without any problems, without anti-*T. gondii* antibodies. The third child, however, was serologically diagnosed (anti-*T. gondii* IgG and IgM) with congenital toxoplasmosis, was treated during the first year of live, and presented a scar on the right eye macula when submitted to an ophthalmologic test at nine months of age. Another similar case was reported by Kodjikian et al. [19], in which the mother, immunocompetent and previously infected, had her third child reactive to antibody IgG, IgM and IgA at birth. The child was treated with sulfadiazine-pirimetamine and, at three weeks of age, the fundus exam presented bilateral macular chorioretinitis. These two cases can be explained as re-infections by

different genotypic strains from those of the strains causing the original infection or by reactivation of latent infection induced by cellular immunity associated with pregnancy [18,19].

It is known that *T. gondii* virulence differs in animals depending on the species genotype of this parasite [20]. Moreover, identification of the association between the severity of illness and species genotype is very important for the determination of appropriate treatment and its sequels in each case [21]. Prevalence and consequences of re-exposition to *T. gondii* during pregnancy in women already immune to the parasite are unknown and perhaps underestimated, making it necessary to suspect congenital toxoplasmosis in children presenting suggestive alterations, even though they are children of mothers who suffer from chronic toxoplasmosis.

Prevalence

Couto et al. [15] reported that the prevalence of anti-*T. gondii* IgG antibodies presents regional variations. This fact has been mainly attributed to climate differences and especially to cultural differences. In the city of Santarém, in the state of Pará, from 1997 to 1999, a prevalence of 72.2% for toxoplasmosis in 601 people was reported. Forty-one of these individuals were pregnant women, and among these, there was a prevalence of 82.9% of anti-*T. gondii* IgG antibodies [22].

Mozzatto and Procianny [23] studied 1,250 pregnant women in the state of Rio Grande do Sul; they found a prevalence of anti-*T. gondii* IgG and IgM antibodies of 48.5 and 0.6%, respectively. In their study, IgM antibodies were also examined in blood samples extracted from the umbilical cord of newborns, allowing them to estimate the incidence of congenital toxoplasmosis as 8/10,000 live births.

Spalding et al. [3] evaluated 2,126 pregnant women attended by the public health system of Rio Grande do Sul; they reported that 74.5% (1,583) were IgG positive, and among those, 3.6% (77) were also IgM positive. Among the IgG and IgM-positive pregnant women, 51 children were followed for at least one year of life; 28 were born from IgA positive mothers, most likely in the acute phase of infection and with risk of congenital transmission. Among these (IgG, IgM and IgA positive), three children (10.7%) had congenital infection

confirmed, and one (3.6%) presented characteristic symptomatology. Extrapolating these data to the population in their study, the authors found a transmission rate of 2.2 of every 1,000 births and of 0.7 among every 1,000 live births presenting symptomatology.

Neto et al. [24] in Rio Grande do Sul, reported 47 cases of congenital toxoplasmosis that among 140,914 blood samples from newborns originated from several cities in Brazil between September 1995 and December 1998, through the analysis of specific IgM antibodies. This datum suggests a prevalence of 1/3,000 live births.

In the city of Uberlândia, Minas Gerais state, Segundo et al. [25] evaluated 805 sera samples from umbilical-cord blood. Among these samples, 305 were collected in a private hospital - Hospital e Maternidade Santa Clara and 500 were collected in a public hospital - Hospital de Clínicas da Universidade Federal de Uberlândia, between January and August 2002. All the samples were analyzed using ELISA for the detection of IgG antibodies. Positive samples were also tested by capture ELISA for the detection of IgM and IgA antibodies. A prevalence of 51.6% was found for IgG anti-*T. gondii* antibodies, and 0.5% congenital toxoplasmosis. The toxoplasmosis cases were from the samples collected in the public hospital, which presented a rate of 0.8%.

In Botucatu, São Paulo, Olbrich-Neto and Meira [26] evaluated 478 expecting mothers from two Basic Health Units (Unidades Básicas de Saúde) administered by the Universidade Estadual Paulista (UNESP) from May 1998 to June 1999; the prevalence of IgG anti-*T. gondii* antibodies was 60% and the prevalence of IgM was 2.1%.

Navarro et al. [27] found a prevalence of IgG anti-*T. gondii* antibodies of 55.7% in pregnant women examined by IFI in the region of Londrina, Parana. Six of them (4.3%) presented titers higher than or equal to 1:1024, indicating a possible acute infection. Reiche et al. [28] conducted a retrospective study on 1,559 pregnant women attended by the Regional University Hospital in Northern Paraná, of the State University of Londrina (UEL) and found 67% positivity for IgG antibodies by IFI, and 1.8% for IgM antibodies by ELISA.

Diagnosis

Maternal Diagnosis

Toxoplasmosis is diagnosed in the laboratory based on immunological testing that give the titer of circulating antibodies, detection of the relevant antibody classes at each phase of the illness, isolation of the parasite, PCR, circulating antigen investigation and ultrasound imaging [29].

Similarly to immune-competent adults, pregnant women are frequently asymptomatic or present mild symptoms, making a diagnosis difficult. Consequently, laboratory exams play an important role in the definitive diagnosis of maternal infection. Early diagnosis and adequate anti-parasitary treatment of pregnant women can reduce the rate of transmission to the fetus and the severity of sequels in cases where inter-uterine infection has already occurred [30].

Toxoplasmosis is usually diagnosed by antibody detection. In acute infections, increased levels of IgG and IgM antibodies usually appear within the first or second week of infection [31]. High levels of specific IgG antibodies indicate that the individual has been previously infected. However, these antibodies do not distinguish a recent infection from one acquired a long time before. Detection of specific IgM antibodies can help determine if infection was recent [32]; however, these antibodies can persist for months or even years after acute infection [33]. This fact has limited the use of this method, because it is not possible to determine if the patient has an acute infection, which can put the fetus at risk, or if the infection had occurred months before [32].

Positive IgM test results should be confirmed by reference laboratories, which are able to determine the time since infection using specific tests, such as IgG avidity, or by serological profile (Sabin-Feldman reaction, capture ELISA-IgM, ELISA-IgA, ELISA-IgE and differential agglutination) [34].

The test for IgG avidity is an auxiliary test to determine if the infection is acute or previously acquired when the IgM serological reaction is positive in an asymptomatic patient. The test is based on the greater strength of ionic bindings between antigen and antibody produced from old infections when compared to recent ones [35]. Depending on the method used, pregnant women with high avidity antibodies are those who have been infected at least 3-5 months earlier. This is most useful in pregnant women in their first months of gestation who have a positive test for both IgG and IgM toxoplasma antibodies. When avidity is low or borderline it may be misleading and a more careful interpretation is critical. Low-avidity results may persist for as long as 1 year [36].

The finding of IgA antibodies indicates, with greater assuredness when it compared with IgM, the acute phase of infection; it has faster kinetics, suggesting that the infection occurred less than eight months previously [3]. ELISA and ISAGA are the most widely-used techniques for detection of IgA antibodies [36].

Whenever the serological result is negative, prenatal and follow-up care must be intensified [31] in order to prevent infection of the mother. As the mother rarely develops infection symptoms, but rather has a temporary parasitemy [37], serological diagnosis should be periodical, throughout pregnancy in seronegative women, in order to be aware of a possible infection [38].

The interpretation of results obtained from serological examinations and the care of the pregnant mother according to pregnancy trimester can be seen in Figures 1 and 2.

Fetal Diagnosis

The diagnosis of toxoplasmosis in the fetus was based on direct identification of the parasite by inoculation of amniotic liquid and/or fetal blood in mice, as well as cell culture, the sensitivity rate ranged from 64 to 73 percent and the specificity was 100 percent, however, it takes considerable time to obtain a result [42].

Both these exams should be performed at least four weeks after the mother was infected [39].

Replacing fetal blood analysis, which is a high risk procedure for the fetus, with molecular evaluation of amniotic fluid has provided a low risk diagnosis of congenital toxoplasmosis [29]. Pre-natal diagnosis of congenital toxoplasmosis using polymerase chain reaction (PCR) in amniotic liquid was initially suggested by Grover et al. [40]. This technique uses the amplification of a gene sequence of *T. gondii*; among the cloned genes, the most frequently used is gene B1, due to its greater specificity, being also found in different species of this parasite. Theoretically, PCR can make more than 1,000,000 copies of a genome fragment with hundreds of base pairs after 30 amplification cycles of material from a single parasite in the sample. Fast and simple, this technique can be used on the amniotic liquid starting at 18 weeks of pregnancy. However, it can also show false-positive results, mainly through contamination with amplification products [15].

Hohlfeld et al. [41] studied 339 French women, who seroconverted during pregnancy from September 1991 to December 1992. Congenital infection was demonstrated through conventional methods (inoculation of amniotic liquid and/or blood from the umbilical cord in mice and/or other cellular cultivation and IgM research in umbilical-cord serum) in 34 of 339 fetuses. PCR was positive in all 34 fetuses and in three others who had negative conventional test results. Pre-natal diagnosis was confirmed by post-natal serological tests or by necropsy findings in case of abortion. The authors of that study used a *T. gondii* B1 gene as a target for the PCR test; the sensitivity was 97.4%, compared to 89.5% with conventional methods, demonstrating that PCR is fast, safe and reliable for pre-natal diagnosis of congenital toxoplasmosis.

On the other hand, a study by Castro et al. [42], conducted at the Fetal Medicine Center of the University Hospital of Minas Gerais Federal University (HU-UFMG) from January 1997 to March 1999, evaluated the efficiency of PCR for studies of amniotic liquid. They used a B1-gene primer for the detection of fetal infection by *T. gondii* in 37 pregnant women with acute infection; they also used inoculation in mice and they examined placenta histology. PCR sensitivity was 67% and specificity was 87%. Inoculation in mice gave a sensitivity of 50%, much lower than the levels observed in France, although it also presented a specificity of 100%. In this case, all the pregnant women were treated with medicine specifically prescribed for toxoplasmosis, and the children were examined to confirm or exclude the diagnosis of congenital toxoplasmosis. Among these 37 pregnant women, eight presented positive results for PCR. However, diagnosis was only confirmed in four newborns (through clinical examination and serological observation). Two other children with post-natal diagnosis were negative in the PCR test (false-negatives).

Vidigal et al. [38] analyzed 86 samples of amniotic liquid obtained from women presenting seroconversion during

pregnancy, in Belo Horizonte, MG. These samples were amplified by PCR using a B1-gene primer. Seven (8.2%) were considered positive and 79 (92%) negative. Among the positive samples, only two were not confirmed after inoculation in mice or through clinical observation of the child. Among the negative cases, three presented clinical symptoms of congenital toxoplasmosis, and in one of them, inoculation in mice gave a positive diagnosis. The sensitivity of PCR was 63% and its specificity was of 97%. Inoculation in mice gave a sensitivity of 43% and a specificity of 100%.

Bessières et al. [43] compared the PCR technique with inoculation of the amniotic liquid into mice to test 261 pregnant French women with toxoplasmosis acquired during pregnancy, from 1996 to 1999; they found a sensitivity of 90% for PCR compared to 70% for the inoculation technique and a specificity of 100% for both techniques. The gene B1 was used for amplification.

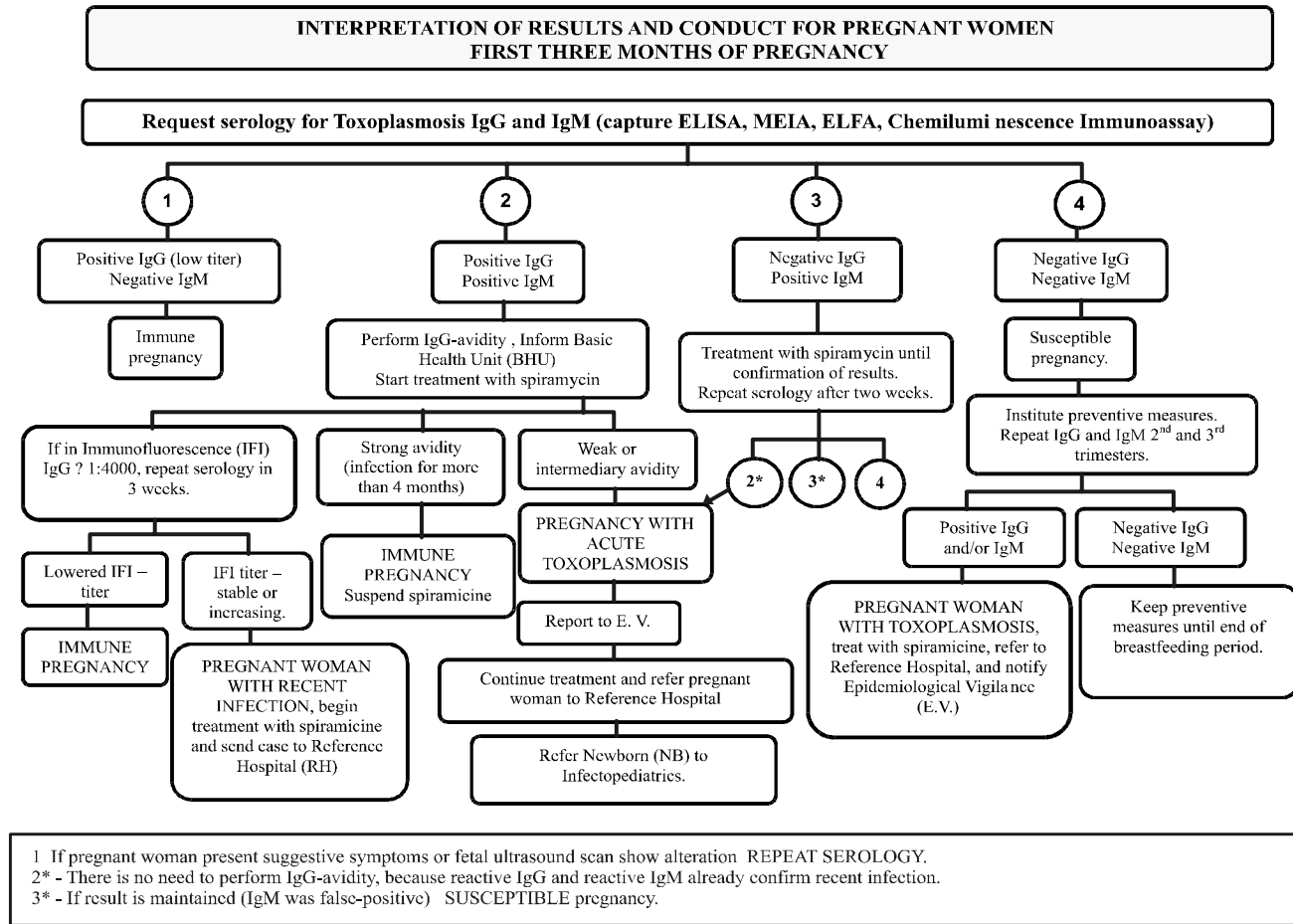
Filisetti et al. [44], in a study in France, compared three targets for the detection of *T. gondii* by PCR (ribosomal DNA 18S, gene B1 and gene AF146527) with inoculation in mice, using 83 samples from 44 newborns whose mothers acquired toxoplasmosis during pregnancy (amniotic liquid collected during pre-natal examination and birth, blood from the umbilical cord collected at birth and peripheral blood from the newborn). They found a sensitivity of 47% for ribosomal DNA 18S, 26% for gene B1 and 42% for gene AF 146527 and inoculation in mice; specificity was 95% for gene B1 and 100% for the other methods. They concluded that the techniques were not significantly different in terms of sensitivity and specificity. However, further analyses should be conducted to resolve problems with the PCR technique and to determine if the gene AF146527 is a suitable target. Association of PCR with inoculation in mice and/or serial repetition of several PCRs in a single sample with repetitive targets [42] increases the sensitivity of pre-natal diagnosis.

There are problems with the PCR technique. Daffos et al. [45] indicated that false-negative results could occur due to later transmission of the parasite to the fetus, after PCR, despite treatment with spiramycin. Grover et al. [40] stated that the primers may not be able to amplify the gene contained in the sample; quality control is necessary so that this does not occur, by testing the primer in several *T. gondii* strains. Examinations with a high rate of false-positive results can be a consequence of contamination at any stage of the process [42].

In addition to the pre-natal exam, quantitative PCR of amniotic liquid can be used for early diagnosis of *T. gondii* fetal infection. Romand et al. [44] observed that fetuses whose mothers acquired the infection prior to 20 weeks of pregnancy and had a parasite load greater than 100/mL are at greater risk of developing severe sequels in the fetus.

As PCR still has limitations in sensitivity and specificity, depending on the methodology and primer used in each laboratory, it should not be the only diagnosis method. Montenegro and Rezende Filho [14] suggest a monthly ultrasound scan of the fetus in pregnant women who have a

Figure 1. Interpretation of results and conduct for pregnant women in the first three months of pregnancy [61].



PREGNANT WOMAN CLASSIFICATION

- 1** PREGNANT WOMAN WITH OLD INFECTION (immune): positive IgG and negative IgM
- 2** PREGNANT WOMAN WITH POSSIBLE RECENT INFECTION: positive IgG and IgM
 - Perform IgG-avidity test and/or IgA research in the same sera sample
 - Interpretation will depend on pregnancy age at the time the sample was collected
- 3** PREGNANT WOMAN POSSIBLY IN INITIAL STAGE OF INFECTION: negative IgG and positive IgM
 - Diagnosis must be confirmed with new serology, after 15 days, to disregard false-positive IgM.
- 4** SUSCEPTIBLE PREGNANT WOMAN (has never been infected): negative IgG and IgM

Figure 2. Interpretation of results and conduct for pregnant women in the latter part of pregnancy (after four months of pregnancy) [61].

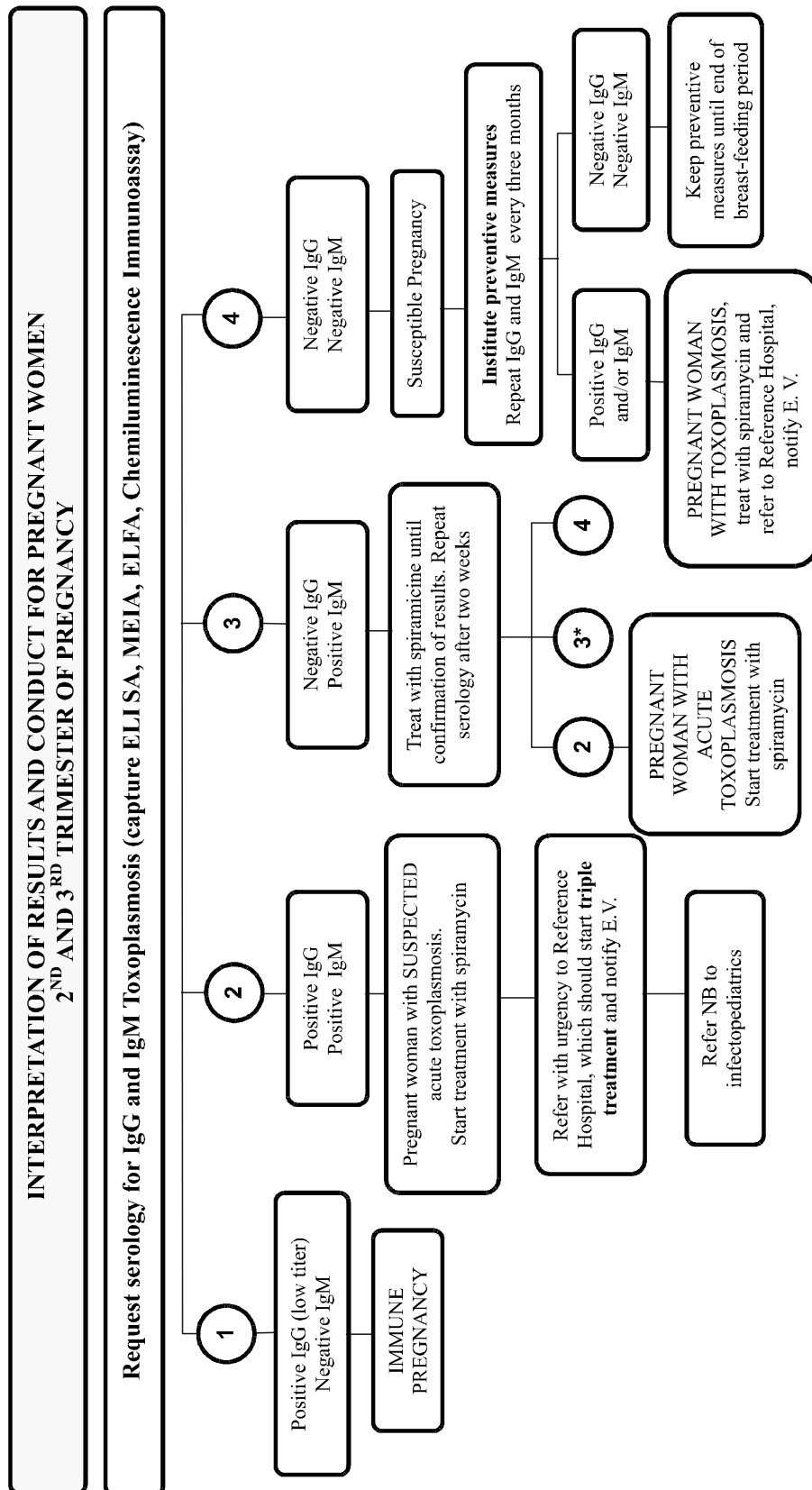
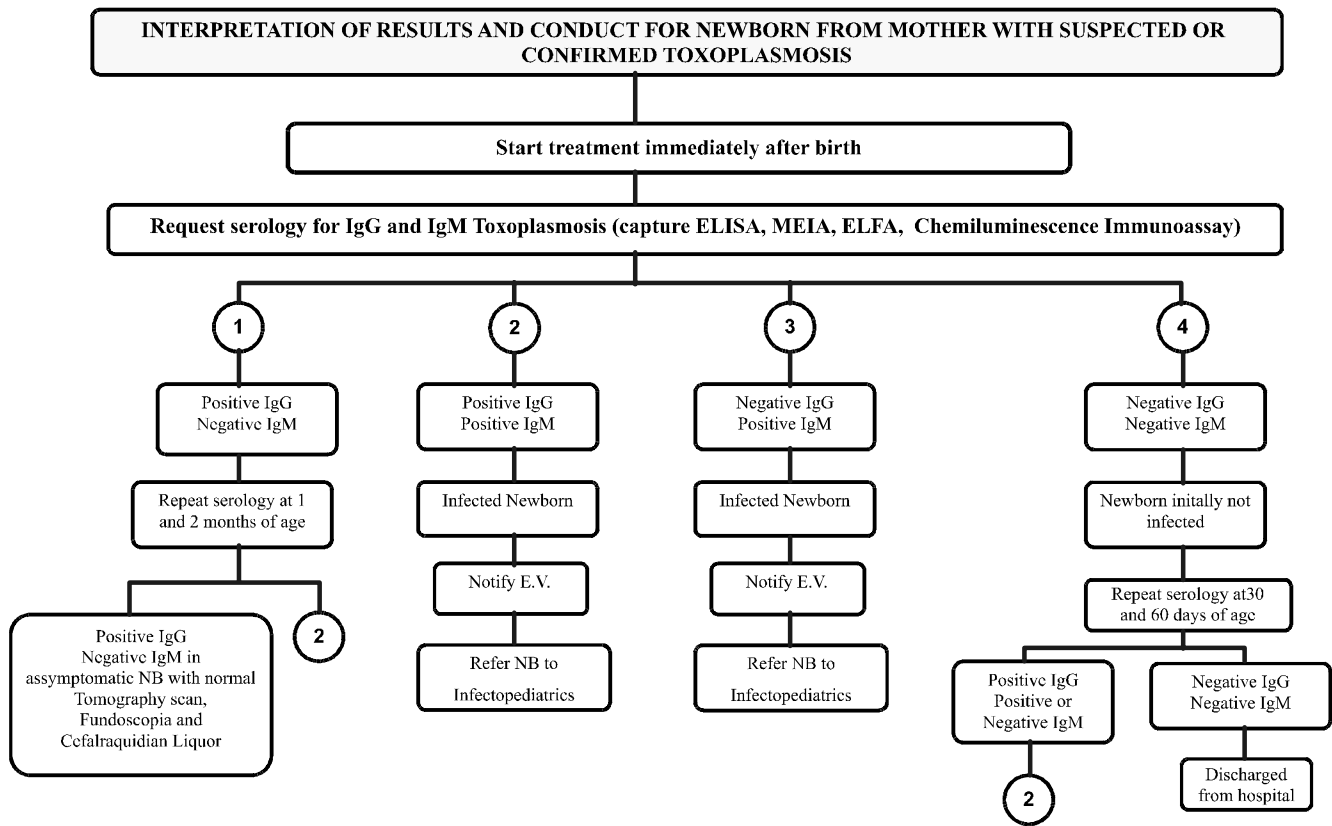


Figure 3. Interpretation of results and conduct for newborns from mothers with suspected or confirmed toxoplasmosis [61].



1 – Serological follow-up will define if there is only passive transfer of IgG from mother or not

CLASSIFICATION OF THE CHILD

SUSPECTED CASE

- Child presenting symptoms or not whose mother presented recent toxoplasmosis during pregnancy
- Child born with signs and symptoms of the illness: jaundice, lymphadenopathy, hepatoesplenomegalia, microcephaly, hydrocephaly, anaemia, spasms, low weight, prematureness, coriorretinitis, brain calcifications, nystagmus, strabismus, iridocyclitis, alterations in cephaloraquidian liquor, positive IgG child.

CONFIRMED CASE

- positive IgM or IgA child after 1 week of age;
- persistently high or increasing IgG or;
- child where *Toxoplasma gondii* was confirmed in placentary or fetal issue in tissue cultivation or bioassey or;
- child presenting positive PCR in amniotic liquid during pregnancy.

DISMISSED CASE

- Negative IgG and IgM child

CASE UNDER INVESTIGATION

- Child with decreasing IgG and negative IgM at 30 days of age.

negative pre-natal diagnosis. They also suggest continuation of spiramycin treatment. Ultrasound scans are important for diagnosis, because they facilitate detection of hydrocephaly and brain calcification. However, other characteristics and alterations cannot be reliably checked.

The anatomic pathological status of the placenta in toxoplasmosis, as in other hematogenic infections, is characterized by focal villitis. However, inflammation of the chorial plate and extra-placental membranes is frequent. Identification of free or encysted parasites can be difficult, demanding use of immunohistochemistry [49]. Castro et al. [42] examined 23 placentas; 10 presented anatomic and pathological alterations compatible with *T. gondii* infection. Among these, four were confirmed as congenital infections through clinical-laboratorial examination of the newborn.

Pinard et al. [50] concluded that seropositive mother should be clinically examined until the end of gestation, and fetus diagnosis should be based on a combination of ultrasound, amniocentesis and cordocentesis exams. Improvement of PCR will permit, in the near future, a decrease in conflicting results, as well as a decrease in the use of invasive techniques [42].

Newborn Diagnosis

Due to false-negative results obtained with fetal-diagnosis methods, all children born from mothers with acute toxoplasmosis must be submitted to serological and clinical exams for the detection of possible infection and sequels. This evaluation must be conducted by pediatric infectologists, neurologists, ophthalmologists and phonoaudiologists.

IgG antibodies, found in the sera of the newborn, can be his/her own or acquired from the mother through the placenta. IgG antibodies inherited from the mother decrease and disappear at from 6-12 months of age [52], whereas endogenous IgG in the infected child persists or increases [53]. IgM and IgA antibodies do not cross the placenta and form the basis for serodiagnosis of congenital infection [52]. Knowledge of these kinetics can help in the diagnosis of congenital toxoplasmosis.

Interpretation of serological examinations and handling of the newborns whose mothers have suspected or confirmed toxoplasmosis can be observed in Figure 3.

We suggest that neonatal screening programs for congenital toxoplasmosis should include on basic Guthrie test for phenylketonuria (PKU) because the serology screening can not detect the infection in the mother.

Treatment

Early treatment of the mother can prevent or lessen congenital infection. Spiramycin does not pass through the placental barrier and does not pose a teratogenic risk for the fetus. Therefore, it can be used alone during the first three months of pregnancy [29]. Spiramycin treatment of the mother seems to control placenta infection and reduces transmission rates up to 60% [37].

A combination of sulfadiazine and pirimetamine, together with folinic acid (triple drug treatment) is indicated for women after 18 weeks pregnancy and when the fetus has a confirmed or very likely infection. This drug association must be avoided during the first three months of pregnancy, due to the potential teratogenic effect of pirimetamine [54] (Figure 4). According to research conducted in Paris, this association is effective in the reduction of the severity of the disease and in the improvement of fetal and neonatal prognosis (2% with severe onset compared to 21% in historical controls) [30]. It has also been observed, in longitudinal studies, that if the woman infected during pregnancy is properly treated and the newborn submitted, during a year, to a classic, specific anti-parasitary treatment regime for toxoplasmosis, the possibilities of neuro-ocular alterations decrease from 50% to 8% [50].

Preventive Measures in Pregnancy

Prevention of human toxoplasmosis is based on care in avoiding the ingestion of tissue cysts and oocysts found in the environment [53]. There is no vaccine to protect humans against this disease. Prevention can be divided into primary, secondary and tertiary. Primary prevention, when applied during pre-natal care, can reduce first-time infections during pregnancy up to 63%. This basically consists of educational and public health programs, recommending the pregnant woman to avoid contact with material potentially contaminated with cat feces and to avoid ingestion of raw or badly-cooked meat or sub-products. The use of gloves when handling earth is also strongly recommended [56].

Secondary prevention consists of early diagnosis of the mother, the fetus and the newborn, and avoiding actions that can cause transplacental transmission of the parasite, through therapeutic intervention in pregnant women and child presenting acute infection. Tertiary prevention is concentrated on early diagnosis through dosage of specific IgA and IgM antibodies in blood collected from the newborn, allowing the use of a therapeutic regime to prevent or lower the risks of sequels [57].

People in the high-risk group, mainly seronegative pregnant women and immunocompromised patients, must avoid contact with cats, soil, as well as handling and consumption of raw meat and its byproducts. Pet cats must only be fed with adequate pet food or cooked food, and they should not be allowed to hunt. Cat sand boxes must be cleaned daily, by people who are not in the high-risk group. The use of gloves for gardening is recommended [58].

Hill and Dubey [58] recommend that hands be thoroughly washed with soap and water after the handling of raw meat, and kitchen utensils, such as cutting boards and knives, should also be cleaned before their use with other food. Fresh meat, sausages and similar products should be cooked at 67°C or frozen to -13°C to prevent cysts from ecloding. Raw food, such as fruits and vegetables, must be thoroughly washed before being consumed.

Figure 4. Therapeutic scheme for pregnancy toxoplasmosis for patients with acute infection [61].

Pregnancy Period	Treatment
<p>1° Trimester (1st to 18th weeks)</p>	<p>Spiramycin (Rovamicina® 500 mg pills) DOSE: 3.0g/day 2 pills every 8 hours – Intake</p>
<p>After 18th week up to birth: “Triple Scheme”</p>	<p>Pirimetamine (Daraprin® 25 mg pills) ATTACK DOSE: 100 mg/day (2nd days) 2 pills every 12 hours – Intake MAINTENANCE DOSE: 50 mg/day 2 pills once a day – Intake</p>
	<p>Sulfadiazine (Sulfadiazin® 500 mg pills) DOSE: 75 mg/Kg/day (maximum of 4.0g/day) 02 pills every 6 hours – Intake Folinic Acid (Leucovorin® or manipulated) DOSE: 15 mg- 1 pill every 3 days – Intake</p>

Navarro et al. [59] found that *T. gondii* cysts resist the effects of salt and condiments found in fresh sausages made from experimentally-infected pork meat, and concluded that only intervals superior to 48 hours of salt at concentrations of 2.5% rendered the parasite inviable. They also found that another condiments did not affect the parasite.

Awareness of the dangers of the disease and serological follow-up during pregnancy are of great importance in the prevention of congenital toxoplasmosis [58]. Countries that have programs for the prevention of congenital toxoplasmosis have a low prevalence of this disease. This is the case for Slovenia, where the incidence of the infection is nine of every 1000 women at risk of acquiring primary infection [60], confirming the importance of infection prevention in pregnancy. Spalding et al. [3] reported that in some countries, such as France and Austria, serological research in pregnant women is mandatory by law. Such procedures have reduced the incidence of fetal toxoplasmosis from 40% to 7%.

Conclusions

Based on information about the risks and damages caused by congenital toxoplasmosis, the implementation of a program to accompany pregnant women is seen as indispensable,

including serological tests every three months, until one month after birth. The addition of toxoplasmosis serology to neonatal screening programs is of utmost importance for the diagnosis of infection, whenever it has not been detected in the mother, so that treatment can be initiated as early as possible, in order to decrease possible sequels on the newborn.

It is also necessary to implement programs to educate health professionals (doctors, nurses, biochemists in the diagnostic lab, community-health agents, etc.) concerning the main congenital infections, specifically toxoplasmosis, as well as educating pregnant women about preventive measures, including pre-natal exams.

References

1. Nicolle C., Manceaux L. Sur un protozoaire nouveau du gondii. Paris **1909**;147:763-6.
2. Dubey J.P. *Toxoplasma, Hammondia, Besnoitia, Sarcocystis* and other tissue cyst-forming coccidia of man and animals. In: Kreier, J.P. Parasitic Protozoa. New York; Academic Press; 3: 101, **1977**.
3. Spalding S.M., Amendoeira M.R.R., Ribeiro L.C., et al. Estudo prospectivo de gestantes e seus bebês com risco de transmissão de toxoplasmose congênita em município do Rio Grande do Sul. Rev Soc Bras Med Trop **2003**;36:483-91.
4. Dressen D.W. *Toxoplasma gondii* infections in Wildlife. J Am Vet Med Assoc **1990**;186:274-6.

5. Meenken C., Assies J., Nieuwenhuizen O., et al. Long term ocular and neurological involvement in severe congenital toxoplasmosis. *Br J Ophthalmol* **1995**;79:581-4.
6. Sabin A.B. Toxoplasmosis: recently recognized disease. *Adv Pediatr* **1942**;1:1-54.
7. Melamed J., Dornelles F., Eckert G.U. Cerebral CT scan alterations in children with ocular lesions caused by congenital toxoplasmosis. *J Pediatr* **2001**;77:475-80.
8. Barragan A., Sibley L.D. Migration of *Toxoplasma gondii* across biological barriers. *Trends Microbiol* **2003**;11:426-30.
9. Peyron F., Ateba A.B., Wallon M., et al. Congenital toxoplasmosis in twins: a report of fourteen consecutive cases and a comparison with published data. *Pediatr Infect Dis J* **2003**;22:695-01.
10. Cohen B.A. Neurologic manifestations of toxoplasmosis in AIDS. *Semin Neurol* **1999**;19:201-11.
11. Silveira C., Belfort Jr. R., Muccioli C., Abreu M.T., et al. A follow-up study of *Toxoplasma gondii* infection in southern Brazil. *Am J Ophthalmol* **2001**;131:351-4.
12. Sáfadi M.A.P., Berezin E.N., Farhat C.K., Carvalho E.S. Clinical presentation and follow up of children with congenital toxoplasmosis in Brazil. *Braz J Infect Dis* **2003**;7:325-31.
13. Avelino M.M., Campos Jr D., Parada J.C.B., Castro A.M. Pregnancy as a risk factor for acute toxoplasmosis seroconversion. *Eur J Obstet Gynecol Reprod Biol* **2003**;108:19-24.
14. Montenegro C.A.B., Rezende Filho J. Toxoplasmose. In: *Infecção Congênita*. Femina **2000**;28:495-7.
15. Couto J.C.F., Melo R.N., Rodrigues M.V., Leite J.M. Diagnóstico pré-natal e tratamento da toxoplasmose na gestação. *Femina* **2003**;31:85-90.
16. Brasil: Fundação Nacional de Saúde. Toxoplasmose. Doenças Infecciosas e Parasitárias: aspectos clínicos, vigilância epidemiológica e medidas de controle. Guia de Bolso. 2. ed. Brasília/DF, **2000**.
17. Hennequin C., Dureau P., N'Guyen N., et al. Congenital toxoplasmosis acquired from an immune woman. *Pediatr Infect Dis J* **1997**;16:75-7.
18. Silveira C., Ferreira R., Muccioli C., et al. Toxoplasmosis transmitted to a newborn from the mother infected 20 years earlier. *Am J Ophthalmol* **2003**;136:370-1.
19. Kodjikian L., Hoigne I., Adam O., et al. Vertical transmission of toxoplasmosis from a chronically infected immunocompetent woman. *Pediatr Infect Dis J* **2004**;23:272-4.
20. Johnson A.M. Speculation on possible life cycle for the clonal lineages in the genus *Toxoplasma*. *Parasitol Today* **1997**;13:393-7.
21. Suzuki Y., Wong S.Y., Grumet F.C., et al. Evidence for genetic regulation of susceptibility to toxoplasmic encephalitis in AIDS patients. *J Infect Dis* **1996**;173:265-68.
22. Souza A.E.S., Souza D.C., Gomez J.G., Matos C.S. Ocorrência de anticorpos anti-Toxoplasma em pacientes atendidos no Laboratório Celso Matos – Santarém, PA. *Rev Bras Anal Clin* **2002**;34:51-2.
23. Mozzatto L., Procianny R.S. Incidence of congenital Toxoplasmosis in Southern Brazil: a prospective study. *Rev Inst Med Trop S Paulo* **2003**;45:147-51.
24. Neto E.C., Anele E., Rubin R., et al. High prevalence of congenital toxoplasmosis in Brazil estimated in a 3-year prospective neonatal screening study. *Int J Epidemiol* **2000**;29:941-7.
25. Segundo G.R.S., Silva D.A.O., Mineo J.R., Ferreira M.S. Congenital toxoplasmosis in Uberlândia, MG, Brazil. *J Trop Pediatr* **2004**;50:50-3.
26. Olbrich-Neto J., Meira D.A. Soroprevalência de vírus linfotrópico de células T humanas, vírus da imunodeficiência humana, sífilis e toxoplasmose em gestantes de Botucatu – São Paulo – Brasil. Fatores de risco para vírus linfotrópico de células T humana. *Rev Soc Bras Med Trop* **2004**;37:28-32.
27. Navarro I.T., Freire R.L., Vidotto O., Ogawa L. Prevalência de anticorpos anti-*Toxoplasma gondii* em mulheres gestantes da região norte do Paraná. I Mostra Acadêmica de Trabalhos Científicos em Medicina Veterinária/ UEL **1998**.
28. Reiche E.M.V., Morimoto H.K., Farias G.N., et al. Prevalência de tripanossomíase americana, sífilis, toxoplasmose, rubéola, hepatite B, hepatite C e da infecção pelo vírus da imunodeficiência humana, avaliada por intermédio de testes sorológicos, em gestantes atendidas no período de 1996 a 1998 no Hospital Universitário Regional Norte do Paraná (Universidade Estadual de Londrina, Paraná, Brasil). *Rev Soc Bras Med Trop* **2000**;33:519-27.
29. Rorman E., Zamir C.S., Rilkis I., Ben-David H. Congenital toxoplasmosis – prenatal aspects of *Toxoplasma gondii* infection. *Reprod Toxicol* **2006**;21:458-472.
30. Hohlfeld P., Daffos F., Thulliez P., et al. Fetal toxoplasmosis outcome of pregnancy and infant follow-up after in utero treatment. *J Pediatr* **1989**;95:11-20.
31. Lindsay D.S., Blagburn B.L., Dubey J.P. Feline toxoplasmosis and the importance of the *T.gondii* oocyst. *Compend Contin Education Pract Vet* **1997**;19:448-61.
32. Leser P. Teste de Avidex de IgG para Toxoplasmose. <<http://www.fleury.com.br/htmls/mednews/0300/mdcontfcb0304.htm>>. Accessed April 30, **2004**.
33. Liesenfeld O., Montoya J.G., Kinney S., et al. Effect of testing for IgG Avidity in the diagnosis of *Toxoplasma gondii* infection in pregnant women: Experience in a US Reference Laboratory. *J Infect Dis* **2001**;183:1248-53.
34. Jones J.L., Lopez A., Wilson M. Congenital Toxoplasmosis. *A F P* **2003**;67:2131-8.
35. Barini R., Bianchi M.O., Camargo M.M., et al. Toxoplasmose: um diagnóstico difícil com testes sorológicos automatizados. In: *Annual Meeting Fetal Medicine and Surgery Society*, 19, Nantucket, MA, USA, **2000**.
36. Remington J.S., Thulliez P., Montoya J.G. Recent developments for diagnosis of toxoplasmosis. *J Clin Microbiol* **2004**;94:1-5.
37. Desmonts G., Couvreur J. Congenital Toxoplasmosis. A prospective study of 378 pregnancies. *N Engl J Med* **1974**;290:1110-16.
38. Vidigal P.V.T., Santos D.V.V., Castro F.C., et al. Prenatal toxoplasmosis diagnosis from amniotic fluid by PCR. *Rev Soc Bras Med Trop* **2002**;35:1-6.
39. Dunn D., Wallon M., Peyron F., et al. Mother-to-child transmission of toxoplasmosis: Risk estimates for clinical counseling. *Lancet* **1999**;353:1829-33.
40. Grover C.M., Thulliez P., Remington J.S., Boothroyd J.C. Rapid prenatal diagnosis of congenital *Toxoplasma* infection by using polymerase chain reaction and amniotic fluid. *J Clin Microbiol* **1990**;28:2297-301.
41. Hohlfeld P., Daffos F., Costa J.M., et al. Prenatal diagnosis of congenital toxoplasmosis with a polymerase-chain-reaction test on amniotic fluid. *N Engl J Med* **1994**;331:695-9.
42. Castro F.C., Castro M.J.B.V., Cabral A.C.V., et al. Comparação dos métodos para diagnóstico da toxoplasmose congênita. *Rev Bras Ginecol Obstet*, Rio de Janeiro, **2001**;23:277-82.
43. Bessières M.H., Cassaing S., Berrebi A., Séguéla J.P. Apport des techniques de biologie moléculaire dans le diagnostic prénatal de la toxoplasmose congénitale. *Immunoanal Biol Spec* **2002**;17:358-62.
44. Filisetti D., Gorcii M., Pernot-Marino E., Villard O. Diagnosis of congenital toxoplasmosis: Comparison of targets for detection of *Toxoplasma gondii* by PCR. *J Clin Microbiol* **2003**;41:4826-8.
45. Daffos F., Forestier F., Capella-Pavlovsky M., et al. Prenatal management of 746 pregnancies at risk for congenital toxoplasmosis. *N Engl J Med* **1988**;318:271-5.
46. Romand S., Chonsson M., Franck J., et al. Usefulness of quantitative polymerase chain reaction in amniotic fluid as early prognostic marker of fetal infection with *Toxoplasma gondii*. *Am J Obstet Gynecol* **2004**;190:797-02.

47. Pedreira D.A.L., Pires M., Rocha e Silva I.R., et al. Ultrasonographic aspects of congenital infections. *Ultr Obstetr Gynecol* **1998**;12:26.
48. Pedreira D.A.L., Camargo M.E., Leser P.G. Toxoplasmosis: will the time ever come? *Ultr Obstetr Gynecol* **2001**;17:459-63.
49. Bittencourt A.L. Infecções congênitas transplacentárias. 1.ed. Rio de Janeiro: Revinter, **1995**.
50. Pinard J.A., Leslie N.S., Irvine P.J. Maternal serologic screening for toxoplasmosis. *J M W H* **2003**;48:308-16.
51. Petersen E. Toxoplasmosis. *Seminars in Fetal & Neonatal Medicine* **2007**;12:214-23.
52. Montoya J.G., Liesenfeld O. Toxoplasmosis. *Lancet* **2004**;363:1965-76.
53. Lappalainen M., Hedman K. Serodiagnosis of toxoplasmosis. The impact of measurement of IgG avidity. *Ann Dell Istit Sup Di San* **2004**;40:81-8.
54. Frenkel J.K. Toxoplasmose. In: Veronesi, R. *Tratado de Infectologia*. São Paulo: ed. Guanabara Koogan, **2002**.
55. Oréface F., Targino A. Na carona do gato. <<http://www.universovisual.com.br>>. Accessed December 12, **2005**.
56. Foulon W. Congenital toxoplasmosis: is screening desirable? *Scand J Infec Dis* **1992**;84(Suppl.):11-17.
57. Hall S.M. Congenital Toxoplasmosis. *B M J* [Review] **1992**;305:291-7.
58. Hill D., Dubey J.P. *Toxoplasma gondii*: transmission, diagnosis and prevention. *Clin Microbiol Infect* **2002**;8:634-40.
59. Navarro I.T., Vidotto O., Giraldo N., Mitsuka R. Resistência do *Toxoplasma gondii* ao cloreto de sódio e aos condimentos em lingüiças de suínos. *Bol Ofic Sanit Panam* **1992**;112:138-43.
60. Logar J., Petrovec M., Novak-Antolic Z., et al. Prevention of congenital toxoplasmosis in Slovenia by serological screening of pregnant woman. *Scand J Infec Dis* **2002**;34:201-4.
61. *Toxoplasmosis Manual for Health Assistance for Pregnant Women and Children, 2006* – State Health Secretary/ Londrina Municipal Health Secretary/ State University of Londrina, **2006**.