

Schistosoma mansoni: a rare cause of tubal infection

Authors

Faria CA¹
Conceição JCJ¹
Valadares TF¹
Rodrigues B¹
Carneiro L²

¹Department of Gynecology, Hospital Universitário Clementino Fraga Filho, Universidade Federal do Rio de Janeiro, Brazil.

²Department of Pathology, Hospital Universitário Clementino Fraga Filho, Universidade Federal do Rio de Janeiro, Brazil.

Submitted on: 07/5/2009
Approved on: 08/25/2009

Correspondence to:
Carlos Augusto Faria
Rua Prof. Rodolpho Paulo Rocco, 255 – Ilha do Fundão
Rio de Janeiro – RJ – Brazil
CEP: 21941-913
Phone/Fax:
+55-21-2562-2890
E-mail: car.far@terra.com.br

We declare no conflict of interest.

ABSTRACT

S. haematobium is an important cause of urinary schistosomiasis, and symptomatic female genital infection is a common gynecological finding in areas where *S. haematobium* is prevalent. On the other hand, genital manifestations of intestinal schistosomes as *S. mansoni* are not frequent or are misdiagnosed. A case of a 40-year-old woman with abnormal uterine bleeding and asymptomatic tubal infection by *S. mansoni* identified in histological examination is presented.

Keywords: schistosomiasis, *S. mansoni*, complications.

[Braz J Infect Dis 2010;14(3):288-290]©Elsevier Editora Ltda.

INTRODUCTION

Schistosomiasis is a water-based disease which is considered the second most important parasitic infection after malaria in terms of public health and economic impact. At least 600 million people are at risk of infection and 200 million are infected with the worm.¹

The disease is endemic in 76 countries. In Africa and Eastern Mediterranean, *S. haematobium* causes urinary schistosomiasis and *S. mansoni* causes intestinal schistosomiasis. Other regions affected by the intestinal form of the disease are the Americas (*S. mansoni*) and East Asia (*S. japonicum* and *S. japonicum*).²

The number of carriers of *S. mansoni* in Brazil was estimated at 6.3 million in 1997, although there are not precise data about the prevalence of the disease.³

Skin-penetrating infections larvae are released from parasitized freshwater snails and are carried by the blood to the veins draining the intestines or the bladder where they mature, mate, and produce eggs. Eggs cause damage to various tissues, particularly the bladder and liver. The reaction to the eggs in tissues causes inflammation and disease. When infected humans excrete parasite eggs with feces or urine into water, the eggs hatch releasing larvae that in turn infect aquatic snails. In snail, the parasite transforms and divides into second-generation larvae which are released into fresh water ready to infect humans.

There is consistent evidence that *S. japonicum* can cause female genital tract lesions,⁴⁻⁸ but the relevance of genital manifestations as a consequence of infection with intestinal schistosomes is not precisely known.⁹

CASE REPORT

A 40-year-old woman with abnormal uterine bleeding, dysmenorrhea and submucous uterine leiomyoma was admitted for surgical treatment. She was born in a Brazilian endemic area for schistosomiasis, and referred contacts with snails from freshwater during childhood. At the age of 16 years, she moved to Rio de Janeiro, where the infection with *Schistosoma mansoni* is unlikely.

She had 6 pregnancies and 3 miscarriages. The first delivery was at 14 years, and the last pregnancy at 33 years.

A Pfannenstiel laparotomy was performed and revealed firm pelvic adhesions. The uterus was enlarged and irregular, and there was a hemorrhagic cyst in left ovary. Hysterectomy and bilateral adnexectomy was performed.

The postoperative course was normal, and the patient was discharged after three days.

Histological examination of uterus revealed uterine leiomyomata and adenomyosis. The left ovary had a hemorrhagic cyst.

Histological examination of sections of the left fallopian tube showed marked chronic salpingitis with numerous granulomas and schistosoma ova in its wall (Figures 1 and 2).

After diagnosis of tubal schistosomiasis, the patient had a Kato-Katz stool examination that revealed *S. mansoni* ova (696 eggs/g faeces) with miracidia. She was then treated with oxamniquine.

Figure 1: Histological section of left fallopian tube showing numerous granulomas distributed throughout the lamina propria, smooth muscle layer and serosa, containing parasite ova of *Schistosoma mansoni* surrounded by lymphocytes, histiocytes, eosinophiles, and multinucleated giant cells. The tubal wall shows remarkable fibrosis and luminal dilatation.

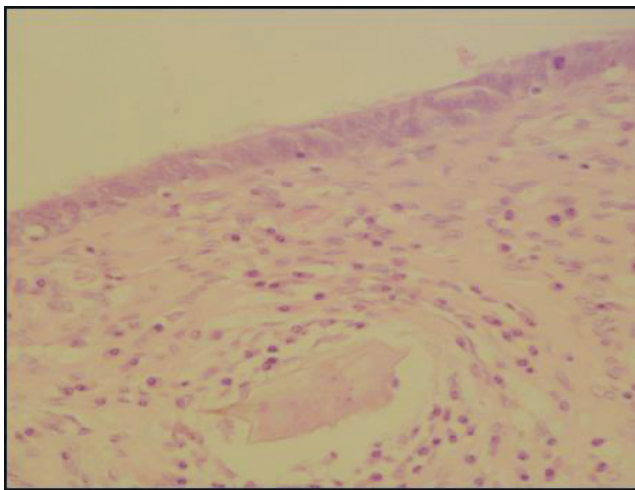
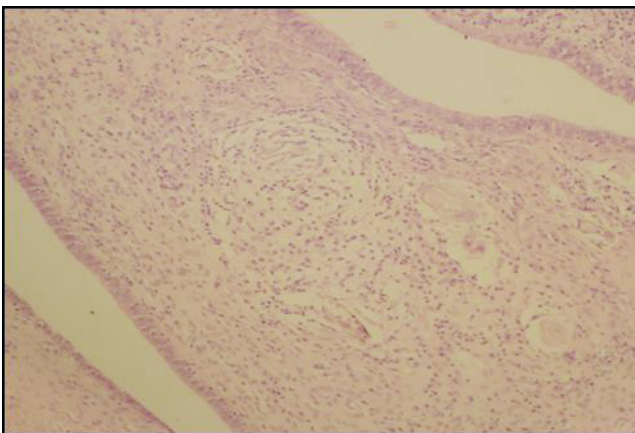


Figure 2: In detail, the lateral spine characterizing the *S. mansoni*.



DISCUSSION

Symptomatic female genital schistosomiasis is a common gynecological finding in areas where *S. haematobium* is prevalent. In contrast, genital manifestations of intestinal schistosomes are not frequent or are neglected and misdiagnosed.

Because schistosomiasis is a highly prevalent poverty-related problem, there are few reports of genital involvement by the worm. Major reports come from developing countries and have been published between 1940 and 1960. Genital involvement by *S. haematobium* is more frequent because adult worms reside in pelvic and vesical venous plexuses, while the others schistosomes live in portal venous system. Nonetheless, there are numerous anastomoses between veins draining genital organs and inferior mesenteric veins. These veins can also have imperfect developed valves, allowing the migration of adult worms of *Schistosoma mansoni* from territory of the portal vein to that of vena cava inferior.¹⁰

The presence of ova in female genital organs can lead to symptoms, such as lower abdominal pain, dyspareunia, bloody cervical discharge, dysmenorrhea, or pelvic tumors. In many cases, it is asymptomatic. Tubal involvement can produce fibrotic scars, tubal occlusion, and infertility.

Genital schistosomiasis can also complicate pregnancy, causing ectopic pregnancy, abortion, preterm labor, intrauterine growth retardation, and stillbirth.

In this case, the patient had symptoms that could be attributed to leiomyoma and adenomyosis. It was not found evidence of uterine involvement by *S. mansoni*.

Although she also had tubal involvement, she had no evidence of impaired fertility. As her first pregnancy was at age 14, so before she had moved to a non-endemic area, it may be postulated that migration of worms to genital vasculature could have occurred after pregnancy. Physiological adaptations of normal pregnancy enhance the chance of ectopic localization of parasite eggs because pelvic veins are definitely enlarged.

REFERENCES

1. WHO – Water-related diseases at: http://www.who.int/entity/water_sanitation_health/diseases/schisto/en accessed 06.15.2009.
2. WHO – Schistosomiasis at: <http://www.who.int/media-centre/factsheets/fs115/en> accessed 6.15.2009.
3. Katz N, Peixoto SV. Critical analysis of the estimated number of schistosomiasis mansoni carriers in Brazil. *Rev Soc Bras Med Trop* 2000; 33(3):303-8.
4. Vass AC, Lucey JJ. Bilharzial granuloma of the fallopian tube. *Br J Obstet Gynaecol* 1982; 89(10):867-9.
5. Letterie GS, Sakas L. Proximal tubal obstruction associated with tubal schistosomiasis. *Int J Gynaecol Obstet* 1992; 37(4):293-6.
6. Morice P, Gadonneix P, Van den Akker M, Antoine M, Villet R. Tubal bilharziasis. *J Gynecol Obstet Biol Reprod* 1993; 22(8):848-50.
7. Ekoukou D, Luzolo-Lukanu A, Mulard C, Bazin C, Ng Wing Tin L. Peritoneal and tubal *S. japonicum* bilharziasis. Two case reports. *J Gynecol Obstet Biol Reprod* 1995; 24(8):819-24.
8. Hoffmann H, Bauerfeind I. High tissue egg burden mechanically impairing the tubal motility in genital schistosomiasis of the female. *Acta Obstet Gynecol Scand* 2003; 82(10):970-1.
9. Yale R, Byunhoon K. Tubal gestation associated with *Schistosoma mansoni* salpingitis. *Obstet Gynecol* 1974; 43(3):413-7.
10. Feldmeier H, Daccal R, Martins MJ, Soares V, Martins R. Genital manifestations of Schistosomiasis mansoni in women: important but neglected. *Mem Inst Oswaldo Cruz* 1998; 93(Suppl I):127-33.