

Unusual localization of an hydatid cyst: first reported case in Buenos Aires, Argentina

ABSTRACT

Hydatidosis is a parasitic infection caused by the tapeworm larva of *Echinococcus* spp. Its relevance lies in its wide distribution, great number of clinical cases and outstanding morbidity. Hydatid infection of the orbit comprises far less than 1% of the total incidence. This is a case of a patient from Argentina complaining of a two-week evolution proptosis of the right eye. A microscopic examination revealed the presence of protoscolices of *Echinococcus* spp. in the fluid obtained during the surgical proceedings. The patient was treated with oral albendazole. To our knowledge, this is the first case of ocular hydatidosis diagnosed in the city of Buenos Aires, Argentina.

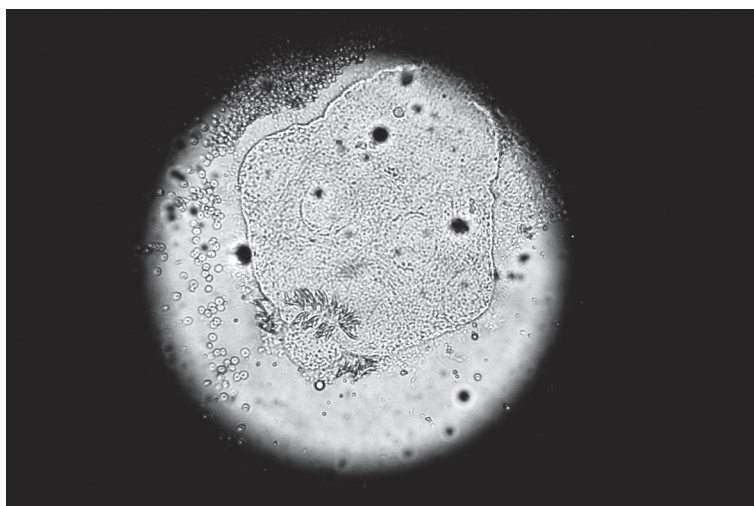
Keywords: echinococcosis; orbit; Argentina.

[Braz J Infect Dis 2011;15(1):81-82]©Elsevier Editora Ltda.

Hydatidosis is a parasitic infection caused by the tapeworm larva of *Echinococcus* spp. In humans, 80% to 95% of hydatids develop in the liver and lungs. The orbit is one of the rarest sites to be involved and comprises far less than 1% of the total incidence.¹ Until 1983, about 15 cases of orbital cysts had been reported in India,² and 11 cases had been reported in South Africa by 1977.³ Recently, in a review between 1984 and 2006, 10 cases of orbital hydatid cyst were reported.⁴ In the *Hospital de Clínicas*, Buenos Aires, we found a case of hydatid cyst of the orbit in a patient from Neuquén, Argentina. The patient was a 41-year-old woman who lived

in the countryside and worked in the manufacture of “*chacinados*”, a kind of cured pork sausage. She complained of a two-week evolution proptosis of the right eye. A computed tomography (CT) scan revealed the presence of a well-delineated, ovoid, heterogeneous, tumor-like mass of 16 x 24 mm in the right eye, confined to the orbit. A whitish cystic mass of the orbit was removed by surgical excision under general anesthesia. Rupture occurred with loss of an uncolored fluid and the microscopic examination revealed the presence of protoscolices of *Echinococcus* spp (Figure 1). After surgical excision, a subsequent lavage of the area

Figure 1: Protoscolex of *Echinococcus* spp.



Authors

Claudia Irene Menghi¹
Claudia Liliana Gatta²

¹Biochemist Parasitologist,
PhD - Head of Parasitology
Laboratory, Hospital de
Clínicas, University of
Buenos Aires

²Biochemist Parasitologist
- Research Assistant,
Parasitology Division,
Hospital de Clínicas,
University of Buenos Aires

Submitted on: 04/30/2010
Approved on: 05/02/2010

Correspondence to:
Dra. Claudia Menghi
Parasitology Division,
Hospital de Clínicas,
Faculty of Pharmacy and
Biochemistry, University
of Buenos Aires
Teodoro García 2350 7
A 1426 Buenos Aires,
Argentina
cmenghi@fibertel.com.ar

We declare no conflict of
interest.

with hypertonic saline solution and sodium bicarbonate was performed. The patient was started on oral albendazole in doses of 400 mg twice a day, and received this drug in three cycles of 28 days, with intervals of 14 days without treatment.

Typically, ocular hydatid cyst is unilateral and occurs with or without hydatid cysts located elsewhere in the body.⁵ Ocular hydatid cysts should be considered in the differential diagnosis of unilateral proptosis, especially in endemic areas. The most frequent clinical findings are exophthalmos, chemosis, lid edema, visual impairment, and restriction of extraocular motility.⁵ Development of effective control programs should be intensified to control hydatidosis. To our knowledge, this is the first case of ocular hydatidosis diagnosed in the city of Buenos Aires, Argentina.

REFERENCES

1. Turgut AT, Turgut M, Koşar U. Hydatidosis of the orbit in Turkey: results from review of the literature 1963-2001. *Int Ophthalmol.* 2004; 25:193-200.
2. Lamba PA, Bhatia PC, Jain M, Baweja U. Hydatid cyst of orbit. *Indian J Ophthalmol.* 1983; 31:23-5.
3. Sevel D, Sapeika RJ. Hydatid cyst of the orbit. *Surv of Ophthalmol.* 1977; 22:101-5.
4. Benazzou S, Arkha Y, Derraz S *et al.* Orbital hydatid cyst: review of 10 cases. *J Craniomaxillofac Surg* (2009). Pubmed DOI: 10.1016/j.jcms.2009.10.001.
5. Selçuklu A, Öztürk M, Külahli I, Doğan H. Successful surgical management of an intraorbital hydatid cyst through a transmaxillary approach: case report. *Skull Base* 2003; 13:101-5.