



The Brazilian Journal of INFECTIOUS DISEASES

www.elsevier.com/locate/bjid



Letter to the editor

Gastrointestinal mucormycosis post lung transplantation



Abbreviations: CF, cystic fibrosis; GI, gastrointestinal; DIOS, distal intestinal obstruction syndrome; LTx, lung transplantation; PGD, primary graft dysfunction; PO, post-operative; CT, computed tomography.

Dear Editor:

Lung transplantation has become the standard therapy for the treatment of eligible patients with terminal pulmonary disease. The last record published by the International Society for Heart and Lung Transplantation – Registry Report of 2018 showed that 64,803 lung transplantations had been performed up to June 2017. The mortality in the first 30 days is high and multifactorial: infections, acute rejection, graft failure¹ and abdominal complication.²

In patients with cystic fibrosis (CF), abdominal complications are common in the immediate postoperative period.³ The most common early abdominal complication in these patients are distal intestinal obstruction syndrome (DIOS), gastroparesis, and Ogilvie's syndrome that may need surgical intervention.²

We describe a case of a cystic fibrosis patient who underwent bilateral lung transplantation with intermittent obstructive abdominal pain and distension. Post mortem diagnosis was intestinal invasive mucormycosis without pulmonary involvement.⁴

A 25 year-old woman, diagnosed with CF at seven months of age and exocrine pancreatic insufficiency was included in the waiting list for lung transplant. She had airway colonization by *Staphylococcus aureus* methicillin-resistant (MRSA), *Pseudomonas aeruginosa* and *Achromobacter sp.* No fungal colonization was identified before the transplant; therefore no antifungal therapy was used.

She underwent bilateral sequential lung transplantation (LTx) without cardiopulmonary bypass. Left lung ischemic time was 315 minutes and right lung 415 minutes. The donor was a 15 year-old man with a traumatic brain injury as cause of death, no comorbidities, six days on mechanical ventilation, PaO₂/FiO₂ of 410 and no use of antibiotics.

Cultures of donor's bronchoalveolar lavage were all negative. Recipient's airway samples were also negative for fungal

cultures and explanted lungs had no signs of fungal infection or colonization.

Post-LTx antimicrobial prophylaxis consisted of inhaled amphotericin and tobramycin, cotrimoxazol, and ganciclovir. Methylprednisolone and basiliximab were used as induction immunosuppression and maintenance was with cyclosporine, mycophenolate and prednisone. Patient also received teicoplanin and piperacillin-tazobactam according to pre-LTx bacterial colonization as well as fluconazole due to vulvovaginal candidiasis. She developed grade 3 primary lung graft dysfunction (PGD) and extubation was possible only on the 12th post-operative (PO) day. The first abdominal manifestation occurred on the 4th PO day with abdominal distension. Computed tomography (CT) of abdomen was performed and showed small bowel and colon distension only, no obstruction points were evidenced, cecum measuring 7 cm and free fluid in the cavity. On the 9th PO day, she had a new abdominal distention episode. GI surgeons diagnosed metabolic ileus or DIOS (Figure 1A) for this intermittent abdominal pain and distension. Fleet enema, prokinetics, laxatives (polyethylene glycol) and parenteral diet improved abdominal distension and patient was discharged from the intensive care unit on 26th PO day.

A new episode of abdominal pain and distension happened two days later. A new CT scan of the abdomen was performed (Figure 1B and 1C), showing hepatic abscess and increased densification of the colon and its surroundings. Patient rapidly developed renal dysfunction and metabolic acidosis. Anidulafungin substituted fluconazole and vancomycin plus meropenem were initiated on 31st PO day. Urgent exploratory laparotomy was performed, evidencing free fluid in the cavity, presence of right colon necrosis in the hepatic angle, liver and duodenal ischemia. Patient presented refractory shock with no response to the therapeutic interventions and died on immediate postoperative period.

The patient's family did not authorize necropsy but the pathology study of the laparotomy product showed: acute colitis with extensive necrosis of the intestinal wall and invasive fungal infection with morphological aspect of *Mucorales* order: large hyphae, rare septations and irregular ramifications at

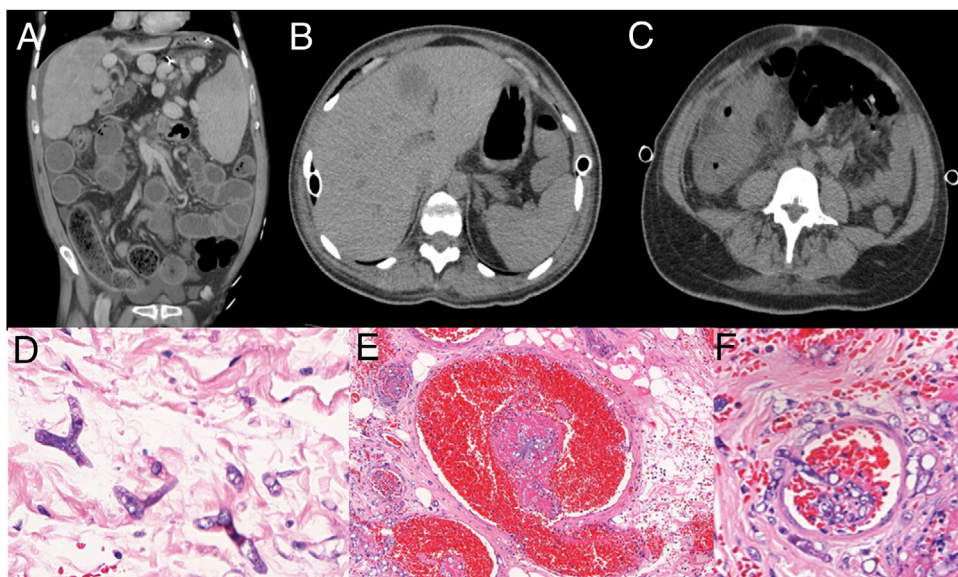


Figure 1 – A. Abdomen CT showing colonic wall thickening, mural striation, mesenteric soft-tissue infiltration, increased pericolic fat mimetizing distal intestinal obstruction syndrome. B. Abdomen CT showing hepatic abscess; C. Increased densification of the colon. D. Large hyphae, rare septations and irregular ramifications at right or acute angle, thin, irregular walls. E. Thrombosis (mycotic thrombi), vascular necrosis and subsequent infarction, and ischemic/hemorrhagic necrosis of affected tissues. F. Angioinvasion, with thrombosis (mycotic thrombi). (D H&E 100x; E H&E 40x; F H&E 40x).

right or acute angle, thin, irregular walls (Figure 1D). Thrombosis (Figure 1E) and angioinvasion (Figure 1F), associated with discrete inflammatory tissue reaction. Lymphadenitis with numerous fungi in the subcapsular sinuses. Acute extensive ulcerated ileitis and fungal infection. Liver necrosis with diffuse fungal infiltration.

This case is emblematic because the post-LTx period has many common but misleading events: primary graft dysfunction, antibiotics, immunosuppressive therapy, and abdominal manifestations misdiagnosed due to the underlying lung disease. The patient presented an intermittent abdominal pain and distension that the LTx team thought about innumerable hypotheses, including DIOS. Ischemic bowel disease is one of the differential diagnosis and may be due to invasive fungal infection such as mucormycosis

The gastrointestinal manifestations in CF patients include pancreatic insufficiency, DIOS and biliary tract complications, which can lead to cirrhosis and hepatic failure.^{3,5} Gastrointestinal mucormycosis in immunocompromised hosts⁶ also have similar clinical manifestations, such as abdominal pain (68%), gastrointestinal bleeding (48%), fever (19%), change in bowel habits (10%). Furthermore, only 25% of all GI mucormycosis have bowel involvement alone among solid organ transplant recipients. There are only few case reports and most of them confirmed only at autopsy, just like our case.⁴ Gastrointestinal mucormycosis is a rare condition after solid organ transplantation. Herein we report a case of invasive fungal infection in small bowel and liver without coinfection with other fungi and no evidence of explanted lung infection.⁷

The diagnosis of gastrointestinal mucormycosis is delayed because of its nonspecific presentation and requires a high degree of suspicion, leading to early biopsy.

In most cases, with negative fungal culture, histopathologic sample is enough to establish the fungal invasive diagnosis.^{8,9} However, histopathologic examination is suggestive, but not confirmatory, as the morphology of fungi in tissue may be difficult to interpret.⁹ Presence of a thick, non-septate hypha branching at right angle on histopathological examination is specific for mucormycosis. Molecular techniques can be used to confirm the diagnosis, although there are no standardized molecular tests currently available. Galactomannan and β -D-glucan test do not detect antigen components of Mucorales cell wall.¹⁰

Mucormycosis has emerged as an important fungal infection with high associated mortality rates. Although any organ system may be affected, the most common reported sites of invasive mucormycosis are paranasal sinuses (39%), lungs (24%), and skin (19%). Mucormycosis restricted to the gastrointestinal tract is uncommon and accounts for only 7% of cases.¹¹

Mucormycosis confined to gastrointestinal tissue accounts for only 4%–7% of all documented cases.¹² Gastrointestinal mucormycosis has a high mortality and 85% of deaths are related to bowel perforation and upper gastrointestinal hemorrhage.¹³ However, when the infection is disseminated, mortality is 100%, such as in our case which involved the liver, lymph nodes and small bowel.

Mucormycosis in the gastrointestinal tract has not been described in the literature in a post-lung transplant patient without pulmonary involvement. However, there are two^{14,15} cases described after cardiopulmonary transplantation. The similarities with our case are gastrointestinal tract involvement and non-specific signs and symptoms, and surgery intervention was also required but with unfavorable outcome.

Mucormycosis is a rare invasive fungal infection that mainly affects immunocompromised patients. LTx recipients, specially with CF, have many early post-operative abdominal manifestation and physicians should be aware of the possibility of gastrointestinal mucormycosis because of the non-specific clinical manifestations and high mortality rate attributed to this infection.

Funding

This research did not receive any specific grant from funding agencies in the public, commercial, or not-for-profit sectors.

Conflicts of interest

The authors declare no conflicts of interest.

REFERENCES

- Chambers DC, Cherikh WS, Goldfarb SB, Hayes D, Kucheryavaya AY, Toll AE, et al. The International Thoracic Organ Transplant Registry of the International Society for Heart and Lung Transplantation: Thirty-fifth adult lung and heart-lung transplant report-2018; Focus theme: Multiorgan Transplantation. *J Heart Lung Transplant*. 2018;37:1169–83.
- Costa HF, Malvezzi Messias P, dos Reis FP, Gomes-Junior O, Fernandes LM, Abdalla LG, et al. Abdominal Complications After Lung Transplantation in a Brazilian Single Center. *Transplant Proc*. 2017;49:878–81.
- Gilljam M, Chaparro C, Tullis E, Chan C, Keshavjee S, Hutcheon M. GI complications after lung transplantation in patients with cystic fibrosis. *Chest*. 2003;123:37–41.
- Almyroudis NG, Sutton DA, Linden P, Rinaldi MG, Fung J, Kusne S. Zygomycosis in solid organ transplant recipients in a tertiary transplant center and review of the literature. *Am J Transplant*. 2006;6:2365–74.
- Kelly T, Buxbaum J. Gastrointestinal Manifestations of Cystic Fibrosis. *Dig Dis Sci*. 2015;60:1903–13.
- Dioverti MV, Cawcutt KA, Abidi M, Sohail MR, Walker RC, Osmon DR. Gastrointestinal mucormycosis in immunocompromised hosts. *Mycoses*. 2015;58:714–8.
- O'Connor C, Farrell C, Fabre A, Eaton D, Redmond K, McSharry DG, et al. Near-fatal mucormycosis post-double lung transplant presenting as uncontrolled upper gastrointestinal haemorrhage. *Med Mycol Case Rep*. 2018;21:30–3.
- Lanternier F, Sun HY, Ribaud P, Singh N, Kontoyiannis DP, Lortholary O. Mucormycosis in organ and stem cell transplant recipients. *Clin Infect Dis*. 2012;54:1629–36.
- Prabhu RM, Patel R. Mucormycosis and entomophthoromycosis: a review of the clinical manifestations, diagnosis and treatment. *Clin Microbiol Infect*. 2004;10 Suppl 1:31–47.
- Cornely OA, Arikan-Akdagli S, Dannaoui E, Groll AH, Lagrou K, Chakrabarti A, et al. ESCMID and ECMM joint clinical guidelines for the diagnosis and management of mucormycosis 2013. *Clin Microbiol Infect*. 2014;20 Suppl 3:5–26.
- Petrikkos G, Skiada A, Lortholary O, Roilides E, Walsh TJ, Kontoyiannis DP. Epidemiology and clinical manifestations of mucormycosis. *Clin Infect Dis*. 2012;54 Suppl 1:S23–34.
- Mungazi SG, Zambuko B, Muchuweti D, Muguti EG, Mlotshwa S. Fatal haemorrhagic duodenal mucormycosis in a non-immunocompromised host: A case report. *Med Mycol Case Rep*. 2017;17:1–3.
- Roden MM, Zaoutis TE, Buchanan WL, Knudsen TA, Sarkisova TA, Schaufele RL, et al. Epidemiology and outcome of zygomycosis: a review of 929 reported cases. *Clin Infect Dis*. 2005;41:634–53.
- Manchikalapati P, Canon CL, Jhala N, Eloubeidi MA. Gastrointestinal zygomycosis complicating heart and lung transplantation in a patient with Eisenmenger's syndrome. *Dig Dis Sci*. 2005;50:1181–3.
- Knoop C, Antoine M, Vachiere JL, Depre G, Alonso-Vega C, Struelens M, et al. Gastric perforation due to mucormycosis after heart-lung and heart transplantation. *Transplantation*. 1998;66:932–5.

Flavio Pola dos Reis *, Silvia Vidal Campos , Vera Demarchi Aiello , Maria Irma Seixas Duarte , Marcos Naoyuki Samano , Paulo Manoel Pego-Fernandes 

Universidade de São Paulo, Faculdade de Medicina, Hospital das Clínicas HCFMUSP, São Paulo, SP, BR

* Corresponding author. Heart Institute (InCor), Av. Dr. Eneas Carvalho Aguiar, 44, CEP 05403-000. Phone/ Fax: +55-11-26615248. E-mail address: flavio.pola@hotmail.com (F.P. Reis). Available online 30 August 2019

1413-8670/

© 2019 Sociedade Brasileira de Infectologia. Published by Elsevier España, S.L.U. This is an open access article under the CC BY-NC-ND license (<http://creativecommons.org/licenses/by-nc-nd/4.0/>).

<https://doi.org/10.1016/j.bjid.2019.07.003>