

# Cutaneous papillomas of green turtles: a morphological, ultra-structural and immunohistochemical study in Brazilian specimens\*

Papilomas cutâneos em tartarugas marinhas:  
um estudo morfológico, ultra-estrutural e  
imunoistoquímico em espécies brasileiras

Eliana Reiko MATUSHIMA<sup>1</sup>; Ademar LONGATTO FILHO<sup>2</sup>; Celso DI LORETTO<sup>2</sup>;  
Cristina Takami KANAMURA<sup>2</sup>; Idércio Luiz SINHORINI<sup>1</sup>; Berenice GALLO<sup>3</sup>; Cecília BAPTISTOLLE<sup>3</sup>

CORRESPONDENCE TO:  
Eliana Reiko Matushima  
Departamento de Patologia da  
Faculdade de Medicina Veterinária  
e Zootecnia da USP  
Av. Prof. Dr. Orlando Marques de  
Paiva, 87  
Cidade Universitária Armando de  
Salles Oliveira  
05508-900 – São Paulo – SP  
e-mail: ermatush@usp.br

1- São Paulo University, Faculty of  
Veterinary Medicine and Animal  
Science, Department of Pathology  
2- Institute Adolfo Lutz, Division of  
Pathology  
3- Tamar Project – IBAMA - Brasil

## SUMMARY

Eleven juvenile green turtles (*Chelonia mydas*) from Atlantic Ocean, Brazil, with multiple cutaneous papillomatosis were examined. Histologically, the papillomas exhibit stromal hyperplasia proliferation and epithelial proliferation. The epithelial cells had nuclear changes suggestive of viral infection and severe nuclear pleomorphism. A large nuclear halo was present in the cases of epithelial proliferation; in these cells, nuclear features were frequently dyscariotic, without inclusion. All fibropapillomas examined were negative for papillomavirus group-specific antigens (BPV) and herpesvirus group-specific antigens (HSV1 / HSV2) by the peroxidase-antiperoxidase technique. Electronic microscopy investigation was negative for papillomaviruses and herpes-viruses particles.

UNITERMS: Green turtles; Fibropapillomas; Papillomatosis.

## INTRODUCTION

Fibropapilloma of captured adult green sea turtles (*Chelonia mydas*) was first described by Luckes<sup>8</sup> and Smith & Coates<sup>11</sup>, over 50 years ago. They observed that papillomas were distributed over the dorsal cervical region, axillary regions of the hindlimbs, eyelids and conjunctivae. Since then the number of green turtles with papillomas seems to have increased. Out of 100 green turtles captured before 1982 none had papillomas; from then until 1986, 30 out of 53 (57%) captured green turtles have this lesion, in the same area: Indian Lagoon System of east central coastal Florida, U.S.A. Similarly, Balazs (pers. comm.) observed that these tumors were present in 35% of all stranded turtles recovered from Hawaiian Islands in 1985 and 1986.

Jacobson<sup>5</sup> suggested the lesions have an infectious etiology. Papillomas were first observed in wild adults and later on a farm reared turtles previously free of gross lesions. As in many papillomatous lesions in many mammals, including man, a viral etiology (Papillomavirus) is believed to be involved.

Sundberg<sup>12</sup> failed to identify papillomavirus antigens in reptilian species; however Jacobson et al.<sup>4</sup> recently described an association between herpesvirus and fibropapillomas in green turtles; microscopic evaluation (H.E.) revealed areas of ballooning degeneration of epidermal cells associated with intranuclear eosinophilic inclusions. On electron microscopy these inclusions consisted of 77 - 90 nm virus-like particles. Envelopment of these particles was observed at the nuclear membrane and mature

enveloped particles of 110 - 120 nm were present in the cytoplasm. Morphology, size, and location of the particles were consistent with those of the Herpetoviridae.

The present study focus on features of cutaneous papillomatosis lesions of sea green turtles (*Chelonia mydas*). Lesions were examined morphologically and ultrastructurally. Attempts in characterize the etiological agent using a polyclonal antibody for bovine papillomavirus (BPV) and monoclonal antibodies to herpes simplex virus (HSV) 1 and 2 are also reported.

## MATERIAL AND METHOD

Samples of multiple cutaneous papillomatosis of 11 green turtles (*Chelonia mydas*) from Atlantic Ocean were examined at Department of Pathology of the Veterinary Medicine and Animal Science Faculty of São Paulo University, Brazil, and Pathology Division of Adolfo Lutz Institute, Brazil. Two turtles were also submitted to necropsy; these animals had died of respiratory failure caused by drowning.

Ten turtles were from the coastal area of São Paulo and the remaining one from the coastal area of Bahia. Ten were found dead and one was still alive within 10 months after observation.

Fragments of papillomas were fixed in 10% formalin buffered solution, processed routinely for histology. Tissue samples of papillomas from the single living animal were fixed in glutaraldehyde and 0.1 M phosphate buffer (2%), pos-fixed in 1% osmium tetroxide and then immersed in 0.5% uranyl acetate overnight

\* Apoio financeiro: FAPESP.

and dehydrated in increasing concentrations of acetone. The fragments were then embedded in Araldite 502. Ultra thin sections were cut in a Sorwall MT-500 ultra microtome and contrasted with uranila acetate and lead acetate. Photomicrographs were performed under a Philips EM 201 transmission electron microscope.

Four µm sections were submitted for immunohistochemical study. The protocol used was described by HSU et al.<sup>4</sup>, and consisted of three main steps. Sections were treated with 3% hydrogen peroxide to block endogenous peroxidase activity. Incubation with policlonal antibodies anti-papillomavirus (DAKO B580) and policlonal antibodies anti-Herpes Simplex I (DAKO B114) and anti-Herpes Simplex II (DAKO B116), obtained in rabbit, were performed at 4°C for 18 hours. Biotinylated goat anti-rabbit immunoglobulin (VECTOR BA1000) was added, and incubated at 37°C for 30 minutes. Reaction was amplified by avidin-biotin-peroxidase complex (VECTOR PK4000) in an incubation at 37°C for 30 minutes. All incubations were concluded with two PBS washings of 5 minutes each. Diaminobenzidine 50 mg% (Sigma D5637) and 0.1 % H<sub>2</sub>O<sub>2</sub> in PBS were used as chromogen substrate and Harris Hematoxylin in the counter staining<sup>4</sup>.

## RESULTS

Papillomas were distributed over the dorsal cervical region, axillary regions of the hind legs, eyelids and conjunctivae and ranged from 0.5 – 10 cm in diameter. These growths involved all the soft integumentary tissue, but were particularly numerous in the axillary and inguinal soft tissue adjacent to all four legs.

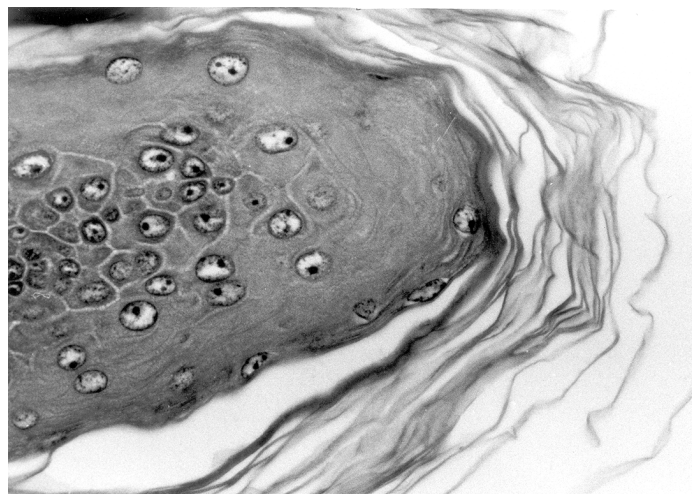
In all cases, elliptical structures surrounded by a chestnut-brown capsule (trematode parasite eggs) and engulfed by multinucleated giant cells were observed scattered in the interstitium of the papillomas. The main histopathological findings are related on Tab. 1.

Seven papillomas exhibit stromal proliferation, and 4 of them epithelial proliferation. When compared with that of human papillomavirus the lesions exhibit nuclear features suggestive of the viral infection, which were observed in all cases with epithelial proliferation. Two cases with stromal hyperplasia showed a discreet epithelial proliferation associated with cytological evidences of

viral infection. Severe nuclear pleomorphism, not seen in all cases with predominantly fibroplasia, was also observed in all cases with epithelial proliferation. A large nuclear halo similar to the human papillomavirus koilocyte was present in cases with epithelial proliferation; in these cells, nuclear features were frequently dyscariotic, without inclusion (Fig. 1).

All fibropapillomas examined were negative for papillomavirus group-specific antigens (BPV) and herpesvirus group-specific antigens (HSV1/ HSV2) by the peroxidase-antiperoxidase technique.

Electron microscopy investigation was negative for viral particles of papillomaviruses and herpes-viruses; a prominent deposition of collagenous fibers was observed. The nucleoli of epithelial cells were prominent cytoplasmic vacuolization was widespread and nuclear vacuolization occurred occasionally. Many cytoplasmic vacuolizations were large enough to displace the nucleus to the cell periphery. Ultra-structural changes confirmed the histopathological findings (Fig. 2).



**Figure 1**

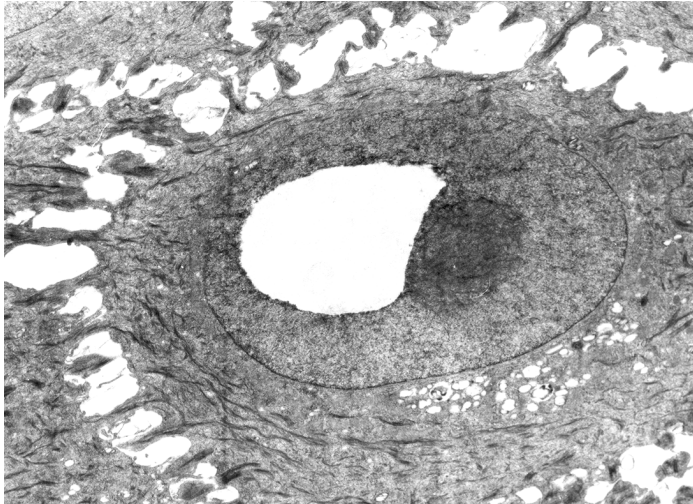
A papilloma showing an arborizing pattern, with nuclear halo and nuclear features discariotic, without inclusion. HE x 165.

**Table 1**

Main histopathological findings of the green turtles, *Chelonia mydas*, papillomas (n = 11), São Paulo, Brasil, 1995.

Case	Papillary Feature	Hyperplastic Stroma	Hiperqueratosis	Hyperplastic Epithelia	Prominent Nucleolus	Diskariosis	Nuclear Halo	Nuclear Inclusion
1	P	P	A	A	A	A	A	A
2	P	A	P	P	P	P	P	A
3	P	A	P	P	P	P	P	A
4	P	P	P	A	A	P	A	A
5	P	P	P	A	A	A	A	A
6	P	P	A	P	P	P	P	A
7	P	A	P	A	A	A	A	A
8	P	P	P	A	A	A	P	A
9	P	A	A	P	P	P	P	A
10	P	P	A	P	P	P	P	P
11	P	P	P	P	P	P	P	A

A = absent; P = present.



**Figure 2**

Transmission electron micrograph of the epidermal cell. A vacuolization is observed in the intra-nuclear region. x 6705.

## DISCUSSION

The proliferative cutaneous lesions of the green turtles from this report were similar to the previously described fibropapillomas of green turtles from Florida (Lucke; Smith and Coates)<sup>8,11</sup>. The lesions had some morphological similarities with cutaneous fibropapillomas of mammals, i.e., epithelial hyperplasia, marked increase in dermal collagen and koilocytotic-like atypia, a cytopathological feature of productive papillomavirus infection (Sundberg)<sup>12</sup>. Immunohistochemical and ultra-structural investigations failed to detect viral particles.

Herpesvirus particles have also been found in papillomas of a wide variety of vertebrate, including the European green lizard,

*Lacerta viridis* (Raynaud and Adrian)<sup>9</sup>, African elephants, *Loxodonta africana* (Jacobson, Sundberg, Gaskin, Kollias and O'Banion)<sup>7</sup>, and green turtle, *Chelonia mydas* (Jacobson, Buegelt, Willians and Harris)<sup>4</sup>. The involvement of herpesvirus as a primary causative agent of these lesions is, until now, uncertain. Except for its demonstration by indirect immunofluorescence or through the observation of intranuclear amphophilic inclusions in HE stained sections, there's no evidence of the role of this virus in papillomatous lesions.

Electron microscopy studies could not identify structures corresponding to the amphophilic intranuclear inclusions seen by light microscopy. The composition of these structures remains unknown. The surface of the inclusions resembled those seen in gray patch disease of green turtles, a skin disease caused by a herpesvirus (Rebel, Rywlin and Haines)<sup>10</sup>. Our results do not suggest a viral infection.

Trematode eggs were found in all papillomatous lesions of our cases. Trematodes (Spirorchidae) are commonly encountered in the cardiovascular system of the loggerhead sea turtle *Caretta caretta* (Wolke et al.)<sup>13</sup> and in both farmed (Greiner et al. and Glazebrook; Campbell)<sup>3,2</sup> and wild (Glazebrook; Campbell; Jacobson et al.)<sup>1,5</sup> green turtles, but they are considered incidental findings.

Further studies are required in order to explain the etiology and biological behavior of these papillomatous lesions.

## ACKNOWLEDGMENTS

We are very grateful to Fundação Pró-TAMAR, São Paulo State Fishing Institute - Santos and Ubatuba bases, São Paulo State Forest Institute - Ilha do Cardoso - SP, Maritime Biology Center - CEBIMar - São Sebastião - SP, and Santos Municipal Aquarium - Santos - SP, for sending us the specimens used in the present work.

## RESUMO

Onze tartarugas verdes juvenis (*Chelonia mydas*) originárias do Oceano Atlântico, Brasil, com múltiplas lesões cutâneas papilomatosas foram examinadas. Histologicamente, os papilomas exibiam proliferação estromal hiperplásica e proliferação epidermal. As células epiteliais apresentavam alterações nucleares sugestivas de infecção viral e pleomorfismo nuclear severo. Um halo grande nuclear estava presente nos casos de proliferação epitelial; nessas células, características nucleares foram freqüentemente discarióticos, sem inclusão. Todos os fibropapilomas examinados foram negativos para antígenos grupo-específico para papilomavírus (BPV) e antígenos grupo-específico para herpesvírus (HSV1/HSV2) pela técnica peroxidase-antiperoxidase. Investigação por microscopia eletrônica foi negativa para partículas virais de papilomavírus e herpesvírus.

UNITERMOS: Tartarugas marinhas; Fibropapilomas; Lesões papilomatosas.

## REFERENCES

- 1- GRAZEBROOK, J. S.; CAMPBELL, R. S. F. A survey of the diseases of marine turtles in Northern Australia. II. Oceanarium-reared and wild turtles. **Diseases of Aquatic Organisms**, v. 9, p. 97-104, 1990b.
- 2- GRAZEBROOK, J. S.; CAMPBELL, R. S. F. A survey of the diseases of marine turtles in Northern Australia. I. Farmed turtles. **Diseases of Aquatic Organisms**, v. 9, p. 83-95, 1990a.
- 3- GREINER, E. C.; FORRESTER, J. J.; JACOBSON, E. R. Helminthes of mariculture-reared green turtles (*Chelonia mydas mydas*) from Grand Cayman British West Indies. **Proc. Helminth. Soc. Wash.**, v. 47, p. 142-144, 1980.
- 4- HSU, S. M.; RAINE, L.; FANGER, H. Use of Avidin-Biotin-Peroxidase Complex (ABC) in Immunoperoxidase Techniques: a comparison between ABC and Unlabeled Antibody (PAP) Procedures. **The Journal of Histochemistry and Cytochemistry**, v. 29, n. 4, p. 577-580, 1981.

- 5- JACOBSON, E. R.; MANSELL, J. L.; SUNDBERG, J. P.; HAIJAR, L.; REICHMANN, M. E.; EHRHART, L. M.; WALSH, M.; MURRU, F. Cutaneous fibropapillomas of green turtles (*Chelonia mydas*). **Journal Comparative Pathology**, v. 101, p. 39-52, 1989.
- 6- JACOBSON, E. R.; BUERGELT, C.; WILLIAMS, B.; HARRIS, R. K. Herpesvirus in cutaneous fibropapillomas of the green turtle *Chelonia mydas*. **Diseases of Aquatic Organisms**, v. 12, p. 1-6, 1991.
- 7- JACOBSON, E. R.; SUNDBERG, J.; GASKIN, J. M.; KOLLIAS, G. V.; O'BANION, M. K. Cutaneous papillomas associated with a herpesvirus-like infection in a herd of captive African elephants. **Journal of the American Veterinary Medical Association**, v. 189, p. 1075-1078, 1986.
- 8- LUCKE, B. Studies on tumors in cold-blooded vertebrates. **Annual Report of the Tortugas Laboratory of the Carnegie Institute of Washington**, v. 38, p. 92-94, 1938.
- 9- RAYNAUD, M. M. A.; ADRIAN, M. Lesions cutaneous a structure papillomateuse associées a des virus chez le lézard vert (*Lacerta viridis* Laur). **Compte. Rendus. Academie des Sciences**, Paris, v. 238, p. 845-847, 1976.
- 10- REBEL, G.; RYWLIN, A.; HAINES, H. A herpesvirus-type agent associated with skin lesions of green sea turtles in aquaculture. **American Journal of Veterinary Research**, v. 36, p. 1221-1224, 1975.
- 11- SMITH, G. M.; COATES, C. W. Fibroepithelial growths of the skin in large marine turtles, *Chelonia mydas* (Linnaeus). **Zoologica**, v. 23, p.93-96, 1938.
- 12- SUNDBERG, J. P.; JUNGE, R. E.; LANCASTER, W. D. Immunoperoxidase localization of papillomaviruses in hyperplastic and neoplastic epithelial lesions of animals. **American Journal Veterinary Research**, v. 45, p. 1441-1446, 1984.
- 13- WOLKE, R. E.; BROOKS, D. R.; GEORGE, A. Spirorchidiasis in loggerhead sea turtles (*Caretta caretta*): Pathology. **Journal Wildlife Diseases**, v. 18, p. 175-185, 1982.

**Received: 12/05/1998**

**Accepted: 02/07/2001**