

Short Communication

Partial duplication of chromosome 20(pter→q12)

Valter Augusto Della-Rosa¹ and Angela M. Vianna-Morgante²

Abstract

Partial duplication of chromosome 20 (20pter→20q12) resulting from a maternally inherited translocation t(14;20)(q11;q13) is described in a female child with neuropsychomotor retardation and multiple congenital anomalies. To our knowledge this is the largest duplication of chromosome 20 that includes segments of both the short and the long arms thus far described in a live-born child.

INTRODUCTION

Numerical and structural abnormalities involving chromosome 20 are extremely rare in live-born babies. Most cases of partial duplications involve the short arm and just a few affect the long arm (Sanchez *et al.*, 1977; Pawlowitzki *et al.*, 1979; Sax *et al.*, 1986). Some partial duplications of chromosome 20 showed involvement of the entire short arm and part of the long arm, associated with small duplications or deletions of other autosomal segments (Krmptotic *et al.*, 1971; Marcus *et al.*, 1979; Rudd *et al.*, 1979; Schinzel, 1980; Delicado *et al.*, 1981).

We describe a girl with partial duplication of chromosome 20 (20pter→20q12) which resulted from a maternally inherited translocation t(14;20)(q11;q13). To our knowledge, this is the largest partial duplication of chromosome 20 described hereto.

CLINICAL REPORT

The patient (Figure 1), a black female child, is the first daughter of healthy, unrelated parents, the mother and father being 23 and 25 years old, respectively, at her birth. The mother's second pregnancy resulted in a spontaneous abortion after two months of gestation. The girl was born post-term by cesarean section, after an uneventful pregnancy. At birth, weight was 2,450 g and length, 44.5 cm. Her health was good, but she was noted to be hypotonic. Motor development was delayed: she held up her head at 5 months of age and sitting without support occurred only at 10 months.

At 3 years and 6 months of age, the patient presented psychomotor retardation; she could not stand up or walk; there was no speech development and generalized hypotonia was observed. Her height was 77 cm (below the 3rd centile) and weight, 12 kg (3rd centile). She had a round

face and a narrow forehead. The frontal bones presented a prominent metopic suture and lateral depressions. Facial dysmorphisms included a mongoloid slant of palpebral fissures, apparent hypotelorism, bilateral convergent strabismus, a depressed broad nasal bridge, a short nose with upturned tip and large nares, a long philtrum, a thin upper lip, and retrognathia. She had a highly arched palate. The ears were short, low set and posteriorly angulated, with overfolding of the helices. The neck was short, and the abdomen appeared normal except for an umbilical hernia. The distal phalanges of digits and toes, especially of the thumbs and halluces, were broad. The hands showed single palmar flexion creases. Pes planus and a prominent calcaneum were observed bilaterally. Radiological examination documented thoracic kyphosis. An electroencephalogram at 3 years of age did not reveal any abnormalities.

At 6 years and 9 months of age, the patient was a healthy girl with severe neuropsychomotor retardation. She sat down without support, but could not stand up or speak. Comprehension of simple orders was rather poor, irritability was constant and sphincter control had not developed. Her height was 92.5 cm (below the 3rd centile) and the head circumference, 47.5 cm (below the 2nd centile).

CYTOGENETIC STUDIES

Chromosomal analysis was performed on peripheral blood leukocytes after G banding. In the propositus, a chromosome 14 was replaced by a derivative chromosome, resulting from a translocation of almost the entire long arm of chromosome 14 to the long arm of chromosome 20 at band 20q13.1 (Figure 2a). Examination of parental chromosomes revealed a normal 46,XY paternal karyotype and an abnormal 46,XX,t(14;20)(14pter→14q11.2::20q13.1→20qter;20pter→20q13.1::14q11.2→14qter) maternal karyotype (Figure 2b).

¹Departamento de Biologia Celular e Genética, Fundação Universidade Estadual de Maringá, Maringá, PR, Brasil.

²Departamento de Biologia, Instituto de Biociências, Universidade de São Paulo, 05422-970 São Paulo, SP, Brasil.

Send correspondence to A.M.V.-M. E-mail: avmorgan@ib.usp.br

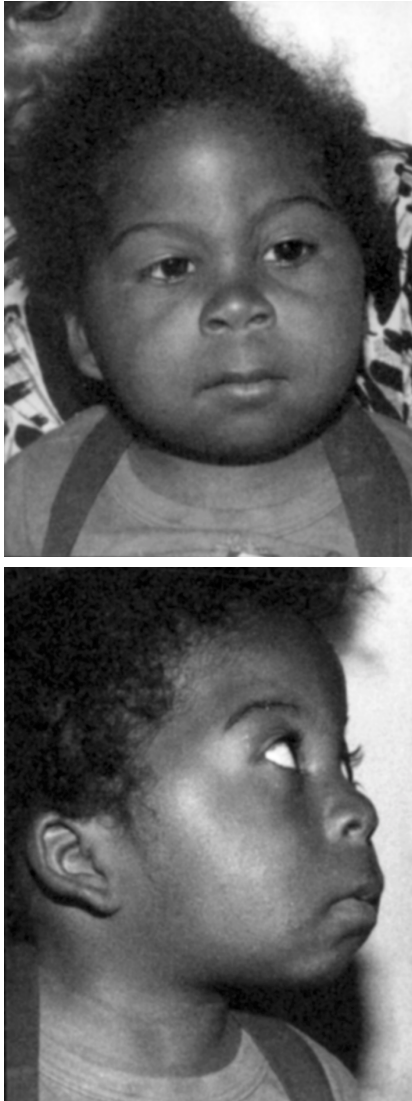

Figure 1 - Patient at the age of 6 years and 9 months.

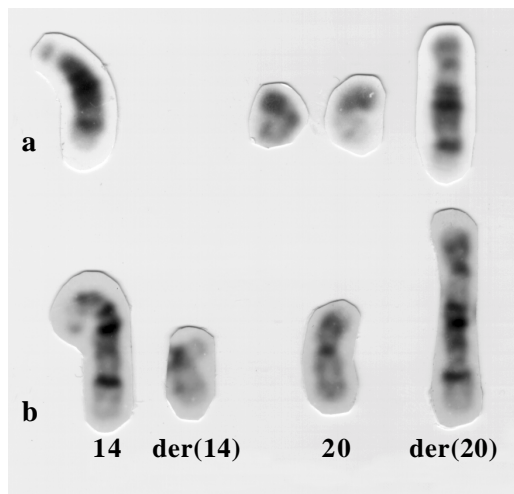


Figure 2 - Chromosomes 14 and 20 of (a) the patient with dup 20(pter→q12) and (b) her mother, carrier of the translocation $t(14;20)(q11.2;q13.1)$.

The karyotype of the child was $46,XX,-14,+der(20),t(14;20)(q11.2;q13.1)mat$, and she was diagnosed as having a duplication of the segment $20pter\rightarrow 20q12$ and a deletion of $14pter\rightarrow 14q11.1$.

DISCUSSION

The patient's karyotype was the result of a type 2 adjacent segregation of the translocation chromosomes and their homologues in maternal meiosis. The material lost from chromosome 14 comprised the short arm, centromere and a small pericentric segment of the long arm. The loss of such segments in Robertsonian translocations does not cause phenotypic abnormalities so that it is reasonable to assume that the patient's clinical picture was the result of chromosome 20 duplication ($20pter\rightarrow 20q12$).

The first report of a child with trisomy of chromosome 20 (Pan *et al.*, 1976) involved a neonate with unusual facial features and multiple congenital malformations who died 4 hours after birth. However, Steele (1990) reanalyzed the chromosomes from a frozen fibroblast culture and identified the extra chromosome as an isochromosome 12p. Indeed, based on the clinical findings, Schinzel (1980) had already suggested that this case represented partial trisomy of an autosomal segment with a banding pattern similar to that of chromosome 20. The same explanation would account for the other presumed trisomy of chromosome 20 reported by Wahlström *et al.* (1976) in a girl who had an abnormal appearance and cat's cry at birth, and later on showed poor weight gain and psychomotor retardation.

A presumptive 20p and partial 20q duplication was reported by Krmpotic *et al.* (1971), who were unable to precisely localize the breakpoint on the long arm. More recently, duplications of chromosome 20, involving the short arm and the proximal part of the long arm, have been identified by banding patterns (Marcus *et al.*, 1979, Rudd *et al.*, 1979, Schinzel, 1980; Delicado *et al.*, 1981). In these cases, the propositi had an extra-rearranged chromosome 20 that included small segments of other autosomes. The 20q duplication affected only the band 20q11 (Marcus *et al.*, 1979; Schinzel, 1980; Delicado *et al.*, 1981) or comprised part of 20q12 (Rudd *et al.*, 1979). Our patient had a larger duplication, that included at least the major part of band 20q12.

Table I summarizes the clinical signs of these patients. Most of these signs are associated with 20p duplication (for review, see Grammatico *et al.*, 1992). It is noteworthy that the two patients with the largest 20q duplications (Rudd *et al.*, 1979, and the present case) are the only individuals with severe growth retardation, microcephaly and broad distal phalanges of thumbs and toes.

ACKNOWLEDGMENTS

The authors thank Ms. Ligia S. Vieira for technical assistance. This work was supported by CNPq and CAPES. Publication supported by FAPESP.

Table I - Clinical signs in patients with dup20p and proximal dup20q.

	Present case	Rudd <i>et al.</i> (1979)	Marcus <i>et al.</i> (1979)	Schinzel (1980)	Delicado <i>et al.</i> (1981)
Duplication	20pter→20q12	20pter→20q12 dup(?)	20pter→20q11 12q24.3→qter	20pter→20q11 13p11→pter	20pter→20q11 11q25→qter
Deletion	14pter→14q11				
Sex	female	female	male	male	male
Age	3 6/12 years	13 weeks	13 months	2 10/12 years	6 months
Birth weight	2,450 g	2,553 g	2,640 g	2,500 g	3,330 g
Growth retardation	<3rd%	<3rd%	25th-30th%	50th%	?
Psychomotor retardation	+	+	+	+	+
Speech impediments	+	?	+	+	?
Head circumference	<2nd%	<3rd%	<50th%	3rd-10th%	?
Lateral depression of frontal bones	+	+	+	+	+
Prominent metopic sutures	+	?	+	-	?
Narrow forehead	+	+	+	-	?
Round face and full cheeks	+	+	+	+	+
Upslanted palpebral fissures	+	+	-	+	-
Convergent strabismus	+	-	-	-	-
Upturned tip of the nose/large nostrils	+	+	+	-	+
Elongated philtrum	+	+	+	+	+
Thin upper lip	+	-	+	+	-
Retrognathia/micrognathia	+	+	+	+	+
Highly arched palate	+	+	+	-	?
Low set ears	+	+	-	-	+
Short/broad neck	+	+	-	+	+
Broad distal phalanges of thumbs/toes	+	+	-	-	-
Rocker bottom feet	-	+	-	+	-
Prominent calcaneum	+	-	-	+	-
Overriding toes	-	+	-	+	-
Abnormal genitalia	-	+	+	+	+
Thoracic kyphosis	+	-	-	+	-

RESUMO

Descrevemos uma duplicação do cromossomo 20 (20pter→20q12), resultante de uma translocação t(14;20)(q11;q13)mat, em uma menina com retardo do desenvolvimento neuropsicomotor e anomalias congênitas múltiplas. Trata-se da mais extensa duplicação do cromossomo 20 presente em indivíduo nascido vivo até agora publicada.

REFERENCES

- Delicado, A., Lopez-Pajares, I., Vicente, P. and Gracia, R.** (1981). Partial trisomy 20. *Ann. Génét.* 24: 54-56.
- Grammatico, P., Cupilari, F., Di Rosa, C., Falcolini, M. and Del Porto, G.** (1992). 20p duplication as a result of parental translocation: familial case report and a contribution to the clinical delineation of the syndrome. *Clin. Genet.* 41: 285-289.
- Krmpotic, E., Rosenthal, I.M., Szego, K. and Bocian, M.** (1971). Trisomy F(?20). Report of a 14qF(?20) familial translocation. *Ann. Génét.* 14: 291-299.
- Marcus, E.S., Fuller, B. and Riccardi, M.** (1979). Triplication of chromosome arm 20p due to inherited translocation and secondary nondisjunction. *Am. J. Med. Genet.* 4: 47-50.
- Pan, S.F., Fatora, R., Haas, J.E. and Steele, M.W.** (1976). Trisomy of chromosome 20. *Clin. Genet.* 9: 449-453.
- Pawlowitzki, I.H., Grobe, H. and Holzgreve, W.** (1979). Trisomy 20q due to maternal t(16;20) translocation. First case. *Clin. Genet.* 15: 167-170.
- Rudd, N.L., Bain, H.W., Giblet, E., Chen, S.-H. and Worton, R.G.** (1979). Partial trisomy confirmed by gene dosage studies. *Am. J. Med. Genet.* 4: 357-364.
- Sanchez, O., Mamunes, P. and Yunis, J.J.** (1977). Partial trisomy 20 (20q13) and partial trisomy 21 (21pter-21q21.3). *J. Med. Genet.* 14: 459-462.
- Sax, C.M., Bodurtha, J.N. and Brown, J.A.** (1986). Case report: partial trisomy 20q (20q13.→qter). *Clin. Genet.* 30: 462-465.
- Schinzel, A.** (1980). Trisomy 20pter→q11 in a malformed boy from a t(13,20)(p11;q11) translocation-carrier mother. *Hum. Genet.* 53: 169-172.
- Steele, M.W.** (1990). Trisomy of chromosome 20/isochromosome 12p. *Clin. Genet.* 38: 79.
- Wahlström, J., Borsgard, Y. and Sabel, K.-G.** (1976). A case of trisomy 20? *Clin. Genet.* 9: 187-191.

(Received November 5, 1999)

