



Guidelines for diagnosis and treatment of Hunter Syndrome for clinicians in Latin America

Roberto Giugliani^{1,2,3}, Martha Luz Solano Villarreal⁴, C. Araceli Arellano Valdez⁵, Antonieta Mahfoud Hawilou⁶, Norberto Guelbert⁷, Luz Norela Correa Garzón⁸, Ana Maria Martins⁹, Angelina Acosta¹⁰, Juan Francisco Cabello¹¹, Aída Lemes¹², Mara Lucia Schmitz Ferreira Santos¹³ and Hernán Amartino¹⁴

¹*Serviço de Genética Médica, Hospital de Clinicas de Porto Alegre, Porto Alegre, RS, Brazil.*

²*Departamento de Genética, Universidade Federal do Rio Grande do Sul, Porto Alegre, RS, Brasil.*

³*Instituto Nacional de Genética Médica Populacional, Porto Alegre, RS, Brazil.*

⁴*Asociación Colombiana de Neurología Infantil, Bogotá, Colombia.*

⁵*Instituto Mexicano del Seguro Social, Guadalajara, Mexico.*

⁶*Instituto de Estudios Avanzados, Caracas, Venezuela.*

⁷*Hospital de Niños, Córdoba, Argentina.*

⁸*La Misericordia University Hospital, Bogotá, Colombia.*

⁹*Centro de Referência em Erros Inatos do Metabolismo, Universidade Federal de São Paulo, São Paulo, SP, Brazil.*

¹⁰*Universidade Federal de Bahia, Salvador, BA, Brazil.*

¹¹*Instituto de Nutrición y Tecnología de los Alimentos, Universidad de Chile, Santiago, Chile.*

¹²*Instituto de Genética Médica, Hospital Italiano, Montevideo, Uruguay.*

¹³*Departamento de Neuropediatra, Hospital Pequeno Príncipe, Curitiba, Paraná, Brazil.*

¹⁴*Hospital Universitario Austral, Buenos Aires, Argentina.*

Abstract

This review aims to provide clinicians in Latin America with the most current information on the clinical aspects, diagnosis, and management of Hunter syndrome, a serious and progressive disease for which specific treatment is available. Hunter syndrome is a genetic disorder where iduronate-2-sulfatase (I2S), an enzyme that degrades glycosaminoglycans, is absent or deficient. Clinical manifestations vary widely in severity and involve multiple organs and tissues. An attenuated and a severe phenotype are recognized depending on the degree of cognitive impairment. Early diagnosis is vital for disease management. Clinical signs common to children with Hunter syndrome include inguinal hernia, frequent ear and respiratory infections, facial dysmorphisms, macrocephaly, bone dysplasia, short stature, sleep apnea, and behavior problems. Diagnosis is based on screening urinary glycosaminoglycans and confirmation by measuring I2S activity and analyzing I2S gene mutations. Idursulfase (recombinant I2S) (Elaprase[®], Shire) enzyme replacement therapy (ERT), designed to address the underlying enzyme deficiency, is approved treatment and improves walking capacity and respiratory function, and reduces spleen and liver size and urinary glycosaminoglycan levels. Additional measures, responding to the multi-organ manifestations, such as abdominal/inguinal hernia repair, carpal tunnel surgery, and cardiac valve replacement, should also be considered. Investigational treatment options such as intrathecal ERT are active areas of research, and bone marrow transplantation is in clinical practice. Communication among care providers, social workers, patients and families is essential to inform and guide their decisions, establish realistic expectations, and assess patients' responses.

Keywords: Hunter syndrome, lysosomal disease, iduronate-2-sulfatase, enzyme replacement therapy, treatment guidelines.

Received: February 6, 2014; Accepted: March 26, 2014.

Introduction

This review summarizes the expertise of a multidisciplinary group of health professionals with extensive experience in Hunter syndrome; the aim is to provide clinicians in Latin America with the most current information on the clinical aspects, diagnosis, and management of Hunter syndrome, a serious and progressive disease for which specific treatment is available. This review is aimed at general practitioners and other specialists to promote clinical suspicion, early diagnosis, and timely initiation of appropriate therapeutic measures to help reduce the sequelae and irreversible damage that can occur in undetected Hunter syndrome.

Hunter Syndrome - Characteristics of the Disease

The mucopolysaccharidoses (MPSs) are inherited metabolic disorders caused by genetic defects that result in the absence or severe deficiency of one of the lysosomal hydrolases responsible for the degradation of glycosaminoglycans (GAGs). Part of the group of lysosomal storage disorders (LSDs), all MPSs are autosomal-recessive, with the exception of Hunter syndrome, or MPS II, which is an X-linked recessive disease (Neufeld and Muenzer, 2001).

Hunter syndrome is caused by a deficiency of iduronate-2-sulfatase (I2S, EC 3.1.6.13), which normally cleaves a sulfate group from the GAGs, heparan and dermatan sulfate. A shortage of I2S leads to an accumulation of undegraded GAGs within the lysosomes of various organs and tissues, including the central nervous system (CNS) (Neufeld and Muenzer, 2001). The abnormal deposition of GAGs alters the architecture and function of cells and tissues, resulting in dysfunction of multiple organs and systems, producing a broad spectrum of chronic and progressive clinical manifestations.

The estimated incidence of Hunter syndrome is between 0.69 and 1.19 per 100,000 live births (Alcalde-Martin *et al.*, 2010). In Latin America, no official data on the incidence of MPS diseases are available; however, a study in Portugal found that Hunter syndrome is one of the most prevalent LSDs in the Portuguese population (Pinto *et al.*, 2004; Ballabio and Gieselmann, 2009). Although this rare disorder is X-linked, thus occurring almost exclusively in males, Hunter syndrome has also been reported in a small group of female patients, manifesting with equal severity. The most common mechanism for disease expression in female patients is thought to involve the process of X-chromosome inactivation (Jurecka *et al.*, 2012). The *I2S* gene is located on chromosome X in the Xq28 region and, to date, more than 300 mutations have been described (Froissart *et al.*, 2002; Jurecka *et al.*, 2012). The identification of carriers through mutational studies is important for genetic counseling and prenatal diagnosis (Neufeld and Muenzer, 2001; Tuschl *et al.*, 2005).

Patients with Hunter syndrome experience a wide spectrum of progressive, multisystemic clinical symptoms. Age at presentation varies, as do the symptoms and progression of disease, and there are severe and attenuated manifestations. Symptoms in the first months of life are usually respiratory; in addition, patients often present with inguinal or umbilical hernia, short stature, coarse facies, macroglossia, and gingival hyperplasia. Patients also exhibit upper respiratory tract dysfunction and increased frequency of recurrent respiratory infections. Another common complication, which also occurs in other types of MPS, is sleep apnea. Skeletal involvement occurs early in Hunter syndrome and is characterized by dystosis multiplex, macrocephaly, abnormal first or second lumbar vertebra with kyphosis, barrel chest, and thickening of the long bone diaphyses. Progressive arthropathy leads to stiffness and contracture of large and small joints, with typical claw hands. Carpal tunnel syndrome is a frequently described complication. The abdomen may be prominent due to hepatosplenomegaly. All patients experience hearing loss, and deposition of GAGs in the heart leads to cardiomyopathy and valvular disease. In severe cases, death occurs in the first or second decade of life, usually due to obstructive respiratory disease or heart failure (Martin *et al.*, 2008; Wraith *et al.*, 2008b).

From a neurological perspective, approximately two-thirds of patients have psychomotor retardation, behavioral disturbances and neurological regression. In its attenuated forms, the clinical signs and symptoms of the disease appear later in life with minimal neurological dysfunction (Neufeld and Muenzer, 2001; Martin *et al.*, 2008; Beck, 2011; Guelbert *et al.*, 2011). These attenuated patients have normal intelligence and can survive into adulthood. In the severe, neuropathic form of Hunter syndrome, patients may have primary disease with parenchymal neural cognitive impairment due to deposition of GAGs in neural tissue and from other pathophysiologic neurotoxic and inflammatory disease mechanisms. Patients with non-neuropathic, attenuated disease may retain normal cognitive abilities yet develop secondary neurological conditions, such as cervical stenosis, carpal tunnel compression, and hydrocephalus, which result from the accumulation of GAGs rather than primary CNS disease (Holt *et al.*, 2011a,b).

Diagnosis and Work-Up

Timely diagnosis is the key to improving outcomes for patients with Hunter syndrome, and diagnosis involves the examination of disparate clinical factors, biochemical parameters, and molecular characteristics.

Clinical diagnosis

The clinical diagnosis of Hunter syndrome requires in the first instance a thorough patient medical and family history. Pediatricians are likely to be the first clinicians to

encounter a patient with Hunter syndrome, and there are a number of very early signs and symptoms that should arouse clinical suspicion, for example, lumbar gibbus, recurrent ear infections, hernia, myocarditis, or progressive hepatosplenomegaly may occur before the age of 6 months. Other signs and symptoms that are commonly found (Martin *et al.*, 2008) include the following:

- Facial dysmorphism: coarsening of facial features, broadened nose with flared nostrils, prominent supraorbital ridges, large jowls, thickened lips, enlarged protruding tongue
- Abdominal symptoms: hernia, abdominal distension due to enlarged liver and spleen
- Respiratory symptoms: recurrent upper airway infection, particularly affecting the ears; sleep apnea
- Skeletal and joint problems: dysostosis multiplex on radiographic examination, including abnormal bone thickening and irregular epiphyseal ossification in the joints of the hand, shoulder, and elbow; carpal tunnel syndrome.

Patients with Hunter syndrome often undergo surgical procedures at a young age, at times before diagnosis, so Hunter syndrome should be suspected in young children who have a history of surgical interventions, particularly for hernia or carpal tunnel syndrome (Mendelsohn *et al.*, 2010). Thorough documentation of the patient's surgical history is an important aspect of the clinical diagnosis of Hunter syndrome. Mendelsohn and colleagues compared surgical histories of patients with Hunter syndrome enrolled in the Hunter Outcome Survey (HOS), a global registry of patients with Hunter syndrome sponsored by Shire, with those of the general population and found that more than 80% of HOS-enrolled patients required surgical intervention and that 57% had undergone surgical intervention prior to Hunter syndrome diagnosis. These percentages are considerably higher than what is found in the general population (Mendelsohn *et al.*, 2010). A patient with a surgical history of hernia repair, tympanostomy, adenoidectomy, and carpal tunnel release should arouse suspicion and should suggest to the pediatrician that he or she should carefully evaluate the patient further for additional symptoms of Hunter syndrome. An extensive checklist of the signs and symptoms of Hunter syndrome is shown in Table 1 (adapted from the list used by HOS).

The signs and symptoms observed in Hunter syndrome vary according to disease severity, as do age of onset of presenting signs and disease complications (Wraith *et al.*, 2008b). Symptomatology in Hunter syndrome is best characterized as a continuum between two extremes, severe and attenuated. The clinical course is somewhat more predictable for patients with severe forms of the disease, whereas the clinical phenotype and progression of attenuated disease is considerably more variable. Individuals with attenuated disease may still develop symptoms and complications that lead to significant morbidity and disability. Manifestations of Hunter syndrome typically emerge

between 18 months and 4 years of age in patients with the severe phenotype, delayed by approximately 2 years in the attenuated phenotype (Muenzer *et al.*, 2009). Table 1 also shows the reported age at onset and prevalence of clinical features in patients with Hunter syndrome enrolled in HOS. Due to the often complex progression of symptoms, frequently there is a significant delay between the appearance of symptoms and the final diagnosis for MPS patients. Vieira and colleagues found in Brazil that there was an average delay of 4.8 years for all MPS diseases and it was even longer for Hunter syndrome. They also reported that, on average, patients were examined by 4.7 specialists before a diagnosis was reached (Vieira *et al.*, 2008). Although the signs and symptoms described Table 1 are very important in diagnosing Hunter syndrome, it is as important for the physician to recognize the pattern of symptoms that are characteristic of the disease as this is also a crucial part of the diagnostic process.

Biochemical diagnosis

Urinary GAG analysis

In most cases of MPS, the total urinary GAG (uGAG) level is elevated (Martin *et al.*, 2008). Excess GAGs in the urine indicate the likely presence of an MPS, but is not a definitive diagnostic test for Hunter syndrome, and other tests should be performed. Tests for uGAG analysis can be quantitative (*i.e.*, measurement of total uGAGs, usually with the dimethylene blue method (de Jong *et al.*, 1989) or qualitative (GAG electrophoresis or chromatography) (Wraith *et al.*, 2008b); however, uGAG testing methods are plagued by a lack of sensitivity and can present false-negative results (Martin *et al.*, 2008).

It is also important to note that uGAG testing, despite being relatively simple, is not available in all Latin American countries. This is an issue as the transport of urine samples across international borders can be challenging, potentially requiring long bureaucratic processes that could impair sample viability. Also, even if uGAG testing is available, it may not be covered by public or private health insurance plans.

Enzyme assay

If uGAG analysis reveals elevated dermatan and heparan sulfates, the definitive biochemical diagnosis of Hunter syndrome can be established through blood enzyme testing. Enzyme assays should be performed to determine deficiency of I2S enzyme activity in plasma leukocytes or fibroblasts (Wraith *et al.*, 2008b; Guelbert *et al.*, 2011; Scarpa *et al.*, 2011). Choice of assay depends on the testing facility, but leukocytes are usually preferred when available (Martin *et al.*, 2008). Analysis of dried blood spots on filter paper is an especially useful screening tool, particularly in areas where transport of cells or serum samples is challenging (Civallero *et al.*, 2006; Dean *et al.*, 2006; Martin *et al.*, 2008).

Molecular diagnosis

Although not usually needed to establish a diagnosis, molecular genetic testing of the *I2S* gene may be useful

(Scarpa *et al.*, 2011). More than 300 mutations of the *I2S* gene have been described (Froissart *et al.*, 2002; Jurecka *et al.*, 2012). A detailed pedigree analysis should be completed if an *I2S* gene mutation is identified, and genetic

Table 1 - Major signs and symptoms of Hunter syndrome. Adapted from (Wraith *et al.*, 2008a,b; Keilmann *et al.*, 2012).

Organ system/anatomical region	Signs and symptoms	Prevalence (%)	Median age of onset (y)
Head and neck	Facial features consistent with Hunter syndrome (facial dysmorphism, coarse facies, macrocephalus, hydrocephalus)	95	2.4
Eye	Papilledema	-	
	Retinal degeneration	-	
Mouth	Enlarged tongue (macroglossia)	70	3.4
Ear	Otitis media	72	1.9
	Ventilation tubes	50	3.5
	Hearing loss	67	4.8
	Hearing aids	41	6.6
	Tinnitus	2	13.3
	Vertigo	3	14.6
	Nose	Nasal obstruction	34
	Rhinorrhea	-	
Throat	Enlarged tonsils/adenoids	68	2.9
Chest/lungs	Dyspnea	-	
	Chronic cough/bronchitis	-	
	Sleep apnea	-	
	Difficulty with intubation/inability to intubate	-	
Cardiovascular	Murmur	62	5.8
	Arrhythmia	4	6.3
	Tachycardia	7	11.3
	Bradycardia	2	13.9
	Hypertension	6	11.4
	Cardiomyopathy	8	4.8
	Congestive heart disease	4	8.9
	Valve disease	57	6.1
	Myocardial infarction	0.5	44.9
	Peripheral vascular disease	2	9.3
Gastrointestinal	Abdominal hernia	78	1.3
	Hepatosplenomegaly	89	2.8
	Diarrhea	-	
Skin	Hunter lesions (<i>i.e.</i> , pebble lesions)	-	
Skeletal	Joint stiffness and limited function/contracture	84	3.6
	Kyphosis/scoliosis	39	5.0
Neurological	Hydrocephalus	17	5.8
	Seizures	18	9.3
	Swallowing difficulties	27	8.9
	Carpal tunnel syndrome	25	7.9
	Impaired fine motor skills	33	4.0
	Hyperactivity	31	3.5
	Frequent chewing	13	6.8
	Cognitive problems	37	3.2
	Behavioral problems	36	3.7

counseling should be offered to all family members (Guelbert *et al.*, 2011; Scarpa *et al.*, 2011). A distal pseudogene (*IDS2*) containing highly homologous sequences is found downstream of the *IDS* gene. This can complicate molecular analysis and for this reason genomic DNA sequencing is often followed by cDNA analysis (Scarpa, 2011).

Identification of an *IDS* gene mutation in affected patients can facilitate (Guelbert *et al.*, 2011):

- Precise molecular diagnosis
- Identification of female carriers
- Initiation of genetic counseling
- Timely and precise prenatal diagnosis
- Evaluation of genotype-phenotype correlations.

Prenatal testing allows for early and rapid diagnosis of affected fetuses and is available via enzyme assay of *IDS* in uncultured chorionic villi sampling at 11 weeks' gestation, or by amniocentesis at 16 weeks. Preimplantation genetic diagnosis can identify affected embryos in at-risk pregnancies. Prenatal enzymatic assays are of two types: (1) enzyme assay of *IDS* in all at-risk pregnancies when mutation is not known, and (2) molecular study when the mutation is known. Chromosomal testing for fetal sex determination should be conducted in conjunction with enzymatic assays (Wraith *et al.*, 2008b; Guelbert *et al.*, 2011). Figure 1 shows a diagnostic algorithm for Hunter syndrome.

Basic Clinical Evaluation and Management

Upon diagnosis of Hunter syndrome, the clinical evaluation endeavors to determine the severity of disease and the extent of multisystem involvement. Table 2 reviews the relevant assessments for patients diagnosed with Hunter syndrome. As the clinical manifestations of Hunter syndrome are multisystemic, a multidisciplinary approach is required to proactively recognize and manage complications (Muenzer *et al.*, 2009; Guelbert *et al.*, 2011). The multidisciplinary care team should include specialists as appropriate to meet each individual patient's needs. Routine assessment of the various affected organs and systems is necessary, and each specialist in the multidisciplinary team should oversee continuing evaluations once a clinical problem is identified. This helps to optimize the quality of life for patients and their families (Muenzer *et al.*, 2009; Guelbert *et al.*, 2011). Figure 2 shows images of two Hunter syndrome children, one with a severe, and one with an attenuated phenotype.

Neurological

CNS complications in patients with Hunter syndrome can include seizures, spinal cord compression with resulting cervical myelopathy, and hypertrophic pachymeningitis cervicalis. Standard anticonvulsant treatment can be administered for tonic-clonic seizures (Holt *et al.*, 2011a; Scarpa *et al.*, 2011). Failure to treat cervical myelopathy can result in irreversible cord damage; thus, when symp-

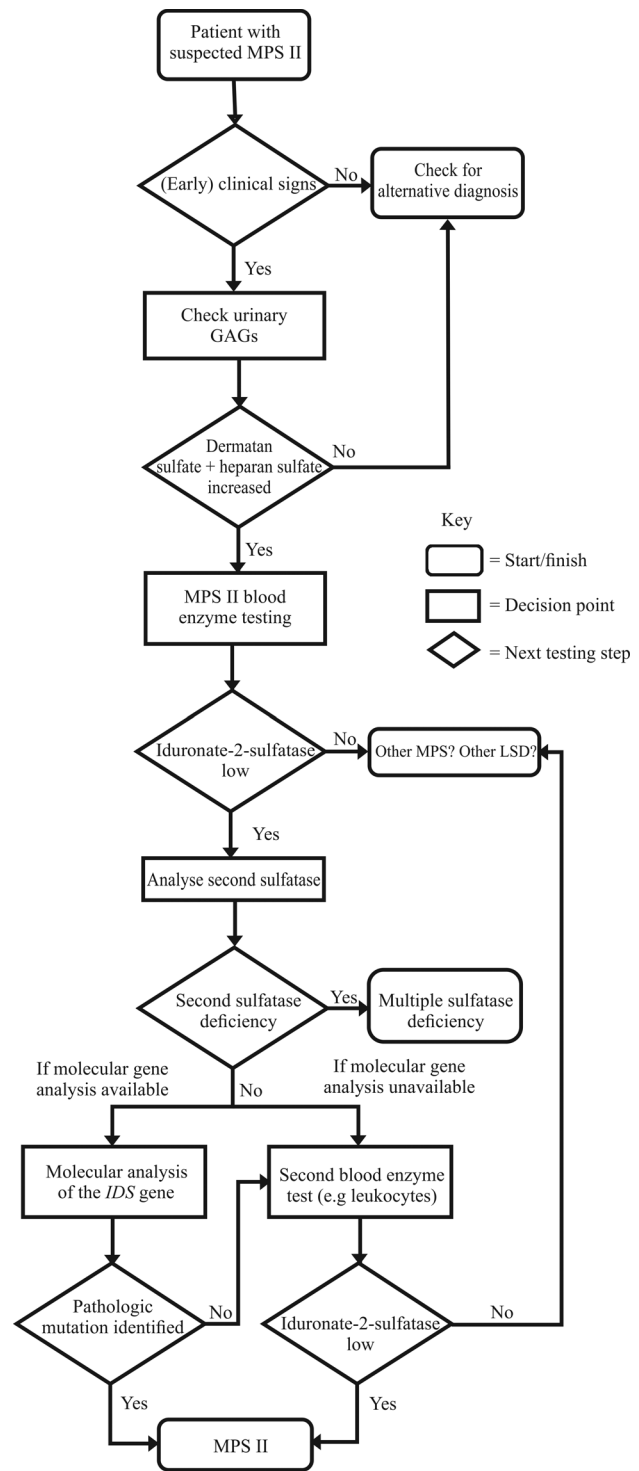


Figure 1 - Diagnostic algorithm for Hunter syndrome. From (Scarpa *et al.*, 2011, copyright © 2011, BioMed Central Ltd.). GAGs, glycosaminoglycans; LSD, lysosomal storage disorder; MPS, mucopolysaccharidosis.

toms manifest, prompt, careful cervical decompression should be performed by an experienced team to help avoid severe neurological consequences (Wraith *et al.*, 2008b; Scarpa *et al.*, 2011). Early aggressive treatment is indicated in patients with attenuated disease who have hypertrophic pachymeningitis cervicalis and cervical compression

secondary to hyperplasia of the transverse ligaments. Particular care should be taken to prevent cord compression during general anesthesia (Muenzer *et al.*, 2009).

Carpal tunnel syndrome, a common peripheral nervous system complication in patients with attenuated forms of the disease, warrants prompt evaluation and treatment.

Frequently it is not easy to determine if the patient is experiencing pain from carpal tunnel syndrome and it can also represent an underlying cause of behavioral problems in patients with Hunter syndrome. As noted in Table 2, nerve conduction studies should be undertaken in patients at 4-5 years of age and every 1-2 years thereafter (Muenzer *et al.*,

Table 2 - Suggested evaluations for patients with Hunter syndrome. Adapted from (Wraith *et al.*, 2008b; Muenzer *et al.*, 2009; Guelbert *et al.*, 2011).

Organ System/involvement	Assessment	Frequency recommendation ^a
Neurological		
General	<ul style="list-style-type: none"> • Neurophysiologic exams • EEG 	Yearly
Hydrocephalus	<ul style="list-style-type: none"> • MRI/CT of the head +/- gadolinium • LP measurement of CSF pressure 	Every 1-3 years
Spinal cord compression	<ul style="list-style-type: none"> • MRI cervical spine 	Every 1-3 years
Atlantoaxial instability	<ul style="list-style-type: none"> • Cervical spine flexion/extension 	Every 2-3 years, and before general anesthesia
Progressive cognitive involvement	<ul style="list-style-type: none"> • Neurobehavioral 	Yearly
Carpal tunnel syndrome	<ul style="list-style-type: none"> • Nerve conduction • Hand function tests 	At 4-5 years old, then at 1- or 2-year intervals Yearly
Cardiovascular		
Myocardiopathy Valvular dysfunction	<ul style="list-style-type: none"> • ECHO/ECG • Holter (conduction irregularities) 	Yearly
Auditory	<ul style="list-style-type: none"> • Otologic and audiologic • Audiometry • Phonoaudiology 	Every 6-12 mo
Respiratory	<ul style="list-style-type: none"> • Pulmonary function <ul style="list-style-type: none"> ◦ Chest x-ray ◦ Oxygen saturation ◦ Sleep study to detect OSA ◦ 6MWT ◦ 3-minute stair climbing test • Sleep study • Bronchoscopy 	Upon diagnosis or when patient is old enough to cooperate, then yearly Every 3-5 years, then upon suspicion of OSA As necessary to evaluate pulmonary involvement or in preparation for general anesthesia
Musculoskeletal	<ul style="list-style-type: none"> • JROM • Bone mapping, radiograph of <ul style="list-style-type: none"> ◦ Spine and hip ◦ Thoracic ◦ Hands ◦ Long bones 	Yearly Upon diagnosis and thereafter in response to signs and symptoms
Ophthalmologic	<ul style="list-style-type: none"> • Standard ophthalmologic examination <ul style="list-style-type: none"> ◦ Visual acuity ◦ Visual field ◦ Biomicroscopy ◦ Intraocular pressure ◦ Electroretinography 	Yearly
Psychiatric	<ul style="list-style-type: none"> • Clinical evaluation • Psychosocial/environmental evaluation 	According to clinical judgment
Dental	<ul style="list-style-type: none"> • Standard dental care 	Every 6 mo
Abdominal		Every examination Every examination
Inguinal hernia	<ul style="list-style-type: none"> • Clinical evaluation 	
Hepatosplenomegaly	<ul style="list-style-type: none"> • Clinical evaluation 	

^aRecommendations upon diagnosis, and thereafter as indicated.

6MWT, 6-minute walk test; CSF, cerebrospinal fluid; CT, computed tomography; ECG, electrocardiogram; ECHO, echocardiogram; EEG, electroencephalography; JROM, joint range of motion; LP, lumbar puncture; MRI, magnetic resonance imaging; OSA, obstructive sleep apnea.

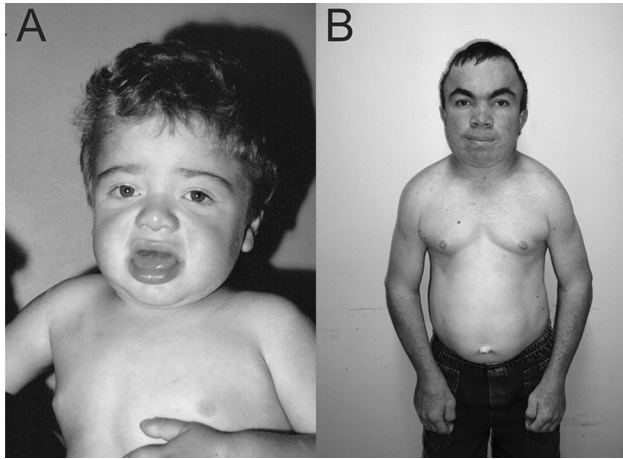

Figure 2 - Children with Hunter syndrome. A: a 2-year-old with a severe phenotype; B: an adult male with an attenuated phenotype.

2009). In most patients, surgical decompression of the median nerve at an early stage of involvement results in partial or complete improvement (Wraith *et al.*, 2008b).

Cardiovascular

Cardiac valve replacement surgery may be needed in some patients with Hunter syndrome, and monitoring is essential through annual cardiac evaluations that include echocardiograms (ECHO) and/or electrocardiograms (ECG). Prophylaxis for bacterial endocarditis should be administered when indicated (Wraith *et al.*, 2008b). The current standard of cardiac care for MPS focuses on pharmacological intervention for heart failure and cardiac surgery. Recent studies in patients with MPS suggest that systemic therapies, such as ERT, may improve cardiovascular clinical outcomes in patients with Hunter syndrome, particularly in patients who receive early intervention (Guffon *et al.*, 2009; Prasad and Kurtzberg, 2010; Braunlin *et al.*, 2011).

Ophthalmic

As with other aspects of Hunter syndrome, early recognition and treatment of ophthalmic complications are critical. Deposition of GAGs within retinal pigment epithelial cells and in the interphotoreceptor matrix results in retinopathy, which leads to progressive photoreceptor loss, and retinal degeneration and dysfunction (Ferrari *et al.*, 2011). Glaucoma is rarely present (Wraith *et al.*, 2008b) but if detected should be treated promptly (Guelbert *et al.*, 2011). Patients should undergo annual ophthalmological evaluations that include measurement of intraocular pressure; corrective lenses should be prescribed as appropriate (Wraith *et al.*, 2008b).

Audiologic

Because hearing loss is nearly universal in Hunter syndrome, the use of hearing aids is an important aspect of

disease management (Muenzer *et al.*, 2009; Keilmann *et al.*, 2012). Hearing loss can contribute to behavioral problems and learning difficulties. Patients who experience hearing loss can become socially disconnected when hearing aids are not used. The resulting behavioral effect is similar to that observed in autism spectrum disorders.

Chronic otitis media is a common feature of Hunter syndrome and contributes to conductive hearing loss. Routine otologic and audiologic evaluations should be performed at least every 6-12 months, and recurrent ear infections should be treated as appropriate. In patients with hearing loss secondary to persistent middle ear effusion, clinicians should discuss the use of hearing aids and/or myringotomy with placement of ventilating tubes to improve hearing (Peck, 1984; Muenzer *et al.*, 2009). The use of hearing aids is encouraged, and both treatments are effective, but hearing aids are preferred for children with significant comorbidities (Muenzer *et al.*, 2009; Scarpa *et al.*, 2011).

Dental

Standard dental care is recommended whenever possible in patients with Hunter syndrome, with evaluation every six months (Muenzer *et al.*, 2009). Due to the limited maximum opening of the jaw, routine dental procedures may be difficult, and some will require general anesthesia, which poses particular risks in patients with Hunter syndrome. Delayed dental eruption has been reported, particularly with the first permanent molars. This is thought to be associated with areas of bone involvement that resemble dentigerous cysts (Liu, 1980; Muenzer *et al.*, 2009). Moreover, surgical procedures may be difficult due to anatomic alterations caused by the disease.

Respiratory

Episodes of significant hypoxia should be managed through use of continuous or bilevel positive airway pressure devices. However, in severely affected patients who do not tolerate this treatment, supplemental oxygen alone may be an acceptable alternative. In patients with documented hypercapnia, supplemental oxygen should be used with caution (Wraith *et al.*, 2008b). Tonsillectomy and adenoidectomy are often performed to correct Eustachian tube dysfunction and to decrease airway obstruction. Severely affected patients also tend to have frequent ear infections and constant rhinorrhea; therefore, early placement of ventilating tubes is recommended (Wraith *et al.*, 2008b; Guelbert *et al.*, 2011). Pathological changes and obstruction in the upper airways, in addition to the short neck and jaw immobility seen in patients with Hunter syndrome makes general anesthesia a high risk procedure. It is therefore good practice to consider local or regional anaesthesia where possible (Scarpa *et al.*, 2011).

Gastrointestinal

Abdominal hernias should be corrected surgically. Diarrhea can be managed with diet and antimotility drugs (Wraith *et al.*, 2008b; Guelbert *et al.*, 2011). According to 2005 World Health Organization guidelines, home therapy to prevent dehydration and manage diarrhea includes intake of plain water and electrolyte solutions. Commercial carbonated beverages, fruit juices, sweetened tea, coffee, and medicinal teas should be avoided. As patients with Hunter syndrome age, physical inactivity and loss of muscle strength can result in constipation. Constipation can be managed through adequate hydration, and dietary and behavior modification. Oral laxative medications to treat constipation include high-dose mineral oil, polyethylene glycol electrolyte solutions, or a combination of both. Other options include high-dose magnesium citrate, magnesium hydroxide, sorbitol, lactulose, senna, or bisacodyl (Greenwald, 2010).

Musculoskeletal/orthopedic

Orthopedic complications can lead to significant disability (Wraith *et al.*, 2008b). Data from HOS showed that 79% of enrolled patients had skeletal manifestations and 25% had abnormal gait. Furthermore, joint range of motion (JROM) was restricted for all joints assessed, which included elbow, shoulder, hip, knee, and ankle (Link *et al.*, 2010). Destructive arthropathy is debilitating and quite difficult to manage (Guelbert *et al.*, 2011). Although the role of physical therapy in Hunter syndrome is not well studied, JROM exercises may offer some benefit and should be started at an early age to preserve joint function and to slow progression in patients with significant restriction of joint movement (Wraith *et al.*, 2008b).

Additional assessments

Additional assessments include evaluations of development (*e.g.* Denver II, Developmental Quotient, Intelligence Quotient *etc.*), function, independence, and daily activities. In Latin America, the FIM (Functional Independence Measure) and PEDI (Pediatric Evaluation of Disabilities Inventory) scales can be employed. The 6-minute walk test (6MWT) (American Thoracic Society, 2002) should be performed upon diagnosis and every 6-12 months depending on treatment regimen.

The multidisciplinary care team may also include other specialists, such as a dietician for nutritional support, speech language pathologists/audiologists, psychotherapists, and physiotherapists. It is also important to highlight the role of patient and family support groups and associations that can often provide good practical advice and emotional support.

Treatments

Enzyme replacement therapy

Enzyme replacement therapy (ERT) with recombinant human I2S (idursulfase) is available for patients with Hunter syndrome. The US Food and Drug Administration and the European Medicines Agency approved idursulfase for treatment of patients with Hunter syndrome based on results of a pivotal phase 2/3 randomized, double-blind, placebo-controlled clinical trial in 96 patients with Hunter syndrome aged 5-31 years (Muenzer *et al.*, 2006). The primary endpoint of the study was a two-component composite of the 6MWT and predicted forced vital capacity (FVC). After 53 weeks, patients receiving a weekly regimen of idursulfase experienced a statistically significant mean 44.3-m (± 12.3 m) improvement in the 6MWT compared to patients receiving placebo, who experienced a mean improvement of 7.3 m (± 9.5 m) ($p = 0.0131$). Those on weekly idursulfase also showed a mean improvement of 3.45% ($\pm 1.77\%$) in predicted FVC compared to 0.75% ($\pm 1.71\%$) for those on placebo ($p = 0.065$), and a mean 220-mL (± 50 mL) increase in absolute FVC, compared to 60 mL (± 30 mL) for those on placebo ($p = 0.0011$). In addition, patients treated with idursulfase experienced improvements in liver and spleen volume and in uGAG excretion. In general, treatment with idursulfase was well tolerated; however, infusion-related reactions did occur (experienced by 69% of patients on idursulfase and 66% of patients on placebo). The risk of infusion related reactions appears to be greatest in the first six months of treatment (Miebach, 2009). Anaphylactoid reactions, which have the potential to be life threatening, have been observed in some patients. Idursulfase is administered weekly as an intravenous (IV) infusion at a dose of 0.5 mg/kg (Shire Human Genetic Therapies, 2011). As idursulfase does not cross the blood-brain barrier, the challenges of treating the neurological features of Hunter syndrome remain.

Criteria for ERT

Despite the approved guidelines that state that ERT should be offered to all patients older than five years with an attenuated phenotype, Latin American specialists who have experience with treatment are increasingly convinced that ERT should be started as early as possible. A recent study has demonstrated that in 28 boys, aged 1.4-7.5 years, idursulfase safety and tolerability was similar to that previously reported in males older than five years (Giugliani *et al.*, 2013). Indeed, ERT should be considered for all symptomatic heterozygous patients who may benefit from therapy, as supported by evidence from clinical trials (6MWT, reduction of organomegaly, respiratory improvement) and case reports. In patients with the severe phenotype and evidence of significant cognitive degeneration, the decision to initiate ERT rests with the treating clinicians, the institution's ethics committee, and the patient's family (Guelbert

et al., 2011). An expert panel consensus, commenting on the role of ERT in patients with severe Hunter syndrome, stated that “all previously diagnosed, symptomatic patients in whom there is an expectation that ERT will alter the course of the somatic involvement are also candidates for a trial of idursulfase treatment, even if cognitive impairment is already evident” (Muenzer *et al.*, 2012). In discussion with government and health authorities when making decisions in the absence of robust scientific evidence, experienced physicians can provide useful advice to aid a final decision.

Female patients with Hunter syndrome show attenuated and severe phenotypes, and disease progression shows a similar clinical course and prognosis as for male patients; criteria for treatment is the same as for males. Although data are extremely limited, results from case studies suggest that ERT may help to stabilize the progression of disease in female patients (Jurecka *et al.*, 2012).

When to initiate ERT

Initiation of ERT should occur as early as possible. Patients aged ≤ 5 years were not included in the pivotal trials of ERT with idursulfase (Muenzer *et al.*, 2006, 2007), but results from a recent study demonstrate that ERT is similarly safe in children younger than five years compared to those older than five years (Giugliani *et al.*, 2013). A recent consensus statement underscores the need for timely individualized treatment. In patients with an attenuated phenotype, the expert panel noted the importance of considering ERT, even if the rate or severity of cognitive decline is not yet apparent (Muenzer *et al.*, 2012).

Benefits of early treatment with ERT

The benefit of early intervention with ERT is supported by data from recent studies. Alcalde-Martín and colleagues analyzed HOS data from 6 patients with Hunter syndrome who were younger than five years at ERT initiation (Alcalde-Martín *et al.*, 2010). All patients showed neurological abnormalities at baseline. After eight months of weekly ERT, results showed reduced uGAG levels and reduced spleen ($n = 2$) and liver size ($n = 1$). In addition, growth (height) was maintained within the normal range during ERT, and joint mobility either stabilized or improved. Safety findings were similar to those observed in older patient populations. A case report from Poland suggests the possibility that early initiation of ERT may markedly slow or prevent the development of some irreversible manifestations of Hunter syndrome, including coarse facial features, joint disease, and cardiac function (Tylki-Szymanska *et al.*, 2012).

Schulze-Frenking and colleagues, conducting a retrospective analysis of patients with attenuated phenotype Hunter syndrome who were enrolled in a clinical trial to determine effects of ERT on linear growth, noted that ERT appeared to have a positive influence on growth. The great-

est benefit was observed in patients beginning ERT before age 10 years, supporting the recommendation that ERT should be started as early as possible (Schulze-Frenking *et al.*, 2011).

Muenzer and colleagues evaluated 124 patients aged < 6 years enrolled in HOS. The mean age at start of ERT was 3.6 ± 1.6 years, with a mean duration of treatment of 22.9 ± 14.6 months. After at least six months of ERT with idursulfase, mean uGAG levels decreased from $592 \pm 188 \mu\text{g}/\text{mg}$ to $218 \pm 115 \mu\text{g}/\text{mg}$ creatinine ($p < 0.0001$, $n = 34$). Furthermore, liver size, as estimated by palpation, also decreased significantly ($p = 0.005$, $n = 23$). No new safety concerns were noted in patients younger than six years (Muenzer *et al.*, 2011).

In a recent, open-label, study that evaluated safety and clinical outcomes in 28 boys aged 1.4 to 7.5 years, the safety of idursulfase ERT over one year was observed to be similar to that previously reported in the 2006 pivotal trial. Exploratory outcomes showed that, at week 18, mean normalized uGAG had decreased 49.2% compared to baseline values, and mean index of liver size and spleen volumes decreased by 20.1% and 23.3%, respectively. These reductions were largely maintained through to week 53 (week 53 decreases vs. baseline were 54.4%, 17.4%, and 20.6% for mean normalized uGAG, index of liver size, and spleen volume, respectively) (Giugliani *et al.*, 2013).

Communicating with patients' families

Effective communication with patients' families is essential. Although ERT may have benefits for many patients, treatment of patients with severe CNS involvement remains problematic. Clinicians should communicate clearly with patients' families regarding the limitations of ERT. Moreover, clinicians must help families of patients with severe forms of the disease establish realistic expectations, as these expectations may influence the decision of whether or not to initiate ERT. Communication with the family is also important in assessing the patient's response to ERT; an improvement in quality of life as perceived by the family should be considered a benefit of treatment in patients with severe disease (Muenzer *et al.*, 2012). Patient/family associations and support groups can be particularly important in helping families obtain realistic expectations for ERT, as families' hopes are frequently much greater than the likely benefit from ERT.

Monitoring of patients receiving ERT

In patients receiving ERT, it is important to monitor uGAG levels, as well as the patient's weight to maintain the standard idursulfase dose of 0.5 mg/kg, to evaluate treatment and patient response to treatment. These and other assessments for patients receiving ERT are listed in Table 3. In patients who are not candidates for ERT (due to advanced disease, pregnancy/lactation, or other significant comorbidities), assessments should be conducted as shown

Table 3 - Monitoring of patients with Hunter syndrome aged ≥ 5 years receiving ERT. Adapted from (Wraith *et al.*, 2008b; Muenzer *et al.*, 2009; Guelbert *et al.*, 2011).

Organ system/involvement	Assessment	Recommendation ^a
Medical history	Clinical evaluation, including developmental milestones	Every 6 mo
Physical examination	Clinical evaluation, including height, weight, head circumference, BP, neurological examination	Every 6 mo
Infections/surgeries	Clinical evaluation	Every 6 mo
Neurological	Cognitive assessment	Every 12 mo
Cardiovascular	Echocardiogram, ECG	Every 12 mo
Pulmonary	Spirometry	Every 12 mo
Musculoskeletal	JROM	Every 12 mo
	6MWT	Every 6 mo
General	ERT status: start date, dosage, any missed infusions	Every 6 mo
	uGAG level	Every 6 mo
	Antibody testing	Prior to ERT start, then every 6 mo

^aConduct upon enrollment, and monitor thereafter, as indicated.

6MWT, 6-minute walk test; BP, blood pressure; ECG, electrocardiogram; ERT, enzyme replacement therapy; uGAG, urinary glycosaminoglycan; JROM, joint range of motion.

in Table 2 (Wraith *et al.*, 2008b; Muenzer *et al.*, 2009; Guelbert *et al.*, 2011).

Management of ERT infusion-site reactions

Idursulfase is administered intravenously at 0.5 mg/kg per week (Shire Human Genetic Therapies, 2011). Clinicians administering ERT to patients with Hunter syndrome, either in the clinic or at home, should be familiar with the timing, nature, and recommended management of infusion-associated reactions (Burton *et al.*, 2010). Two types of infusion-site reactions have been documented: those occurring during the infusion and those occurring ≥ 12 h after the infusion (Wraith *et al.*, 2008b). Most infusion-site reactions occur during the first three months of treatment; however, in rare cases, infusion-site reactions have occurred after more than six months of ERT (Burton and Whiteman, 2011).

In an analysis of data from the HOS, researchers noted that most infusion-site reactions were mild to moderate in severity (Burton and Whiteman, 2011). Typical reactions during infusion include fever, chills, and urticaria, which can be managed by temporarily stopping the infusion, administering acetaminophen and antihistamines, and restarting the infusion at a slower rate after 30 min or longer (Wraith *et al.*, 2008b; Burton and Whiteman, 2011). At subsequent ERT infusions, the treating physician may decide to premedicate the patient with acetaminophen and antihistamines one hour prior to infusion. In patients who experience reactions despite premedication, pretreatment with corticosteroids should be considered (Wraith *et al.*, 2008b).

Reactions occurring ≥ 12 h after the infusion typically consist of a sunburn-like rash and mild wheezing. Rash can be managed with acetaminophen and antihistamines and/or

corticosteroids. Management of wheezing requires treatment with bronchodilators and, possibly, oxygen supplementation (Wraith *et al.*, 2008b).

Analysis of HOS data detected immunoglobulin G (IgG) antibodies to idursulfase in 51% of patients on ERT (Burton and Whiteman, 2011) and analysis of the pivotal II/III data has also showed that about half of patients (attenuated phenotype, five years or older) developed IgG antibodies, with about a third becoming persistently antibody positive, and one fifth developing neutralizing antibodies. Infusion-associated reactions were about twice as likely to occur in those patients who become antibody positive on treatment, but most of the risk for reactions occurs before the antibodies have developed, so this data leads to no modifications to the guidelines for management of infusion-associated reactions (Barbier *et al.*, 2013).

ERT home therapy

Most patients receive ERT infusions at dedicated treatment centers. However, lack of transportation, missing school and work, and living in remote areas may present significant challenges for patients and their families. Studies have shown that receiving infusions at home can be beneficial in terms of reducing stress, improving adherence, providing greater convenience, and having less impact on family life (Milligan *et al.*, 2006; Burton *et al.*, 2010; Scarpa *et al.*, 2011).

In general, home infusion of idursulfase may be considered for patients who have received several months of treatment in the clinic and who are tolerating their infusions well. More details of the considerations required for home treatment are shown in Table 4. Regular administrations are usually performed by a nurse (Burton *et al.*, 2010). In some Latin American countries home therapy is already in

Table 4 - Minimum requirements for transfer of patients to ERT home therapy. Adapted from (Burton *et al.*, 2010).

Patients
<ul style="list-style-type: none"> • Well established on idursulfase therapy • Free of infusion-associated reactions • Aged 2 years or older • Stable airway disease^a • Established IV access
Family
<ul style="list-style-type: none"> • Should be made aware of relative risks/benefits of home therapy
Home Care Team
<ul style="list-style-type: none"> • Meet patient prior to transfer • Assess home environment prior to patient transfer • Skilled in giving infusions and managing infusion-associated reactions • Experienced in management of patients with LSDs • Family doctor should be informed of patient transfer to ERT home therapy

^aHome treatment is contraindicated in patients with respiratory infections or other current illnesses. ERT, enzyme replacement therapy; IV, intravenous; LSDs, lysosomal storage disorders.

operation and patients are receiving treatment at home. Home therapy is usually more challenging in Latin America than in developed countries as home care teams are scarce or not available in many countries, and patients' home conditions may not be suitable for safe storage of drugs or for performing infusions.

Patients younger than five years receiving ERT

Recommendations for follow-up in patients aged ≤ 5 years mirror those for older patients. Special care should be taken in monitoring since age-related challenges could arise that require adaptations to the monitoring regimen.

Continued monitoring of routine developmental milestones is required to determine the long-term effects of idursulfase on linear growth and weight (Alcalde-Martin *et al.*, 2010). Monitoring of GAG levels in urine is important because available data and clinical observations suggest that uGAG levels are higher in young patients (aged less than five or six years) with Hunter syndrome compared with older patients (Muenzer *et al.*, 2011).

A particular challenge when monitoring very young patients with Hunter syndrome is that functional testing requires their cooperation, especially when assessing pulmonary function or mobility (Muenzer *et al.*, 2011). Thus, in children aged ≤ 5 years, interpreting data from JROM tests and determining reliability can be difficult; the 6MWT may not be performed consistently, making evaluation of results problematic; and pulmonary spirometry can be difficult to perform and interpret if a child chooses not to cooperate. Furthermore, difficulties exist with respect to abdominal imaging in very young children, making it hard to deter-

mine improvements in organomegaly (Alcalde-Martin *et al.*, 2010).

When to stop or suspend ERT

In general, ERT should be discontinued or suspended in the following circumstances (Guelbert *et al.*, 2011):

- Severe or advanced disease that does not improve with ERT
- Severe infusion-associated reactions that cannot be managed with recommended premedication
- Life-threatening comorbidities (review on a case-by-case basis)
- Pregnancy/breastfeeding
- Incurable disease unrelated to Hunter syndrome (e.g., terminal cancer)

In patients with severe Hunter syndrome, discontinuation of ERT should be considered in the following circumstances (Muenzer *et al.*, 2012):

- After a trial of at least 6-12 months if no benefit is evident. Note that improvement in quality of life as perceived by the patient's family should be considered a benefit of treatment
- Exacerbated behavioral difficulties as a result of ERT
- Neurological decline progressing to a severe degree

Other Treatment Options

Transplantation

Although hematopoietic stem cell transplantation (HSCT) has been successful in modifying the course of disease in patients with other LSDs (*i.e.*, MPS I and MPS VI), data in the literature do not seem to support the benefits of HSCT for Hunter syndrome (Vellodi *et al.*, 1992, 1999; Wraith *et al.*, 2008b). Similarly, data on bone marrow transplantation and umbilical cord blood transplantation (UCBT) are scarce and based on published individual case studies or small case series (Scarpa *et al.*, 2011). Research continues into novel treatment approaches, such as micro-transplantation.

In Latin America there are particular challenges due to the difficulty of finding donors (insufficient donor registries) and obtaining timely transplantations. There is also a lack of experience in many bone marrow transplantation/HSCT centers in dealing with patients with metabolic diseases.

Ongoing Research

Intrathecal ERT and fusion proteins to overcome the blood-brain barrier

Research seeks to address the challenges of treating the neurological complications of Hunter syndrome, with a focus on developing well-tolerated therapies that can cross the blood-brain barrier. Investigational experiments in

animal models of LSDs, including Hunter syndrome, have shown that ERT with a different formulation of idursulfase to that used in conventional ERT delivered via the intrathecal route distributes throughout the CNS, penetrates brain tissue, and promotes clearance of lysosomal storage material (Dickson, 2009). Clinical trials are currently investigating intrathecal ERT in patients with MPS II (see, for example, U.S. National Institutes of Health ClinicalTrials.gov identifiers NCT00920647 and NCT02055118).

Another approach to enabling therapeutic proteins to cross the blood-brain barrier is by using fusion proteins. In this approach, the therapeutic protein is fused with another protein that binds to receptors that stimulate its transport across the blood-brain barrier via active receptor-mediated transport. Intravenous administration of a fusion protein consisting of the I2S enzyme with a monoclonal antibody to the human insulin receptor has been reported to produce therapeutic concentrations of I2S in the brain of Rhesus monkeys (Lu *et al.*, 2011).

Biomarkers

To date, blood enzyme levels and total uGAGs are the only commonly used biomarkers for diagnosis of MPS. There is no consensus, however, on the use of GAGs to assess treatment efficacy; however, some experts assert that in addition to clinical efficacy, the biochemical effect of idursulfase is noted by a dose-dependent reduction in uGAG excretion (Clarke, 2008; Clarke *et al.*, 2012). Although measurement of uGAG levels may provide some nuanced information regarding treatment efficacy, the information is nonspecific and subject to variability depending on the age and hydration status of the patient, features that limit the utility of this biomarker (Langford-Smith *et al.*, 2011).

There is great hope that new biomarkers will provide greater specificity and ultimately help to improve outcomes in patients with Hunter syndrome. One such biomarker is heparin cofactor II-thrombin complex (HCII-T), which was recognized as a biomarker for MPS diseases in 2008 (Randall *et al.*, 2008). A subsequent investigation of blood samples from patients with MPS diseases found that serum HCII-T levels are elevated prior to ERT treatment of Hunter syndrome and that levels decrease in response to treatment (Langford-Smith *et al.*, 2011). These results suggest that HCII-T might be a suitable biomarker for the diagnosis and monitoring of immediate treatment outcomes, whereas the ratio of urine dermatan sulfate to chondroitin sulfate may correlate with long-term clinical outcomes. Continued research is needed to determine the clinical utility of new biomarkers.

Social Support

Social partnership

The multisystemic nature of Hunter syndrome underscores the importance of a multidisciplinary team approach. In addition to medical specialists, the patient's care team should include the coordinating support of a social worker. This is important in Latin America, where there is a high percentage of the population with limited economic and cultural resources, far from minimum standards of welfare.

As part of the multidisciplinary care team, the social worker must act responsibly to effectively coordinate social services to enhance individual capabilities and collective resources so as to best meet the needs of patients and their families. Education and training, including the creation of action strategies, play important roles in coordinating the work of the entire care team to optimize patient outcomes. The social worker plays a vital coordinating role in the care team to bridge the gap between physicians, patients, and families, and to facilitate optimal treatment. The social worker must assess the socioeconomic needs of each patient and intervene, as appropriate, to overcome the effects of social, cultural, and economic obstacles to meet therapeutic goals.

The role of the social worker includes:

- Liaising with patients and their families and/or preparing them for the challenges of living with Hunter syndrome
- Facilitating access to adequate medical care
- Encouraging patients and their families to be active participants in attaining therapeutic goals
- Communicating with other members of the care team about the patient's individual challenges, while considering the patient's socioeconomic situation
- Informing patients and their families regarding their rights to social support and the resources available in their respective countries
- Talking with family members to help determine the patient's needs for support during treatment.

Resources for Patients and Families

Supportive care is an important component of treatment for patients with Hunter syndrome and their families. A number of resources are available to guide clinicians and family members in Latin America; for example, in Brazil the MPS Brazil Network (www.mps.ufrgs.br) provides information on MPS diseases for families and health professionals and also supports diagnostic intervention (see Supplementary Material Table S1).

Conclusion

Hunter syndrome is a rare, X-linked metabolic disorder that affects multiple organ systems in a progressive

manner. Patients with Hunter syndrome experience a wide spectrum of clinical manifestations that require management through a multidisciplinary care team. Early diagnosis of the disease and timely initiation of available treatments are key factors that may help to slow disease progression and lead to improved quality of life for patients and their families. Clinicians in Latin America should consider current data on the clinical aspects, diagnosis, and treatment of Hunter syndrome; furthermore, the patient's care team must coordinate efforts to employ available resources to optimize patient outcomes.

Acknowledgments

Shire funded the workshop that preceded the development of this paper. Editorial and translation assistance was provided by Maria Uravich and Robin Smith of The Curry Rockefeller Group, LLC, and was funded by Shire. The opinions expressed are solely those of the authors, and the authors confirm independence from the funding source. The authors received no payment for their work.

Financial Disclosure

Dr. Acosta has received travel and research grants from Shire, Genzyme, Biomarin, and Actelion. Dr. Amartino has received honoraria as a speaker for, travel support for educational activities, and unrestricted grants from Shire. Dr. Giugliani has received honoraria, travel grants, and research grants from Shire. Dr. Mahfoud Hawilou has received travel grants from Shire. Dr. Martins has received congress travel support and research grants from Biomarin, Genzyme, and Shire. Dr. Santos has received honoraria, travel grants, and research grants from Shire. Dr. Valdez has received grants from Shire. All other authors declare no conflict of interest.

References

- Alcalde-Martin C, Muro-Tudelilla JM, Cancho-Candela R, Gutierrez-Solana LG, Pintos-Morell G, Marti-Herrero M, Munguira-Aguado P and Galan-Gomez E (2010) First experience of enzyme replacement therapy with idursulfase in Spanish patients with Hunter syndrome under 5 years of age: Case observations from the Hunter Outcome Survey (HOS). *Eur J Med Genet* 53:371-377.
- American Thoracic Society (2002) ATS statement: guidelines for the six-minute walk test. *Am J Respir Crit Care Med* 166:111-117.
- Ballabio A and Gieselmann V (2009) Lysosomal disorders: from storage to cellular damage. *Biochim Biophys Acta* 1793:684-696.
- Barbier AJ, Bielefeld B, Whiteman DA, Natarajan M, Pano A and Amato DA (2013) The relationship between anti-idursulfase antibody status and safety and efficacy outcomes in attenuated mucopolysaccharidosis II patients aged 5 years and older treated with intravenous idursulfase. *Mol Genet Metab* 110:303-310.
- Beck M (2011) Mucopolysaccharidosis type II (Hunter syndrome): clinical picture and treatment. *Curr Pharm Biotechnol* 12:861-866.
- Braunlin EA, Harmatz PR, Scarpa M, Furlanetto B, Kampmann C, Loehr JP, Ponder KP, Roberts WC, Rosenfeld HM and Giugliani R (2011) Cardiac disease in patients with mucopolysaccharidosis: presentation, diagnosis and management. *J Inher Metab Dis* 34:1183-1197.
- Burton BK and Whiteman DA (2011) Incidence and timing of infusion-related reactions in patients with mucopolysaccharidosis type II (Hunter syndrome) on idursulfase therapy in the real-world setting: a perspective from the Hunter Outcome Survey (HOS). *Mol Genet Metab* 103:113-120.
- Burton BK, Guffon N, Roberts J, van der Ploeg AT and Jones SA (2010) Home treatment with intravenous enzyme replacement therapy with idursulfase for mucopolysaccharidosis type II - data from the Hunter Outcome Survey. *Mol Genet Metab* 101:123-129.
- Civallero G, Michelin K, de Mari J, Viapiana M, Burin M, Coelho JC and Giugliani R (2006) Twelve different enzyme assays on dried-blood filter paper samples for detection of patients with selected inherited lysosomal storage diseases. *Clin Chim Acta* 372:98-102.
- Clarke LA (2008) Idursulfase for the treatment of mucopolysaccharidosis II. *Expert Opin Pharmacother* 9:311-317.
- Clarke LA, Winchester B, Giugliani R, Tylki-Szymanska A and Amartino H (2012) Biomarkers for the mucopolysaccharidoses: discovery and clinical utility. *Mol Genet Metab* 106:395-402.
- de Jong JG, Wevers RA, Laarakkers C and Poorthuis BJ (1989) Dimethylmethylene blue-based spectrophotometry of glycosaminoglycans in untreated urine: A rapid screening procedure for mucopolysaccharidoses. *Clin Chem* 35:1472-1477.
- Dean CJ, Bockmann MR, Hopwood JJ, Brooks DA and Meikle PJ (2006) Detection of mucopolysaccharidosis type II by measurement of iduronate-2-sulfatase in dried blood spots and plasma samples. *Clin Chem* 52:643-649.
- Dickson PI (2009) Novel treatments and future perspectives: outcomes of intrathecal drug delivery. *Int J Clin Pharmacol Ther* 47 Suppl 1:S124-127.
- Ferrari S, Ponzin D, Ashworth JL, Fahnehjelm KT, Summers CG, Harmatz PR and Scarpa M (2011) Diagnosis and management of ophthalmological features in patients with mucopolysaccharidosis. *Br J Ophthalmol* 95:613-619.
- Froissart R, Moreira da Silva I, Guffon N, Bozon D and Maire I (2002) Mucopolysaccharidosis type II - genotype/phenotype aspects. *Acta Paediatr* 91:82-87.
- Giugliani R, Hwu W, Tylki-Szymanska A, Whiteman D and Pano A (2013) A multi-center, open-label study evaluating safety and clinical outcomes in young children (1.4-7.5 years) with Hunter syndrome receiving idursulfase enzyme replacement therapy. *Genet Med*, Epub Ahead of Print.
- Greenwald BJ (2010) Clinical practice guidelines for pediatric constipation. *J Am Acad Nurse Pract* 22:332-338.
- Guelbert N, Amartino H, Arberas C, Azar N, Bay L, Faiboim A, Fernandez MC, Giner A, Ilari R, Marchione D, *et al.* (2011) Guideline for diagnosis, follow-up and treatment of mucopolysaccharidoses type II or Hunter disease. *Arch Argent Pediatr* 109:175-181 [in Spanish].

- Guffon N, Bertrand Y, Forest I, Fouilhoux A and Froissart R (2009) Bone marrow transplantation in children with Hunter syndrome: outcome after 7 to 17 years. *J Pediatr* 154:733-737.
- Holt J, Poe MD and Escolar ML (2011a) Early clinical markers of central nervous system involvement in mucopolysaccharidosis type II. *J Pediatr* 159:320-326.e2.
- Holt JB, Poe MD and Escolar ML (2011b) Natural progression of neurological disease in mucopolysaccharidosis type II. *Pediatrics* 127:e1258-e1265.
- Jurecka A, Krumina Z, Zuber Z, Rozdzyńska-Swiatkowska A, Kloska A, Czartoryska B and Tylki-Szymanska A (2012) Mucopolysaccharidosis type II in females and response to enzyme replacement therapy. *Am J Med Genet A* 158A:450-454.
- Keilmann A, Nakarat T, Bruce IA, Molter D and Malm G (2012) Hearing loss in patients with mucopolysaccharidosis II: data from HOS - the Hunter Outcome Survey. *J Inher Metab Dis* 35:343-353.
- Langford-Smith KJ, Mercer J, Petty J, Tylee K, Church H, Roberts J, Moss G, Jones S, Wynn R, Wraith JE, *et al.* (2011) Heparin cofactor II-thrombin complex and dermatan sulphate:chondroitin sulphate ratio are biomarkers of short- and long-term treatment effects in mucopolysaccharide diseases. *J Inher Metab Dis* 34:499-508.
- Link B, Henseman L, Pinto L, Beck M, Guffon N, on behalf of the HOS investigators (2010) Orthopedic manifestations in patients with mucopolysaccharidosis type II (Hunter syndrome) enrolled in the Hunter Outcome Survey. *Orthop Rev (Pavia)* 2:e16.
- Liu KL (1980) The oral signs of Hurler-Hunter syndrome: report of four cases. *ASDC J Dent Child* 47:122-127.
- Lu JZ, Boado RJ, Hui EK, Zhou QH and Partridge WM (2011) Expression in CHO cells and pharmacokinetics and brain uptake in the Rhesus monkey of an IgG-iduronate-2-sulfatase fusion protein. *Biotechnol Bioeng* 108:1954-64.
- Martin R, Beck M, Eng C, Giugliani R, Harmatz P, Munoz V and Muenzer J (2008) Recognition and diagnosis of mucopolysaccharidosis II (Hunter syndrome). *Pediatrics* 121:e377-e386.
- Mendelsohn NJ, Harmatz P, Bodamer O, Burton BK, Giugliani R, Jones SA, Lampe C, Malm G, Steiner RD and Parini R (2010) Importance of surgical history in diagnosing mucopolysaccharidosis type II (Hunter syndrome): Data from the Hunter Outcome Survey. *Genet Med* 12:816-822.
- Miebach E (2009) Management of infusion-related reactions to enzyme replacement therapy in a cohort of patients with mucopolysaccharidosis disorders. *Int J Clin Pharmacol Ther* 47 (suppl 1):S100-S106.
- Milligan A, Hughes D, Goodwin S, Richfield L and Mehta A (2006) Intravenous enzyme replacement therapy: better in home or hospital? *Br J Nurs* 15:330-333.
- Muenzer J, Wraith JE, Beck M, Giugliani R, Harmatz P, Eng CM, Vellodi A, Martin R, Ramaswami U, Gucavas-Calikoglu M, *et al.* (2006) A phase II/III clinical study of enzyme replacement therapy with idursulfase in mucopolysaccharidosis II (Hunter syndrome). *Genet Med* 8:465-473.
- Muenzer J, Gucavas-Calikoglu M, McCandless SE, Schuetz TJ and Kimura A (2007) A phase I/II clinical trial of enzyme replacement therapy in mucopolysaccharidosis II (Hunter syndrome). *Mol Genet Metab* 90:329-337.
- Muenzer J, Beck M, Eng CM, Escolar ML, Giugliani R, Guffon NH, Harmatz P, Kamin W, Kampmann C, Koseoglu ST, *et al.* (2009) Multidisciplinary management of Hunter syndrome. *Pediatrics* 124:e1228-e1239.
- Muenzer J, Beck M, Giugliani R, Suzuki Y, Tylki-Szymanska A, Valayannopoulos V, Vellodi A and Wraith JE (2011) Idursulfase treatment of Hunter syndrome in children younger than 6 years: results from the Hunter Outcome Survey. *Genet Med* 13:102-109.
- Muenzer J, Bodamer O, Burton B, Clarke L, Frenking GS, Giugliani R, Jones S, Rojas MV, Scarpa M, Beck M, *et al.* (2012) The role of enzyme replacement therapy in severe Hunter syndrome - an expert panel consensus. *Eur J Pediatr* 171:181-188.
- Neufeld EF and Muenzer J (2001) The mucopolysaccharidoses. In: Scriver CR, Beaudet AL, Sly WS and Valle D (eds) *The Metabolic and Molecular Bases of Inherited Disease*, Volume III. 8th edition. McGraw-Hill, New York, pp 3421-3452.
- Peck JE (1984) Hearing loss in Hunter's syndrome - Mucopolysaccharidosis II. *Ear Hear* 5:243-246.
- Pinto R, Caseiro C, Lemos M, Lopes L, Fontes A, Ribeiro H, Pinto E, Silva E, Rocha S, Marcao A, *et al.* (2004) Prevalence of lysosomal storage diseases in Portugal. *Eur J Hum Genet* 12:87-92.
- Prasad VK and Kurtzberg J (2010) Transplant outcomes in mucopolysaccharidoses. *Semin Hematol* 47:59-69.
- Randall DR, Colobong KE, Hemmelgarn H, Sinclair GB, Hetty E, Thomas A, Bodamer OA, Volkmar B, Fernhoff PM, Casey R, *et al.* (2008) Heparin cofactor II-thrombin complex: a biomarker of MPS disease. *Mol Genet Metab* 94:456-461.
- Scarpa M (2011) Mucopolysaccharidosis type II. In: Pagon R, Bird T, Dolan C and Stephens K (eds) *GeneReviews* 1993-2007. University of Washington, Seattle, E-book. Available at: www.ncbi.nlm.nih.gov/books/NBK1274/, accessed May 1, 2014.
- Scarpa M, Almassy Z, Beck M, Bodamer O, Bruce IA, De Meirleir L, Guffon N, Guillen-Navarro E, Hensman P, Jones S, *et al.* (2011) Mucopolysaccharidosis type II: European recommendations for the diagnosis and multidisciplinary management of a rare disease. *Orphanet J Rare Dis* 6:72.
- Schulze-Frenking G, Jones SA, Roberts J, Beck M and Wraith JE (2011) Effects of enzyme replacement therapy on growth in patients with mucopolysaccharidosis type II. *J Inher Metab Dis* 34:203-208.
- Shire Human Genetic Therapies I (2011) Elaprase® (idursulfase) solution for intravenous infusion [prescribing information]. Cambridge, MA: Shire Human Genetic Therapies, Inc.
- Tuschl K, Gal A, Paschke E, Kircher S and Bodamer OA (2005) Mucopolysaccharidosis type II in females: case report and review of literature. *Pediatr Neurol* 32:270-272.
- Tylki-Szymanska A, Jurecka A, Zuber Z, Rozdzyńska A, Marucha J and Czartoryska B (2012) Enzyme replacement therapy for mucopolysaccharidosis II from 3 months of age: a 3-year follow-up. *Acta Paediatr* 101:e42-e47.
- Vellodi A, Young E, New M, Pot-Mees C and Hugh-Jones K (1992) Bone marrow transplantation for Sanfilippo disease type B. *J Inher Metab Dis* 15:911-918.
- Vellodi A, Young E, Cooper A, Lidchi V, Winchester B and Wraith JE (1999) Long-term follow-up following bone

marrow transplantation for Hunter disease. *J Inher Metab Dis* 22:638-648.

Vieira T, Schwartz I, Munoz V, Pinto L, Steiner C, Ribeiro M, Boy R, Ferraz V, de Paula A, Kim C, *et al.* (2008) Mucopolysaccharidoses in Brazil: what happens from birth to biochemical diagnosis? *Am J Med Genet A* 146A:1741-1747.

Wraith JE, Beck M, Giugliani R, Clarke J, Martin R and Muenzer J (2008a) Initial report from the Hunter Outcome Survey. *Genet Med* 10:508-516.

Wraith JE, Scarpa M, Beck M, Bodamer OA, De Meirleir L, Guffon N, Meldgaard Lund A, Malm G, Van der Ploeg AT and Zeman J (2008b) Mucopolysaccharidosis type II (Hunter syndrome): a clinical review and recommendations for treatment in the era of enzyme replacement therapy. *Eur J Pediatr* 167:267-277.

Internet Resources

World Health Organization, World Health Organization (WHO) Guidelines on Treatment of Diarrhea, http://www.pediatriconcall.com/for-doctor/diarrhea/who_guidelines.asp (May 10, 2013).

Supplementary Material

The following online material is available for this article:

- Table S1: MPS resources

This material is available as part of the online article at <http://www.scielo.br/gmb>.

Editor: Carlos F.M. Menck

License information: This is an open-access article distributed under the terms of the Creative Commons Attribution License, which permits unrestricted use, distribution, and reproduction in any medium, provided the original work is properly cited.