

Luiz Henrique Gebrim, Geraldo Rodrigues de Lima, Osvaldo Gianotti Filho, Elci Barreto, Fausto F. Baracat, Hartmut H. Grabert.

Prognostic value of the histopathologic private characteristics of breast cancer in patients with no axillary lymph node involvement

This paper won the "A. C. Camargo Award" Granted by the "Associação Paulista de Medicina" in 1993.

The biological behavior of breast cancer supports the impression that it is often a systemic disease which can recur many years after the treatment of the local lesion.

Since 35% of patients without axillary nodal metastasis will have recurrence of the disease after mastectomy, prognostic indicators are necessary to identify the high-risk patients to allow a more rational adjuvant therapy.

We studied the prognostic value of fatty tissue invasion, perineural involvement and lymphatic and venous peritumoral embolization in T2NOMO primary breast carcinomas.

Fifty-three patients were studied after initial treatment (only Halsted mastectomy). They were divided into two groups: A (control), with 25 patients with 15 years of survival without clinical and laboratory evidence of metastasis, and group B, with 28 patients who developed metastasis after initial treatment.

The results were analysed by the chi-square test ($p < 0.05$).

The fatty tissue invasion was identified in 56.0% and 78.5% in the A and B groups respectively, while venous embolization was only detected in 8.0% of the group A tumors and in 10.7% of those in group B. Neither showed significant variation when analyzed according to the chi-square test. Lymphatic embolization and perineural involvement were found respectively in 36.0% and 40.0% in the group A tumors and in 67.8% and 71.4% of those in group B, exhibiting a significant statistical variation.

When analysing the histopathological characteristics in the pre- and post-menopausal patients, the chi-square test disclosed that lymphatic embolization and perineural involvement had a significantly higher incidence only in pre-menopausal patients in group B.

UNITERMS: breast cancer, node negative, histopathology, prognosis

INTRODUCTION

Breast cancer is being featured in current literature because of its increasing incidence and a high mortality rate among Western women (4,7,9).

In the United States, 142,000 new cases of cancer were diagnosed in 1989. It is the principal cause of death among women (6,7).

There are an estimated 40,000 new cases every year in Brazil, leading to about 4,000 deaths annually (4,16).

The clinical picture is variable, exhibiting forms of slow evolution or speedy progression, depending on the tumor/host relationship.

Recent studies further support the evidence that lymphatic metastization would precede the hematogenic. The first one would take place initially after the 20th doubling of the malignant neoplastic cell, at a state at which, from a clinical point of view, the primary tumor is undetectable (5,8,14).

It is known that the many communications existing between lymph and venous capillaries permit metastasized

Address for correspondence: Dr. Luiz Henrique Gebrim
Rua Caçapava, 49, Conj. 12 – CEP 01408-010
São Paulo – SP – Brazil

tumor cells to pass from one system to the other (2,7). As such, FIDLER and NICOLSON (1991) consider that the division in lymphatic and hematogenic metastasis is arbitrary and that therefore the role played by the axillary lymph nodes as a barrier against metastatic cells is questionable, for the latter are not always retained by the former.

Histopathological involvement of the axillary lymph nodes continues to be the principal prognostic indicator, characterizing an inverse correlation between the number of involved nodes and survival (5,6,12,24).

By contrast, the absence of histologic metastases in the axillary lymph nodes does not imply patient remission. During the 10 years following initial treatment, 25% of them present metastases leading to death.

Because of this phenomenon, attention has focused on the study and identification in the primary tumor of prognostic indicators that might select among patients with high risk of recurrence those eligible for adjuvant systemic therapy.

Elements that contribute to a more precise characterization of the prognosis are many. Among them are to be stressed the clinical, morphological, biochemical, immunological ones, oncogenes, cell kinetics, etc. However, reproducibility of the majority of these elements is difficult. They are not cost-effective, require sophisticated equipment, and as such are not viable, especially in the Brazilian environment. Thus, current tumor morphology has been a widely studied subject because it features these extensive advantages.

The majority of authors consider that many of the morphological aspects pertaining to the primary tumor, such as histopathological type, multicentricity, differentiation rate, dermic lymphatic embolization, lymphocytic infiltration, degree of necrosis and desmoplastic reaction are of great prognostic value (2,3,9,12).

Nevertheless, additional indicators, such as peritumoral lymphatic and venous embolization, invasion of the fatty tissue, involvement of the perineural space and spread of the tumor boundaries, among others, have contradictory values attributed to them in literature (2,9,11,12,21).

The authors found no reference with patients belonging to the IIA stage (T2NOMO), U.I.C.C. (1988) who had been submitted to the same treatment and with equal distribution for clinical and histopathological aspects of a primary tumor. With this in mind, and aware that in Brazil the majority of the node negative patients belong to the II_A state, the chosen course was to study the prognostic value of some histopathological peritumoral characteristics.

PATIENTS AND METHODS

Patients

We studied 53 out of 221 patients with primary breast carcinoma and with no histopathological involvement of the axillary lymph nodes among those treated at the Mastology Section of the Gynecology and Obstetrics Service of the Public Officials State Hospital Francisco Morato de Oliveira, of Sao Paulo, between January 1970 and December 1975.

Patients were divided into two groups. The first, a control group called group A, comprises 25 patients with a minimum survival rate of 15 years, still under surveillance, who do not exhibit clinical or laboratory evidence of recurrence or metastasis. In the other group, called B, the tumors of 28 patients, decreased because of histologically confirmed metastasis resulting from a primary breast tumor, were studied.

Only primary tumors T2NoMo (UICC - 1988) were studied, classified as infiltrating ductal carcinomas (W.H.O., 1981) (25).

All the patients were submitted to the same initial treatment, which consisted solely and exclusively of the Halsted radical mastectomy.

Both groups, in addition to pertaining to the same clinical stage, had the same histopathological modality and were equally standardized for menopausal status, site of primary tumor and rate of differentiation.

The following exclusion criteria were used: patients who had been submitted to an adjuvant therapy (radiation, chemo or hormone therapy) who had a previous tumor biopsy at another hospital; those with analyzed lymph nodes numbering less than 10, bilateral breast or other organ cancer; histopathological dermic involvement or lymphatic embolization found in the mammary tissue distant from the primary tumor. Also excluded were intraductal carcinomas and special modalities such as: Paget, inflammatory, medullary, tubular, papillary, colloid, lobular, adenocystic. Patients with undifferentiated forms (G3) of infiltrating duct carcinoma were also excluded because such a tumor has a poor prognosis.

Histopathological Method

The histopathological study was retrospectively undertaken by two pathologists in double blind. As an average, three slides of approximately 3 cm² were analyzed concerning the primary tumor including the skin, two of each quadrant and one slide of each of the pectoralis muscles, nipple and lymph nodes. Each lymph node was sectioned in half along its largest diameter.

The utilized histopathological criterion for tumoral malignancy was that of PATEY and SCARFF (1928) (10), modified by BLOOM and RICHARDSON (1957) (3), being G1 (well differentiated), G2 (moderate) and G3 (undifferentiated).

After a routine histopathological study, the following characteristics were studied: invasion of the fatty tissue, involvement of the perineural space, lymph and venous embolization (Figures 1, 2, 3 and 4). Such elements were preferably researched in the peripheral portion of the primary tumor, contiguous to stromal invasion.

Statistical Method

Non-parametric tests were used for the analysis of results, taking into account the type of variables.

In all tests, the level of significance of the null hypothesis was set at 0.05 or 5% ($p < \text{or equal to } 0.05$), significant values were marked with an asterisk.

RESULTS

Fatty tissue invasion was identified in 56.0% and 78.5% in the A and B groups respectively, while venous embolization was only detected in 8.0% of the group A tumors and in 10.7% of those in group B. Neither showed significant variation when analyzed according to the chi-square test (Table 1).

Lymphatic embolization was found in 36.0% of the group A tumors and in 67.8% of those in group B, exhibiting a significant statistical variation according to the chi-square test.

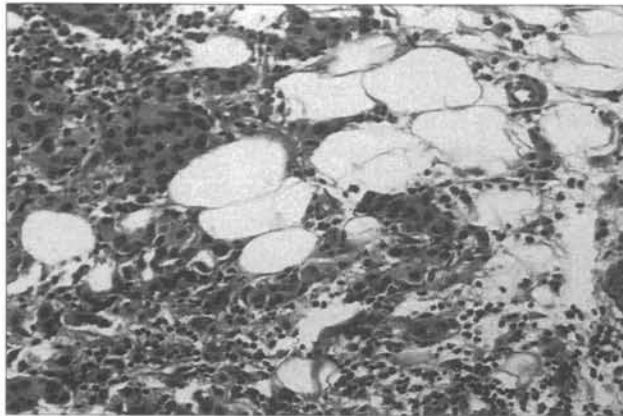


Figure 1 – Microphotography of primary breast cancer with adipose tissue infiltration (HE 200 \times).

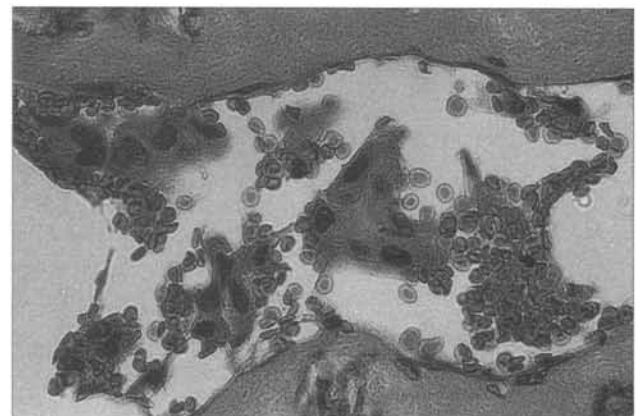


Figure 3 – Microphotography of breast cancer with anaplastic cells and blood cells clustered in the interior of a venula (HE 400 \times).

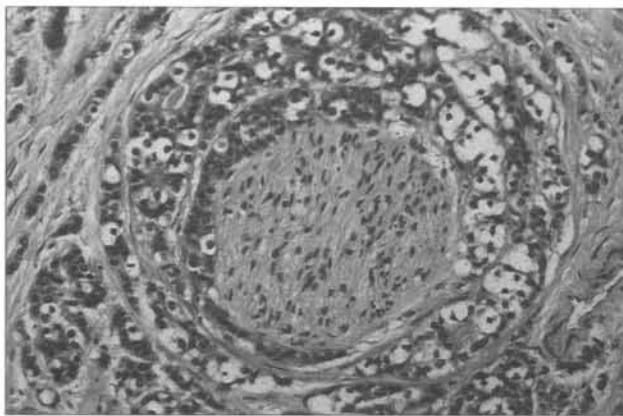


Figure 2 – Microphotography of breast carcinoma with invasion of the perineural space (HE 160 \times).

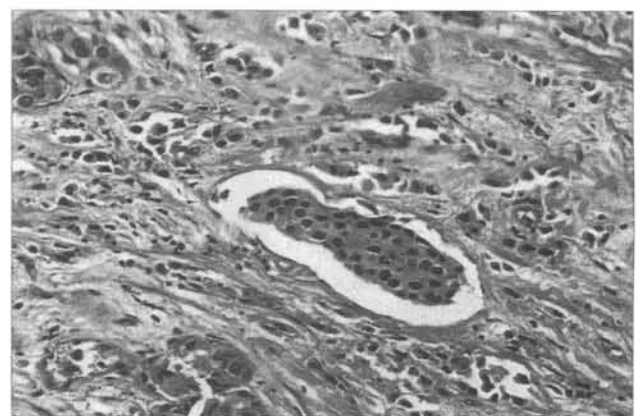


Figure 4 – Microphotography of breast cancer with anaplastic cells clustered within a lymphatic vessel.

Table 1
Presence of the studied histopathological characteristics in 53 patients of Group A (control) and Group B (deaths).

Groups	Fatty T. In. N. (%)	Venous E. N (%)	Lymph E. N (%)	Perineural I. N (%)
A	14 (56.0)	2 (8.0)	9 (36.0)	10 (40.0)
B	22 (78.0)	3 (10.7)	19* (67.8)	20** (71.4)

CHI-SQUARE TEST

*X²calc = 5.38

**X²calc = 5.37

X²crit = 3.84

(P<0.05)

Involvement of the perineural space was found in 40.0% of the group A tumors and in 71.4% of those in group B. The chi-square test disclosed significant variation between the two groups.

When analyzing the distribution of the histopathological variations in the pre- and post-menopausal status, the chi-square test disclosed that lymphatic embolization and perineural involvement had a significantly higher incidence in patients at premenopausal stage of group B (Table 2) and were not variations found in those at post-menopausal status (Table 3).

DISCUSSION

The important strides forward made by breast oncology are primarily due to an early diagnosis which, by pinning down an increasing number of patients with

Table 2
Presence of the histopathological characteristics studied in 27 patients at pre-menopause in Group A (control) and Group B (deaths).

Groups	Fatty T. In. N. (%)	Venous E. N (%)	Lymph E. N (%)	Perineural I. N (%)
A	6 (42.8)	1 (3.7)	2 (14.2)	3 (21.4)
B	10 (71.4)	1 (3.7)	9* (64.2)	10** (71.4)

CHI-SQUARE TEST

X²crit = 3.84

X²calc = 7.33

X²calc = 7.03

(P<0.05)

Table 3
Presence of histopathological characteristics studied in 26 patients at post-menopause in Group A (control) and Group B (deaths).

Groups	Fatty T. In. N. (%)	Venous E. N (%)	Lymph E. N (%)	Perineural I. N (%)
A	8 (72.7)	1 (3.8)	7 (63.4)	10 (71.4)
B	12 (85.7)	2 (7.6)	10 (71.4)	10 (71.4)

FISHER Test (n.s.)

(P<0.05)

tumors at initial stages, reduces the mortality rate resulting from such neoplasms (1,7,8,14,22).

Recent studies in node negative breast cancer patients (stages I and II), submitted to radical mastectomy disclose, respectively, long-term, 10 and 15 years, survival rates of 80.0% and 70.0% (1,17,18,21,22).

Thus, patients with a high risk of recurrence must be selected to adjuvant systemic therapeutic procedure to lessen the mortality rate. Whenever feasible, the risk group must be identified for the adjuvant systemic treatment. It should not be administered routinely to all patients, not only because of the high cost of drugs but also because of the negative side effects, essentially caused by antitumor drugs.

A quicker and more cost-effective investigation for a specific therapy should initially rely upon the morphological data of the tumor, portraying some of the neoplasm biological characteristics.

In our environment, short of specialized personnel and material resources, priority must be given to the identification of these prognostic indicators to attain a more rational utilization of the adjuvant therapy.

Pre-tumoral fatty tissue invasion in node negative patients is of little prognostic significance. NEALON et al. (1981) observed it in 36.0% of instances, including patients at stage I. Results of this research show that such a characteristic is very common in the T2NoMo tumors. ROSEN et al. (1982) found 90.2% of fatty tissue invasion but did not relate it to recurrence.

Venous embolization was observed in 8.0% of group A tumors and 10.7% of group B. No significant statistical variation was found between the two groups, therefore, singly deprived of a prognostic value. FISHER et al. (1984), NEALON et al. (1981) and ROSEN et al. (1983) reached similar results, respectively 4.7%, 14.0% and 13.1%.

Peri and intratumoral venous embolization is quite a controversial phenomenon. The wide variation of criteria

for its identification renders matching data found in literature rather difficult, ranging between 4% and 46% (2,9,17,22,23).

In the current study the classical criterion by FISHER et al. (1984) formerly mentioned was the adopted one, which presents the smallest rate of subjectivity, and because of its easy reproducibility.

Although venous embolization was only detected in a small number of tumors, as a rule it was associated with the other three indicators under study. The bulk of research in node negative patients was performed with stage I tumors and does not seem to have any isolated prognostic value.

Among the histopathological characteristics studied, lymphatic embolization, identified by histological sections of the breast carcinoma, has the highest prognostic potential.

Most reviews on the subject, found in literature, confirm its prognostic significance when undertaken on patients at clinical stage I (2,17,21,22).

In the current study, lymphatic embolization was present in 36.0% of the group A tumors and in 67.8% of those in group B, exhibiting significant variation (Table I). The average found was of 52.8%. A higher percentage than that of NEALON et al. (1981) and LEE et al. (1990), who respectively found 36.0% and 33.3%. The homogeneous quality of the surveyed groups might account for such results, as the first author also included stage I tumors, in which the phenomenon is seldom found, described as ranging between 8.0% and 31.8% (2,9,10,15,22).

In T2 tumors a higher expression of the phenomenon was expected and was indeed found. Variation reached in both groups further confirms its prognostic value at this clinical stage, BETTELHEIM et al. (1981).

The contradictory results reported in literature are further brought about by the reproducibility of the histopathological procedure used to diagnose lymphatic embolization.

GILCHRIST et al. (1982) observed that there is a 34.2% rate of disagreement among the various pathologists who studied intra and peritumoral vascular neoplastic embolization. It is very common that nests of tumor cells in the interstitial space mimic tumoral lymphatic microemboli (9,15,21).

Although this effect might result from the fixation technique, it will clearly be seen by an expert pathologist, as in the mammary stroma there are no endothelial cells surrounding the visualized space (9,21).

The rate of agreement between the two pathologists who participated in this study was 85.9%, similar to the rates of ROSES et al. (1982), FISHER et al. (1984), whose respective figures were 80.0% and 92.0%, proving the

high reproducibility of the procedure. The eight differing cases were examined again, after additional slabs had been prepared, and the pathologists reached a consensus. They concluded that precarious fixation in six of the cases and scarce material in the remaining two were essentially responsible for the disagreement.

Involvement of the peripheral space, found in 40.0% of group A and in 71.4% of group B, however, presented a significant variation similar to that of lymphatic embolization. In literature, data on such involvement are few. FISHER et al. (1984) correlated peripheral involvement to peritumoral lymphatic embolization and to axillary lymph node involvement. Such phenomenon might be explained by the presence of lymphatic networks in the peripheral space.

Although few authors have reported on the menopausal status (2,10,15), we observed in both groups that the three histopathological characteristics were detected in most of the tumors diagnosed in post-menopause, as such of less predictive value (Table 3).

In the pre-menopausal patients, peripheral involvement and lymphatic embolization were much less frequent in group A, thus having a higher predictive value about the outcome.

The improved response to the adjuvant hormone therapy in post-menopausal phase and to the antihormonal therapy at the premenopausal phase suggest that neoplasms exhibit a different behavior pattern at those two stages (7,9,10,14,17,20).

In our study group, the menopausal status bore a major influence on the figures for lymphatic embolization and for peripheral involvement, by contrast with the findings of LEE et al. (1990). The *Cooperative Breast Cancer Group* (1978), in a study of the venous embolization, reached similar results, which allow the conclusion that vascular microembolization might to some degree entail hormone dependence.

Based solely upon histopathological findings, the higher dissemination of breast cancer in post-menopausal women might be questioned. However, FRACCHIA et al. (1980) and BETTELHEIM et al. (1984b) did not find a difference in patient survival rates related to the menopausal status.

The presence of lymphatic embolization in 36.0% of tumors in the group A patients (control), similar to the 33% found by FISHER et al. (1984), again proves the limitation of this factor as sole prognostic indicator.

That is why we consider that lymphatic embolization and perineural space involvement, although useful prognostic tools in pre-menopause, should not be utilized as exclusive criteria for the trial of adjuvant systemic treatment.

Future research might detect variations of tumor morphology during the menstrual cycle and post-menopause, demonstrating in a more precise fashion the influence of the ovarian endocrine function on dissemination of breast cancer.

Unquestionably, one single indicator is not to be held responsible for the course of the disease, but a variety of them. Nevertheless, sophisticated and restricted procedures are not justified when seeking prognostic information without prior sound knowledge of the tumor's histopathological characteristics. As such, greater interaction and cooperation between technicians and pathologists is required, aiming to enhance the utilization of adjuvant therapy in the treatment of node-negative breast cancer.

ACKNOWLEDGEMENTS

Acknowledgements to Professors Neil Ferreira Novo and Yara Juliano of the Biostatistics Department of the "Escola Paulista de Medicina" for the statistical study undertaken.

REFERENCES

1. ADAIR, F.; BERG, J.; JOUBERT, L. & ROBBINS, G. F. – Long-term follow up of breast cancer patients: the thirty-year report. **Cancer**, **33**: 1145, 1974.
2. BETTELHEIM, R. & NEVILLE, A. M. – Lymphatic and vascular channel involvement within infiltrative breast carcinoma as a guide to prognosis at the time of primary surgical treatment. **Lancet**, **2**: 651, 1981.
3. BLOOM, H. J. G. & RICHARDSON, W. W. – Histological grading and prognosis in breast cancer. **Br J Cancer**, **11**: 359, 1957.
4. BRASIL. Ministério da Saúde – Estatística brasileira de mortalidade. **Brasília, Divisão Nacional de Epidemiologia**, 56, 1989.
5. BRENTANI, R. R.; LOPES, J. A. & JUNQUEIRA, L. C. M. – Biology of metastases. **Braz J Med Biol Res**, **21**: 1, 1988.
6. COOPERATIVE BREAST CANCER GROUP – Identification of breast cancer patients with high risk of early recurrence after radical mastectomy. II – Clinical and pathological correlations. **Cancer**, **42**: 2809, 1978.
7. FIDLER, I. J. & NICOLSON, G. L. – Concepts and mechanisms of breast cancer metastases. In: BLAND, K. I. & COPELAND, E. M. ed – The breast: comprehensive management of benign and malignant diseases. **Philadelphia, Saunders**, **395**, 1991.
8. FISHER, E. R.; REDMOND, C. & FISHER, B. – Pathologic findings from the national surgical adjuvant project for breast cancer. VI. Discriminants for tenth year treatment failure (Protocol. n° 4). **Cancer**, **53**: 712, 1984.
9. FISHER, E. R.; REDMOND, C.; FISHER, B. & BASS, G. – Pathologic findings from the national surgical adjuvant breast and bowel projects (NSABP). Prognostic discriminants for eight-years survival for node-negative invasive breast cancer patients. **Cancer**, **65**: 2121, 1990.
10. FRACCHIA, A. A.; ROSEN, P. P. & ASHIKARI, R. – Primary carcinoma of the breast without axillary lymph node metastasis. **Surg Gynec Obstet**, **151**: 325, 1980.
11. GEBRIM, L. H.; RODRIGUES DE LIMA, G.; BROM DOS SANTOS, H.; GUIDUGLI NETO, J. & GRABERT, H. H. – Relação entre tipo histopatológico e dosagem bioquímica dos receptores de estradiol e progesterona em pacientes portadoras de carcinoma primário da mama. **Rev Paul Med**, **105(4)**: 195, 1987.
12. GILCHRIST, K. W.; GOULD, V. E.; HIRSCHL, S.; IMBRIGLIA, J. E.; PARCHEFSKY, A. S.; PENNER, O. W.; PICKREN, J.; SCHWARTZ, I. S.; WHEELER, J. E.; BARNES, J. M. & MANSOUR, E. G. – Interobserver variation in the identification of breast carcinoma in intramammary lymphatics. **Hum Pathol**, **13**: 170, 1982.
13. INTERNATIONAL UNION AGAINST CANCER – TNM classification of malignant tumors. 4th ed, Geneva, U. I. C. C., 7, 1988.
14. KOSCIELNY, S.; LE, M. G. & TUBIANA, M. – The natural history of human breast cancer: the relationship between involvement of axillary lymph nodes and the initiation of distant metastases. **Br J Cancer**, **59**: 775, 1989.
15. LEE, A. K. C.; DELELLIS, R. A. & SILVERMAN, M. L. – Prognostic significance of peritumoral lymphatic and blood vessel invasion in node-negative carcinoma of the breast. **J Clin Oncol** **8(9)**, 1457, 1990.
16. MIRRA, A. P. & FRANCO, E. L. – Cancer mortality in São Paulo, Brazil. São Paulo, Ludwig Institute for Cancer Research (LICR cancer epidemiology monograph series, 3), 77, 1987.
17. NEALON Jr., T. F.; NKONGHO, A.; GROSSI, C. E.; WARD, R.; NEALON, C. & GILLOOLEY, J. F. – Treatment of early cancer of the breast (T1NOMO and T2NOMO) on the basis of histologic characteristics. **Surgery**, **89(3)**: 279, 1981.
18. PAGE, D. L. – Prognosis and breast cancer: recognition of lethal and favorable prognostic types. **Am J Surg Pathol**, **15(4)**: 334, 1991.
19. PATEY, D. H. & SCARFF, R. W. – The position of histology in the prognosis of carcinoma of the breast. **Lancet**, **1**: 801, 1928.
20. RODRIGUES DE LIMA, G. – Aspectos endócrinos das moléstias mamárias. In: _____ – Funções e disfunções endócrinas em ginecologia e obstetrícia. **São Paulo, Manole**, **2**: 585, 1975.
21. ROSEN, P. P. – Tumor emboli in intramammary lymphatics in breast carcinoma: pathologic criteria for diagnosis and clinical significance. **Pathol Ann**, **18**: 215, 1983.
22. ROSEN, P. P.; GROSHEN, S.; SAIGO, P. E.; KINNE, D. W. & HELLMAN, S. – Pathological prognostic factors in stage I (T1NOMO) and stage II (T1N1MO) breast carcinoma: a study of 644 patients with median follow-up of 18 years. **J Clin Oncol**: 1239-1251, 1989.
23. ROSES, D. F.; BELL, D. A.; FLOTTE, T. G.; TAYLOR, R.; RATECH, H. & DUBIN, N. – Pathologic predictors of recurrence in Stage I (T1NOMO) breast cancer. **Am J Clin Pathol**, **78**: 817, 1992.
24. SILVA NETO, J. B. – Tratamento do carcinoma da mama pela mastectomia radical: resultado e análise da influência de alguns fatores sobre o prognóstico. **Rev. Ass Med Bras**, **20**: 81, 1973.
25. WORLD HEALTH ORGANIZATION – Histological typing of breast tumours. 2nd ed, Geneva. W. H. O., 106, 1981.

RESUMO

Estudou-se o valor prognóstico da permeação adiposa, do comprometimento Perineural, da embolização linfática e venosa na periferia do tumor, em 53 pacientes com carcinoma de mama, bem e moderadamente diferenciados, relacionando com a recidiva dos pacientes na estágio 2A.

A permeação adiposa foi a característica mais frequente (67,9%) e não apresentou nos grupos estudados variação significativa. A embolização venosa foi a característica menos frequente (9,4%) e não variou nos dois grupos.

O comprometimento perineural e a embolização linfática apresentaram alto grau de concordância entre si e foram significativamente mais frequentes em tumores de pacientes axila negativa que apresentaram recidiva até 15 anos após o tratamento inicial.