

Parenteral injection of organophosphate insecticide. Apropos of two cases

Biomedical Sciences Center, Uberlândia Federal University, MG

Two cases of parenteral injection of organophosphate insecticide are reported. A 20-year-old man injected himself malathion intramuscularly, The developed necrosis in the injection set and abscess formation, and developed a severe poisoning reaction of late onset that was fully manifested 60 hours after the injection. A 22-year-old girl injected herself subcutaneously a small amount of fenitrothion and had severe swelling of the affected limb and a sterile abscess. In cases of parenteral injection of organophosphates, attention must be paid to the possibility of late onset of the clinical manifestations of the poisoning, and to the fact that usual measures to reduce exposure to the organophosphate, such as induction of vomiting, gastric lavage and use of activated charcoal are probably ineffective. Local complications at the site of the injection, like necrosis and abscesses are also expected findings.

UNITERMS: Injections; Insecticides; Organophosphate; Pesticides; Poisoning.

INTRODUCTION

Poisoning by organophosphate pesticides is an important medical problem in many parts of the world, particularly in developing countries. Poisoning occurs mostly by voluntary ingestion (by people attempting suicide), by inhalation or by absorption through the skin (3).

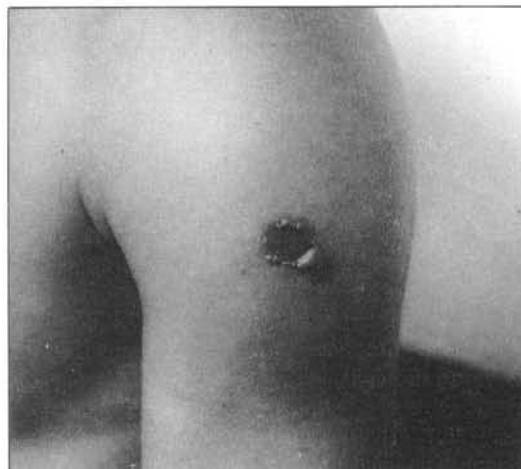
Two unusual cases of parenteral injection of organophosphate insecticides are described here.

CASE REPORTS

Case 1

A 20-year-old man injected 6 ml IM of an organophosphate insecticide (malathion) in to each deltoid muscle with a syringe normally used for horses (total dose of 7.2 grams). He sought medical help about 13 hours later, complaining of dizziness and sensation of pesticide taste in his mouth. He had a past history of having attempted suicide four times before. On admission he had no sign of poisoning, and physical examination revealed only swelling of both deltoid regions. In spite of this, treatment with pralidoxime was instituted. The patient was initially asymptomatic except for vomiting and the

appearance of an area of necrosis of the skin at the site of the injection on his left deltoid region (Figure). Sixty hours after the injection he developed salivation, muscular fasciculations and intense sweating. Miosis was noted later, and the patient developed progressive respiratory failure. In spite of receiving pralidoxime, atropine, and assisted ventilation, the patient died on the fourth day after admission. The death was attributed to respiratory failure due to organophosphate poisoning complicated by a nosocomial pneumonia. At the time of the death, he had abscesses in both deltoid regions. Serum levels of pseudocholinesterase (PChE) were not determined at any time.



Area de necrosis of the skin at the site of injection on the left arm (about 30 hours after the injection)

Address for correspondence: Dr. Sérgio de Andrade Nishioka - Av. Teresina, 1415 - Umuarama CEP 38405-384 - Uberlândia - MG - Brasil

Case 2

A 22-year-old woman attempted suicide trying to inject herself intravenously a spray preparation of organophosphate (fenitrothion) plus a pyrethroid insecticide, with a syringe that she had used before for other purposes. She said the liquid was volatile, making it difficult to handle the syringe properly. She missed the vein, and injected about 2 ml of the solution subcutaneously in her left forearm. There was an immediate onset of local numbness, and she complained of mild pain. There was also severe local swelling that extended to the whole limb, redness and blisters that appeared later. The lesion progressed to an abscess that was drained 5 days after the injection. Culture of the pus was sterile for aerobic bacteria. She had no sign of systemic toxicity. When last seen, 7 months later, the patient had no complaints, and had only a small scar where the incision for drainage was made.

DISCUSSION

Although organophosphate poisoning is not a rare event, I could find in the literature only one reference to poisoning by the parenteral route, the report by Lyon et al. of a 24-year-old man who injected 1.8 g of malathion intravenously (2). In that patient serum PChE levels were undetectable for 24 hours after the injection, but the patient had only moderate toxic effects and survived. The apparent half-life of malathion, calculated from the serum concentration data, was of 2.89 hours (2).

The second patient herein described had no symptom of poisoning, presumably because she injected a small amount of the drug. On the other hand, the other patient had severe poisoning, that proved to be lethal. The dose of malathion injected by this patient, although 4-fold higher than the injected intravenously by the patient described by Lyon et al (2), was considerably lower than the doses commonly ingested by patients attempting suicide. Interestingly enough, the clinical picture was of late onset and progressive severity, suggesting that the insecticide was absorbed slowly but continuously from the site of injection. From the observation of these patients, one can conclude that different presentations and outcomes of organophosphate poisoning depend not only on the pesticide, the dose and the time between poisoning and start of treatment, but also on the route of administration of the insecticide.

Another aspect of these two case report deserves comment. Local inflammatory findings are to be expected in cases of subcutaneous or intramuscular injection of insecticides, perhaps mainly because of the vehicle (solvent) and not of the pesticide itself. Therefore, abscess formation

is theoretically not an unlikely event. Abscesses can be sterile, as in case 2, but one must not forget that the injection can be given using contaminated material (as in both cases), and that secondary infection of the injured tissue is also a possibility. Such injuries are also a potential portal of entry to *Clostridium tetani*, hepatitis B virus and human immunodeficiency virus, among others.

In short, this report draws attention to the following facts: a) patients who inject organophosphate insecticides subcutaneously or intramuscularly may develop local abscesses. Tetanus prophylaxis and antibiotics, chosen based on the results of culture and direct examination of the pus, are recommended when appropriate; b) the onset of the symptoms can be delayed, and therefore patients should be not diagnosed as mild cases and discharged early, but kept under observation for at least 3 days; c) although the quantity of insecticide injected may be low when compared to the amount usually ingested in ordinary cases of organophosphate poisoning, the usual measures such as induction of vomiting, gastric lavage and use of activated charcoal (1) are probably useless in this situation. Local debridement of the injection site could be a possible measure to be taken in such cases aiming at removing of the "depot" of insecticide.

REFERENCES

1. LOTTI, M. - Treatment of acute organophosphate poisoning. *Med J Aust* **154**: 51-55, 1991.
2. LYON, J.; TAYLOR, H; ACKERMAN, B. - A case report of intravenous malathion injection with determination of serum half-life. *J Toxicol Clin Toxicol* **1** **25**: 243-249, 1987.
3. POLSON, C.J.; GREEN, M.A.; LEE, M.R. - *Clinical Toxicology*. London, Pitman, 541-543, 1983.

RESUMO

São relatados dois casos de injeção parenteral de inseticidas organofosforados. Um homem de 20 anos de idade injetou-se malathion por via intramuscular em ambos os deltóides, tendo desenvolvido necrose local e formação de abscesso, e desenvolveu um envenenamento grave de início tardio, que se manifestou de forma mais evidente 60 horas após a injeção. Uma mulher de 22 anos de idade injetou-se por via subcutânea uma pequena quantidade de fenitrothion, tendo apresentado edema acentuado do membro injetado, e um abscesso estéril. Em casos de injeção parenteral de organofosforados deve-se prestar atenção quanto à possibilidade do aparecimento tardio das manifestações clínicas de envenenamento, e ao fato de que as medidas usuais para reduzir exposição ao inseticida, como indução de vômito, lavagem gástrica e uso de carvão ativado são provavelmente inefetivas. Complicações no local da injeção, como necrose e abscessos, são também achados que podem ser esperados.