

*Maria Leticia Cintra, Elemir Macedo de Souza,  
Fernanda Mouro Fernandes*

## **Complete regression of melanocytic nevi: clues for proper diagnosis**

*Departments of Pathology and Dermatology, UNICAMP, Campinas, SP, Brazil.*

A histopathological study of a distinct papule isolated from a patient's neck is reported and compared to 80 melanocytic nevi. The histogenesis of this unique tumor indicates that it probably represents the residual of a melanocytic nevus in which nevi cells have disappeared but fat infiltration and fibrosis of the dermis and the typical aspects of other cutaneous elements persisted. The finding of focal acantholytic dyskeratosis in multiple foci of the lesion may indicate melanocytic cells regression. Lesions with the histopathological appearance of melanocytic nevi, even in the absence of nevi cells, may be discovered scrutinizing the associated alterations.

**UNITERMS:** Melanocytic nevus; regression; focal acantholytic dyskeratosis

### **INTRODUCTION**

**M**elanocytic nevi are development defects. Nevus, "lato sensu", means the abnormalities (hamartomas) manifested by hyperplasia or aplasia of the epidermis and dermis normal elements. The two elements most conspicuously involved in the nevus development are the nevi cells and the dermis nerves. The level of importance of other skin components (epidermis, pilosebaceous apparatus, sweat glands, vessels and connective tissue) will vary from case to case (10). According to Pinkus and Mehregan (15), these lesions are neoplasms, not malformations, since nevi cells constitute an abnormal tissue. Nevertheless, the following other abnormal structures presence within the nevi suggests that they are hamartomas: a) a vast dendritic arborization of free nerve endings throughout the nevi cells masses (17);

b) an attempt to form hair follicles on the soles and c) the association with trichoepitelioma (18). Furthermore, nevi areas seem to be predeternined in fetal life and once established they usually do not expand laterally (11).

As the nevus ages, both the skin where the nevus is settled as well as the nevi cells themselves, undergo alterations in their architecture. Therefore, the melanocytic nevi evolution and regression correlate to their histological appearance (8). The knowledge of these aspects allow us to recognize a nevus lesion even its cells have disappeared. This paper purpose is to report the histopathological observations of a distinct lesion settled on the dorsal face of a patient's neck, pointing out the histogenesis and its possible relationship to melanocytic nevus.

### **MATERIAL AND METHODS**

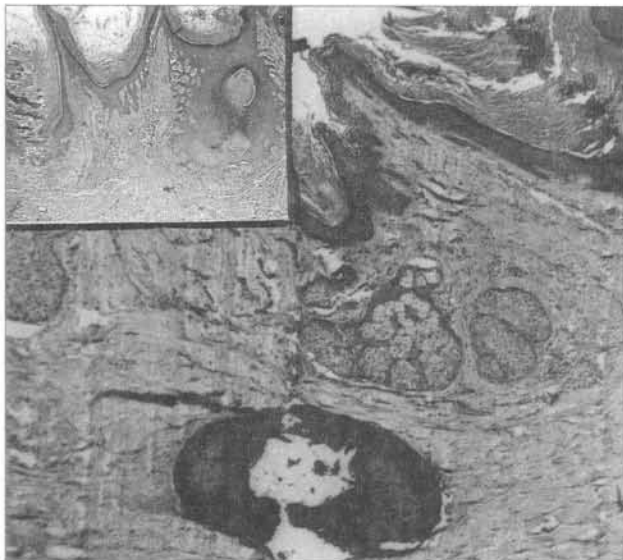
The lesion under discussion has been removed from the dorsal face of a 69 years-old man's neck. It appeared

**Address for correspondence:** *Fernanda Mouro  
Fernandes - Rua Culto à Ciência, 391 - apto.22 -  
Campinas - S P - Brasil - CEP 13020-060*

as an 8 mm erythematous, indurated, asymptomatic keratotic papule of unknown duration. The clinical diagnosis was adnexal tumor or keratotic basal cell epithelioma and it was surgically excised. The patient also had a basal cell carcinoma on his face. After the study of the neck lesion, 80 melanocytic nevi removed from different regions of other patients' bodies were collected and examined for comparison. All specimens were fixed in 10% formalin, the tissue was processed into routine paraffin-blocked sections. Multiple levels of the neck lesion were examined in hematoxylin-eosin-stained preparations and by immunohistochemical study for S100 protein.

### HISTOPATHOLOGICAL OBSERVATIONS

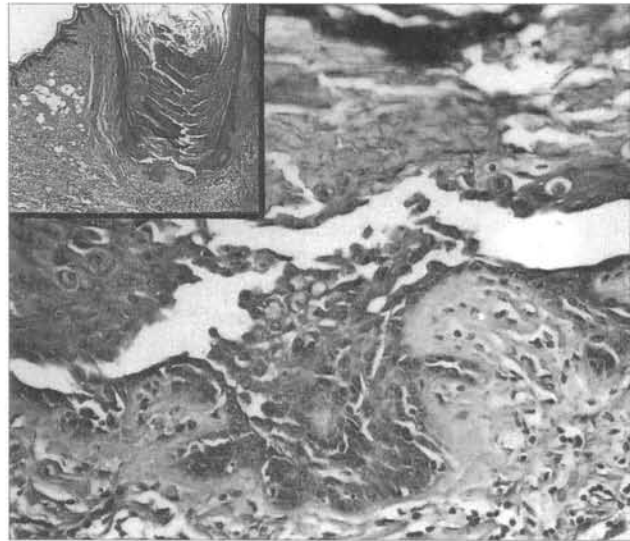
The lesion histological appearance was exophytic, with numerous, wide and deep epidermis invaginations filled with keratin, resembling dilated hair follicles. There were no sebaceous lobules at these comedo-like structures periphery, but in one which showed some glands lobules with calcified dermal foci at their base (Fig. 01). Most of them exhibited at their base multiple foci of acantholysis combined with dyskeratosis, resembling Darier's disease, as the result of the presence of ronds corps and grains. At the margin of the lesion there was a pronounced solar elastosis.



**Fig. 1** - The lesion is exophytic, with the epidermis numerous wide and deep invaginations filled with keratin, resembling to dilated hair follicles. Most of them exhibit foci of acantholysis and dyskeratosis. Fibrosis and an atrophic eccrine gland are present. A calcified dermal focus is present at the gland base. (x109; H&E). INSET: There are some lobules of sebaceous glands at a dilated hair follicle periphery (x52; H&E).

It must be emphasized that fat cells groups were found scattered among the high dermis collagen bundles, by the side of the dilated follicles (Fig. 02). Few lymphohistiocytic inflammatory cells were noticed. There was vascular neof ormation and fibrosis. We could notice a tendency for the vessels and fibers to remain at certain areas of the epidermis and to surround to dilated follicles. The dermis beneath the lesion showed some eccrine glands, sometimes cystically dilated with flattened epithelium.

The immunohistochemical reaction for S100 protein failed to demonstrate any nevus cell.

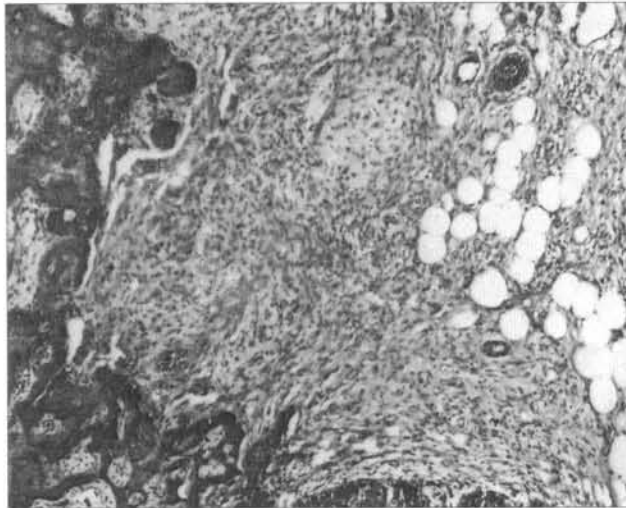


**Fig. 2** - Groups of fat cells are seen scattered among the high dermis collagen bundles, by the side of a dilated hair follicle. Acantholysis and dyskeratosis can be seen at the hair follicle base. /x140; (INSET, x208); H&E/.

### COMMENTS

Nevi do disappear, as reported by several authors. Lund & Stobbe and Stegmaier (8,19) have described in detail the natural regression of melanocytic nevi. An estimated percentage of 20 to 30 of nevi disappear in old age (15). The process toward involution and disappearance indicated by the statistics is hard to prove in individual lesions, but there have been proven cases by old photographs where this has happened (2,16). Nevi are generally believed to be eliminated from the skin by the following mechanisms: a) degeneration and atrophy of nevi cells, leaving just the fibrous stroma (15), a common age related phenomenon, b) fat degeneration: the cutis area of fat cell replacement may represent lipomatous infiltration followed by nevi cells atrophy (6). In the large,

hairy nevi found in children, lipomatous proliferation may be quite prominent, but can be considered a hamartomatous development (19). We observed the dermis fat infiltration in sebaceous nevi lesions (Fig. 3).

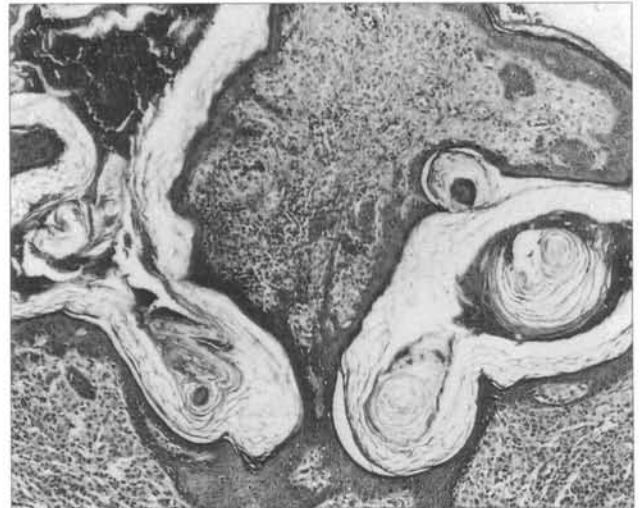


**Fig. 3 - Nevus sebaceous.** Basaloid proliferations are seen on the left. Numerous large fat cells lie in the upper dermis (x275; H&E).

However, it may be due to that they originate from mononuclear cells ( these cells can differentiate into the lipoblasts that can be identified around capillaries, as occurs in nevus superficialis lipomatous) (20), c) the descending nevus cells may stimulate a fibrous stromal reaction and be entirely replaced by fibrosis (6), d) the organism inflammatory response: in this relatively uncommon condition, one or more pigmented nevi are surrounded by a leukoderma halo (Sutton nevus or halo nevus). Histologically, there is an inflammatory lymphocytic reaction and nevi cells are destroyed as the epidermal melanocytes, clinically resulting in the formation of an halo, e) transdermal elimination may be another mechanism for nevus involution (6), f) friction and trauma: in papillomatous lesions, the more superficial cells are attached to the skin by fine stalks, so it's conceivable that many are slashed off during life. This may be partly responsible for the nevi volume reducing in the elder people. Furthermore, in many nevi studied, the epidermal pegs were anastomosed in several places, engulfing little pieces of dermis containing nevi cells, that were consequently eliminated(Fig. 4).

The lesion histopathological study suggested at first glance, a nevus comedonicus diagnosis, but the characteristic clinical-histopathological aspects were lacking. The following features allowed us to recognize it as a melanocytic nevus: a) there was an anfractuous surface as can be seen on the cerebriform nevi, b) the high dermis fat infiltration and fibrosis were present, with few or no

elastic fibers on the lesion and elastic degeneration only on the lesion's margin and c) dermal calcification and multiple foci of acantholytic dyskeratosis were also observed.



**Fig. 4 - Papillomatous compound nevus.** Little dermis pieces containing nevi cells will be eliminated (x275; H&E).

The nevi protusion increase is due to several causes, such as production of what seems to be new connective tissue developed in the nevus cells interstices (10). The reason why a keratotic fibrotic lesion persists as a residual of a regressed melanocytic nevus is difficult to answer. The nevus cells replacement by dense fibrosis in the dermis and the follicles irreversible abnormalities could maintain the papulous contour. Compound and intradermal nevi, specially those of the face and neck, may have large and distorted pilosebaceous follicles filled with keratin debris (8), for nevi can interfere with their growth (5). The lesion's follicles were surrounded and compressed by connective tissue fibers. Those fibers were arranged in a concentric laminated configuration, as is observed in nevi and fibrous papule of face (4).

Moles are often injured. Granulomas can be formed if the follicles are infected or ruptured. If they are only slightly damaged by epilation, necrobiosis may occur. All these facts may result in calcification, as it happened in the neck lesion studied or occurs in osseous metaplasia (3).

Elastic fibers are not found in all nevi and are present in greatly varying amounts (4,9,12,14). Nevi usually occur in sun exposed areas (13). In those areas where nevi cells disappear, senile elastosis may appear since elastic fibers have not been destroyed in the nevic evolution.

Clinically unapparent, histologically incidental foci of acantholytic dyskeratosis were found in biopsy specimens with the diagnosis of melanocytic nevus by

Ackerman (1).

Interestingly, the focal acantholytic dyskeratosis solitary form tends to occur on sun exposed skin, as was also observed in the lesion studied. Microscopic foci showing features of transient acantholytic dermatosis were observed in 8 melanocytic nevi regression areas by Lambert (7). The author suggested that focal lesions resembling transient acantholytic dermatosis could indicate the melanocytic lesions regression.

All these described features were also observed in many of the 80 melanocytic nevi studied. One of the lesions studied had been present in a woman's abdomen for along period of time without presenting any alteration. Recently, as it had gone through a clinical transformation, it was excised. Upon histological examination, it exhibited an intraepidermal nevi cells complete necrosis, with a peculiar pattern similar to that of fixed drug eruption (Fig. 5). All nevi cells would disappear in the future.

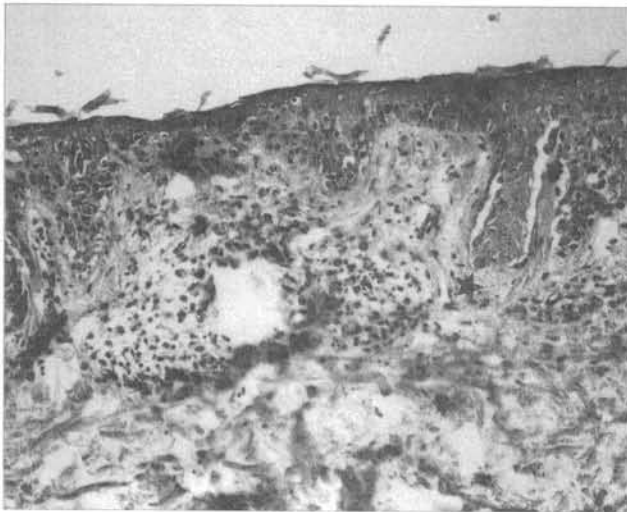


Fig. 5 - Junctional nevus. Complete intraepidermal nevi cells necrosis (x437; H&E).

## REFERENCES

1. ACKERMAN, A. B. - Focal acantholytic dyskeratosis. *Arch Dermatol* **106**:702-706,1972.
2. BRAITMAN, M. - Junctional nevus with spontaneous clinical disappearance. *Arch Dermatol* **77**:721,1958.
3. DUPPERRAT, B. - Suppurations folliculaires torpides sous les naevi mlaniques. *Ann Dermatol Syph* **81**:251-258,1954.
4. GRAHAM, J. H.; SANDERS, J. B. & JOHNSON, W. C.; et al - Fibrous papule of the nose: a clinicopathological study. *J Inv Dermatol* **45**:194-203,1965.
5. HABER, H. - Some observations on common moles. *Br J Dermatol* **74**:224-228,1962.
6. KANTOR, G. R. & WHEELAND, R. G. - Transepidermal elimination of nevus cells. A possible mechanism of nevus involution. *Arch Dermatol* **123**:1371-1374, 1987.
7. LAMBERT, W. C. - Focal transient acantholytic dermatosis in sites of regression in melanocytic lesions. Abstracts of papers presented at the 24 th, 1986 annual meeting of the American Society of Dermatopathology. *J Cutan Pathol* **13**:452,1986.
8. LUND, H. Z. & STOBBE, G. D. - The natural history of the pigmented nevus; factors of age and anatomic location. *Am J Pathol* **25**:1117-1155,1949.
9. MASSI, G.; FEDERICO, F.; CHIARELLI, C.; CELLENO, L. & FERRANTI, G. - Elastic fibers in congenital melanocytic nevus (letter). *Arch Dermatol* **125**:299-300,1989.
10. MASSON, P. - My conception of cellular nevi. *Cancer* **4**:9-38,1951.
11. McKIE, R. M. - Melanocytic naevi in Textbook of Dermatology, edited by Rook, A. et alii, Blackwell Scientific Publications, Oxford, London, Edinburgh, Boston, Palo Alto, Melbourne, pp 181-189,1986.
12. MEHREGAN, A. & STARICCO, R. G. - Elastic fibers in pigmented nevi. *J Inv Dermatol* **38**:271-276,1962.
13. NICHOLLS, E. M. - Development and elimination of pigmented moles and the anatomical distribution of primary malignant melanoma. *Cancer* **32**:191-195,1973.
14. ONO, T.; MAH, K. & HU, F. - Dermal melanocytes and elastic fibers. *J Cut Pathol* **12**:468-475,1985.
15. PINKUS, H. & MEHREGAN, A. H. - Melanocytic and nevocytic tumors and malformations in A Guide to Dermatopathology, edited by Appleton-Century-Crofts, New York, pp 441-466,1976.
16. SHELLEY, W. B. - Photographic evidence of the spontaneous involution and disappearance of pigment nevi. *Arch Dermatol* **81**:208-209,1960.
17. SHELLEY, W. B. & ARTHUR, R. P. - Nerve fibers, a neglected component of intradermal cellular nevi. *J Inv Dermatol* **34**:59-65,1960.
18. STARINK, T. M. & BROWNSTEIN, M. H. - Dermoplastic trichoepithelioma with intradermal nevus: a combined malformation. Abstracts of papers presented at the 24 th, 1986 annual meeting of the American Society of Dermatopathology. *J Cutan Pathol* **13**:464,1986.
19. STEGMAIER, O. C. - Natural regression of the nevus. *J Inv Dermatol* **32**:413-421,1959.
20. WILSON JONES, E.; MARKS, R. & PONGSEHIRUM, D. - Naevus superficialis lipomatous. *Br J Dermatol* **93**:121-133,1975.

---

## RESUMO

São relatados os aspectos histopatológicos de uma pápula isolada do pescoço comparativamente a 80 nevos melanocíticos. Os aspectos histogenéticos sugerem que este tumor representa o resíduo de um nevo melanocítico onde as células névicas já desapareceram, porém a infiltração da derme adipócitos maduros, o espessamento fibroso da derme e os aspectos típicos dos outros elementos cutâneo permanecem. O achado de disqueratose acantolítica focal em múltiplos pontos adiciona novo elemento sugestivo de NEVO em regressão. Lesões com características morfológicas de nevo melanocítico, mesmo na ausência de células névicas podem ser identificadas se as alterações associadas forem reconhecidas.