

Restoration of sensitivity after removal of the sural nerve. A new application of latero-terminal neurorraphy.

Discipline of Plastic Surgery, Botucatu Medical School, UNESP, Botucatu, SP, Brazil

INTRODUCTION

The sural nerve is possibly the most usual source of nerve grafts.

Its anatomical situation, extension and morphological characteristics are adequate to make it the first option for almost all cases where a nerve graft is indicated. To the contrary, its removal always produces an anesthesia zone, since it is responsible for the sensitive innervation of a great region of the foot (1,2,3,4,5,6,7,8,9,10,11). The anesthesia varies in extension among patients. This disturbance is commonly well accepted by the patients, and the surgeons consider it a minor problem since up to now there was no way of avoiding it.

Viterbo (1992) (12,13) and Viterbo and cols. (1992) (14) recently developed a new form of neurorraphy that might change this concept. It is a latero-terminal or a termino-lateral neurorraphy which utilize a healthy nerve as axon donor. The procedure does not change the donor nerve structure or function.

Based on this technique we tested the neurorraphy between the distal ending of the sural nerve termino-laterally to the superficial fibular nerve in order to avoid producing the anesthesia area consequent to its removal (Figs. 1, 2 and 3). The anatomical proximity between the nerves made the procedure easy and did not increase the surgical time.

CLINICAL CASE

Two patients were submitted to the procedure up to now.

Case 1. S.C.A., 28 years old, ID: 275.653-5, male, suffered a motorcycle accident 4 years earlier, with various fractures in the left upper limb. Since that time he is unable to move that limb and shows almost full absence of sensitivity. Electromyography and myelographic exams confirmed lesions by multiradicular proximal cervical avulsion, concomitantly of C5-8 and T1. Recent electromyography examination (April 07, 1993) showed signs of regeneration in C7-8 and T1, but not of C5-6.

In the day April, 7 1993, he was submitted to exploration of the brachial plexus. Since no discontinuities were found in the roots involved, we made various autografts with termino-lateral neurorraphies (12,13,14) between the phrenic nerve and the roots of C5-6. The purpose was to allow phrenic nerve fibers to grow through the graft into the C5-6 roots.

In the same opportunity we produced termino-lateral neurorraphy between the distal ending of the sural nerve and one of the branches of the superficial fibular nerve, close to the lateral malleolus, after removing an epineural window.

In the immediate post-operative period it was surprising to note that the patient did not refer any anesthetic area in the region innervated by the sural or in any other the sensitivity was tested by gentle touching and by metal needle no complication was observed.

Case 2. C.M.B.F., 47 years old, ID: 271.143-5, female, born and resident in Avaré, SP. She was submitted to resection of a Neurinoma which resulted total hearing loss and facial paralysis, both in the left side. In June 2, 1993, she was submitted to reparation of the facial paralysis

Address for Correspondence: Dr. Fausto Viterbo
Rua José Dal Farra, 592 - Botucatu - SP - Brasil
CEP 18603-790

through sural nerve transfacial graft termino-lateral neurorraphies, as proposed by Viterbo (1992) (15,16). In the same occasion, a termino-lateral neurorraphy was made with the distal ending of the sural nerve and a branch of the superficial fibular nerve. Since both sural nerves had been removed, the neurorraphy was made bilaterally. Again in the immediate post-operative period, the patient did not refer any anesthetic area in the sural nerve region of innervation or in any other area the sensitivity inspections were conducted as for the other patient.

CONCLUSION

In spite of the follow up periods having not been long enough and the number of operated cases being small for establishing unquestionable conclusion, we feel safe to report that the termino-lateral neurorraphy between the distal ending of the sural nerve to a branch of the superficial fibular nerve is able to prevent the sensorial sequel of the sural nerve removal the post-operative morbidity and the operative time are not increased.

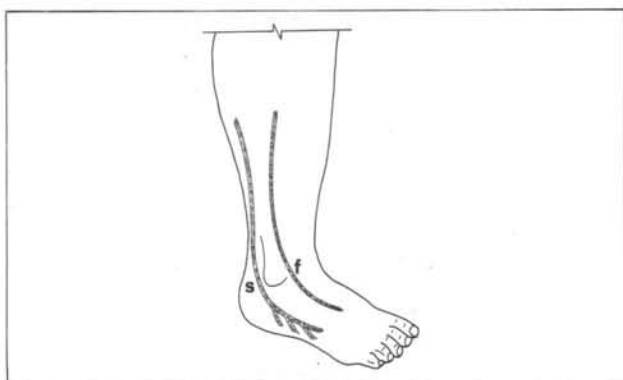

Fig.1. Schematic of the Sural (S) and the superficial fibular (F) nerves.

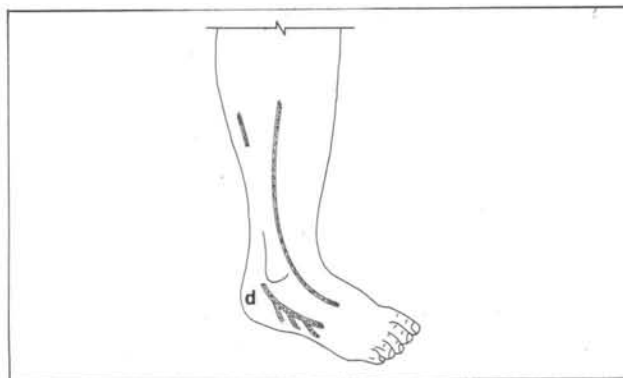


Fig.2. Schematic with detail of the distal ending (D) of the sural nerve, after its removal.

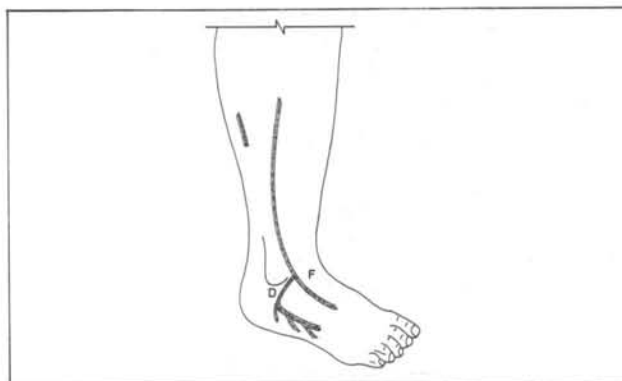

Fig.3. Schematic showing the latero-terminal neurorraphy between the distal ending of the sural nerve (D) and the superficial fibular nerve (F).

REFERENCES

1. BROOKS, D. The place of nerve-grafting in orthopedics surgery. *J Bone Surg (Am)* 37:299,1955.
2. BROWN, P. W. Factors of influencing the success of the surgical repair of peripheral nerves. *Surg Clin North Am* 52:1137,1972.
3. BUNNELL, S. & BOYES, J. H. Nerve graft. *Am J Surg* 44:64,1939.
4. DAVIS, L., PERRET, G. & CARROLL, W. Surgical principles underlying the use of grafts in the repair of peripheral nerves injuries. *Ann Surg* 121:686,1945.
5. MILLESI, H. Treatment of nerve lesions by fascicular free nerve grafts. In J. Michon and E. Morberg (Eds.), *Traumatic Nerve Lesions* Edinburg: Churchill/Livingstone, 1975.
6. SAUNDERS, F. K. The repair of large gaps in the peripheral nerve. *Brain* 65:281,1945.
7. SEDDON, H. J. Nerve grafting. *J Bone Joint Surg (Br)* 45:447,1963.
8. SEDDON, H. J. The use of autologous nerve graft. *Br J Surg* 35:151,1947.
9. SMITH, J. W. Microsurgery of peripheral nerves. *Plast Reconstr Surg* 33:317,1964.
10. SUNDERLAND, S., & RAY, L. J. The selection and use of autografts for bridging gaps in injured nerves. *Brain* 70:75,1947.
11. TERZIS, J. K., DYKES, R. W., & HAKSTIAN, R. W. Electrophysiological recording in peripheral nerve surgery: a review. *J Hand Surg* 1:52,1976.
12. VITERBO, F. - *Neurorrafia Látero-Terminal, estudo experimental no rato*. (PhD Thesis) - Botucatu, Faculdade de Medicina: Universidade Estadual Paulista, 1992. 198 pp.
13. VITERBO, F. - "*Neurorrafia látero-terminal. Estudo experimental no rato*". 29^o Congresso Brasileiro de Cirurgia Plástica, realizado em Porto Alegre, de 8 a 12 de novembro de 1992, Anais, p 35.
14. VITERBO, F.; TRINDADE J. C. S, HOSHINO K. & MAZZONI NETO A. Latero-terminal neurorraphy Without

Removal Of The Epineural Sheath. Experimental Study In Rats. *São Paulo Medical Journal, (Rev Paul Med)*, Nov-Dec, 1992; 110(6): 267-275.

15. VITERBO, F. - **Cross-face termino-lateral neurorraphy : a new method for treatment of facial palsy.** 61st Annual Scientific Meeting of the American Society of Plastic and Reconstructive Surgeons, the Plastic Surgery Educational Foundation, and the American Society of Maxillofacial Surgeons, Washington, DC, Sept 20th, 1992. *Plastic Surgical Forum*, 1992: 356-358

16. VITERBO, F. - **"Cross-face nerve com neurorrafia látero-terminal. Novo tratamento da paralisia facial".** 29^o Congresso Brasileiro de Cirurgia Plástica, realizado em Porto Alegre, de 8 a 12 de novembro de 1992, Anais , p 28.

ACKNOWLEDGMENTS

We thank very much to Prof. Dr. Romeu C. Guimarães to the final revision of the text and to Marcia Mazzoni for the designs.

RESUMO

Os autores propõem o emprego da neurorrafia término-lateral do coto distal do nervo sural na face lateral do nervo fibular superficial para evitar anestesia ou hipoestesia na face lateral do pé após a retirada do nervo sural para enxertia. A proximidade anatômica entre os nervos em questão tornam o procedimento simples, sem aumentar o tempo cirúrgico. A neurorrafia término-lateral proposta não prejudica as estruturas inervadas pelo nervo doador.