

## Secondary rhinoplasty: reconstitution of the allar cartillages by a rhinoplasty with an external incision

*Otorhinolaryngology Discipline, Hospital das Clínicas, Faculdade de Medicina da Universidade de São Paulo - São Paulo, Brazil*

Presentation of 62 cases of secondary nasal deformities treated by external incision. Several types of endonasal deformities were observed, properly classified and repaired. When excessive resection was observed, local cartilage graft, septonasal or conchal types were employed.

**UNITERMS:** Nose. Secondary rhinoplasty.

### INTRODUCTION

Classic endonasal rhinoplasty does not enable a symmetric resection of the allar cartillages. Due to this, presence of secondary endonasal deformities is very frequent.

Opening utilization, with a whole exposition of the cartillages, enabled an exact evaluation of deformities and, as a result, a more precise restoration.

In all of the cases, wrong removals were observed, resulting in the most different types of deformity, ranging from since a small asymmetria until a complete collapse, with total resection of the cartillages.

After Rethi (4), Sercer (5), Padovan (3) and, most recently, Goodman (1 and 2), Sheen (6), divulgated rhinoplasty through nose openings, we have observed that treatment of the secondary deformities as well as some

congenital ones, have been extremely improved by this procedure. Incision initially used was the one described by Rethi (4) and, afterwards, we have adopted the one proposed by Goodman (1 and 2), bearing the medium portion of the columella and in a broken line. This procedure resulted, in most of the cases, in a quite invisible scar 3 months ago.

In spite of requiring a longer surgery time, the wide exposition of the anatomic elements, a more symmetrical reparation of the elements is possible.

### SURGICAL TECHNIQUE

Incision begins in the marginal portion of both of the wings and is extended till the columella.

Endonasal cutaneous detachment starts on the point subcutaneous cellular tissue is more flabby continuing slowly in direction to the columella, where there is a higher adherence of the skin to the cartilage. In this point of surgery, incisions join each other at the medium part of the columella, in the form of a small inverted "v".

This sequence results in a faster detachment of skin, avoiding trauma and, sometimes, skin scrubbing at the

---

#### Address for correspondence:

Jorge Ishida  
Rua Padre Pereira de Andrade, 545  
Ilha do Sul - Ed. Ilha Bela, 123/124  
São Paulo - SP - Brasil - CEP 05480-000

columella point. Also, it is very important that, in some cases, even being scheduled an open rhinoplasty, deformity can be treated only by a marginal incision, being not necessary free columella in its entirety.

## DIAGNOSIS AND TREATMENT

Sixty-two cases of endonasal deformities were treated. Deformities can be classified as follows:

1. Excessive resection
2. Asymmetric resection
3. Insufficient resection
4. Total resection

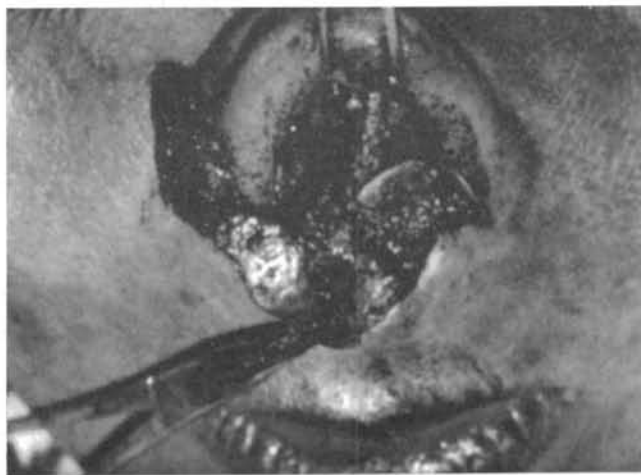
In 100% of the cases asymmetric resection was observed, even in the total ones, due to differences in the remaining stump.

Treatments were classified in two groups:

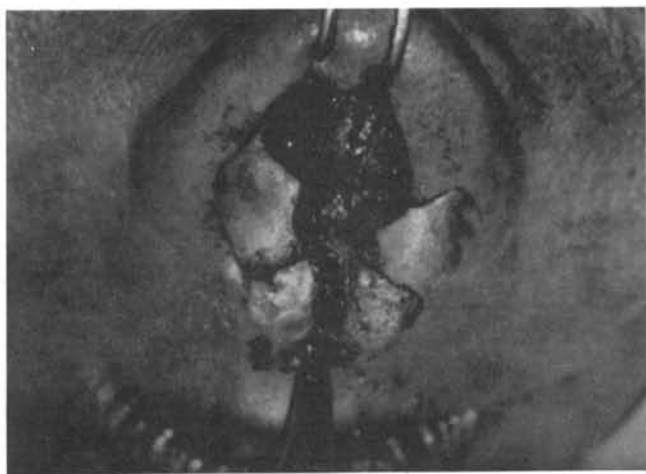
1. Insufficient and asymmetric cases: we tried to free all cartilages in its entirety, since the medial cross till extremity; approaching both cartilages, side by side, a completely symmetrical resection is possible to be done.



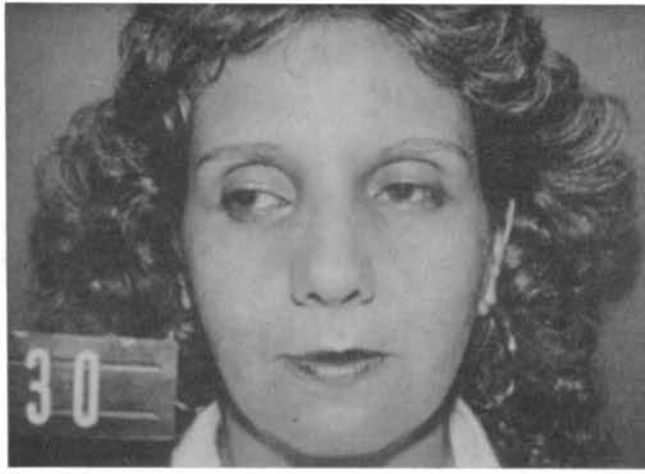**Figure 1A** - Preoperative semblance of the patient with endonasal asymmetry, saddle nose



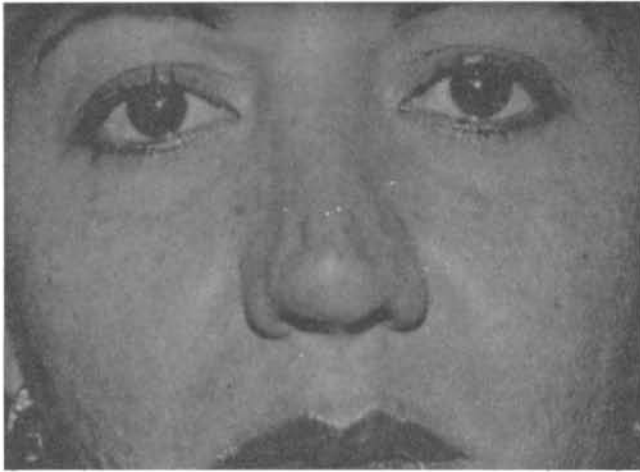**Figure 1B** - Aspect after endonasal exposition, high asymmetry of the alar cartilages, right alar cartilage sectioned right above domus




**Figure 1C** - Aspect of the alar cartilage restoration with alar cartilage left overs



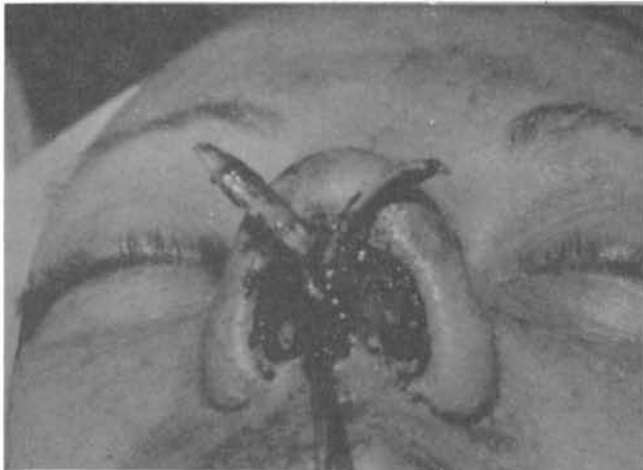**Figure 1D** - Final aspect of the patient, 6 months after surgery



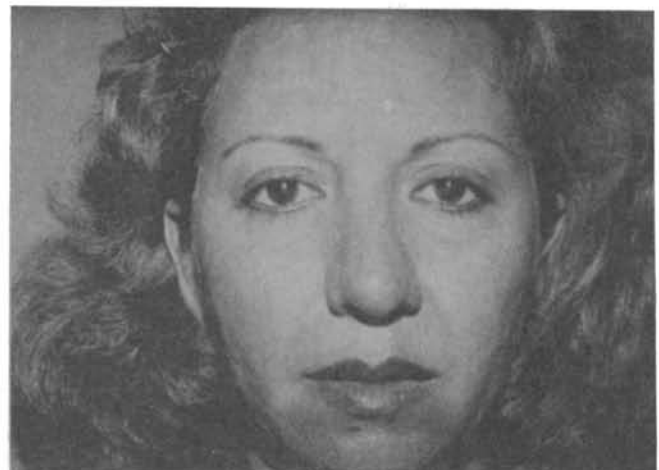**Figure 2A** - Preoperative aspect, with pincered endonasal



**Figure 2B** - Conchal cartilages carved, reproducing alar cartilage form



**Figure 2C** - Aspect of the graft sutures in the medial stump of the alar cartilages



**Figure 2D** - Final aspect of the endonasal, 6 months after surgery

2. In the excessive and total resection cases, we recur on to grafts of the remaining alar cartilages, septal cartilages or conchal ones.

We frequently obtain leftover fragments from the more lateral portion, that are dissected and sutured to the portion where an excessive resection has been done. Suture is done with monofilar nylon thread 6.0 (Fig.1 A,B,C and D).

When septal cartilage is chosen, we use fragments of approximately 2.5 x 1 cm, carved to reproduce the alar cartilage (Fig. 3 A,B,C,D,E,F,G). Carefully, cartilage is divided in its whole espessure. We observe that the 2 sheets obtained present a convexity, rigorously in the same format as the alar cartilages (Fig.3 A and B).

These cartilage sheets are sutured on the remaining cartilage stump (Fig.3 C,D,F).

In order to get symmetric and, mainly, the same resistance, stumps must be withered to the same level, so as the suture graft. This procedure avoids distortion and unevenness of the future endonasal.

Conchal graft is obtained through a retroauricular incision and wide detachment of the conchal cartilage. Two convex and symmetric portions are chosen and properly withered. Conchal cartilages, being very thick, need to be carved, mainly in the edges, where they are slender (Fig.2 A,B,C,D).

In some cases, in order to avoid very large ends, some incisions may be done to decrease the spring resistance.

## RESULTS

Endonose was restored in all of the surgeries performed. Small asymmetry was observed in 2 cases. In one of them, where a simultaneous dorsal grafting was performed, an infection occurred, but was satisfactorily solved by antibioticotherapy.

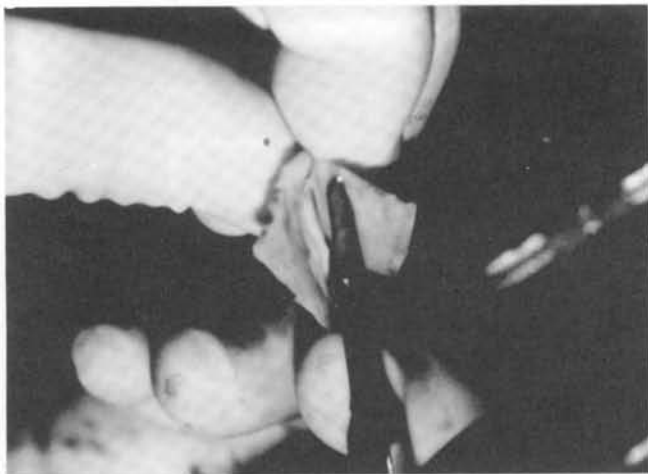
## DISCUSSION

Rhinoplasty with external incision introduced new aspects in the treatment of secondary nose deformations, mainly in what refers to the endonose structural

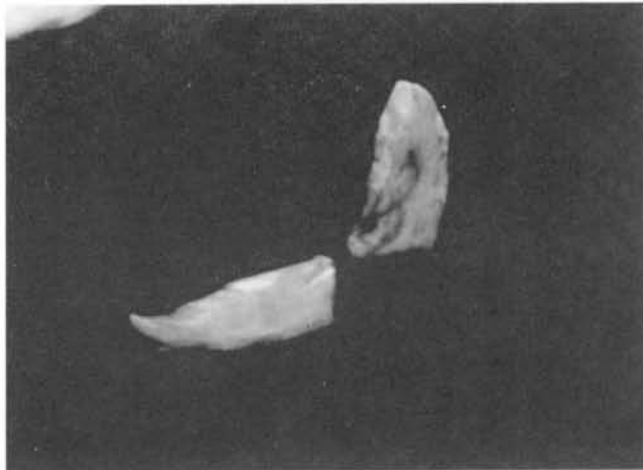components. Complete view of elements "in situ" enables precise anatomic diagnosis and the large exposition of the surgical area enables surgical proceedings, difficult to be performed by the endonasal usual ways. Assessment of losses and cartilage graft on the wings can be done symmetrically.

The three methods applied for the endonasal restoration showed to be very efficient. In small failures, use of small fragments obtained from leftovers of the allar cartilage itself, in terms of results, was the easiest method and the best one, due to the structure and characteristics of this cartilage.

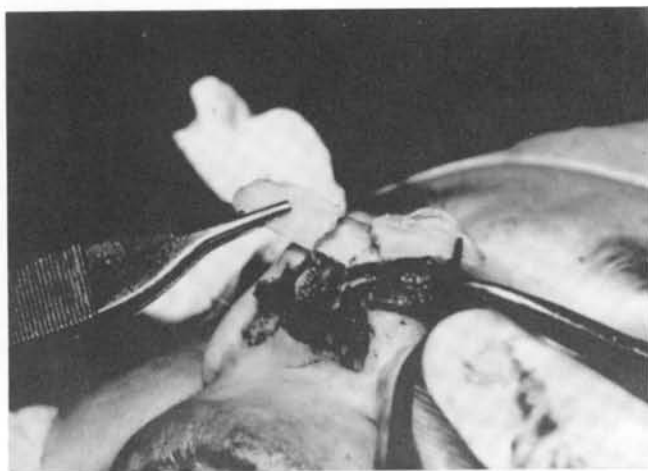
Conchal cartilage, due to higher thickness and less flexibility, even modulable, resulted in a slightly bulbous and firm endonasal.



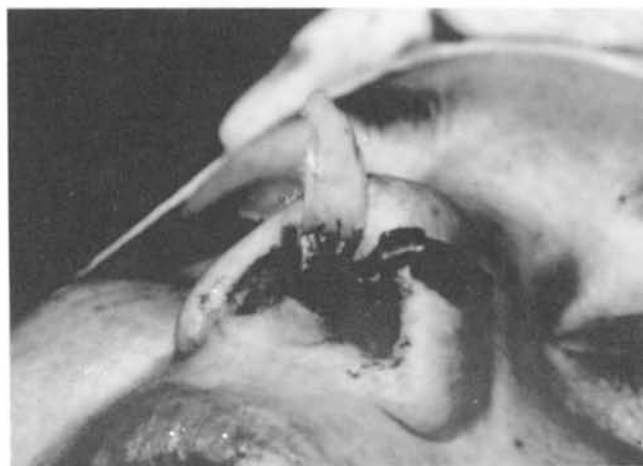**Figure 3A** - Fragment of septal cartilage being bipharted to obtain cartilage graft for the wing of the nose. The two cartilage sheets show side curve tendency, becoming convexed



**Figure 3B** - Septal cartilage divided in the middle, showing the convex form they acquire



**Figure 3C** - Aspect of endonasal placing, being prepared for suture



**Figure 3D** - Septal cartilage sutured to medial cross of the alar cartilage

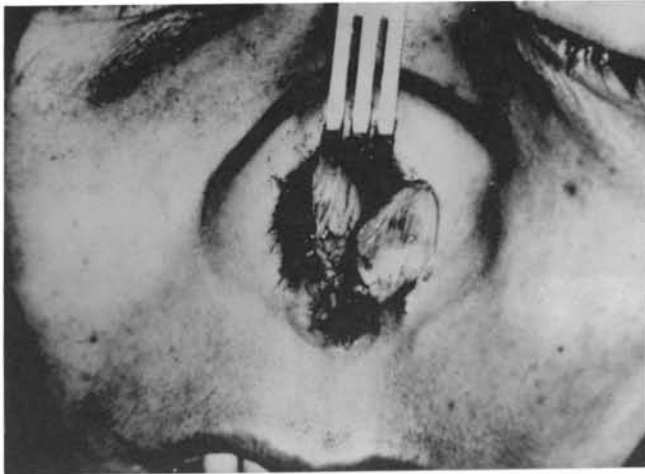


Figure 3E - Aspect after the graft suture on the cartillageous stump

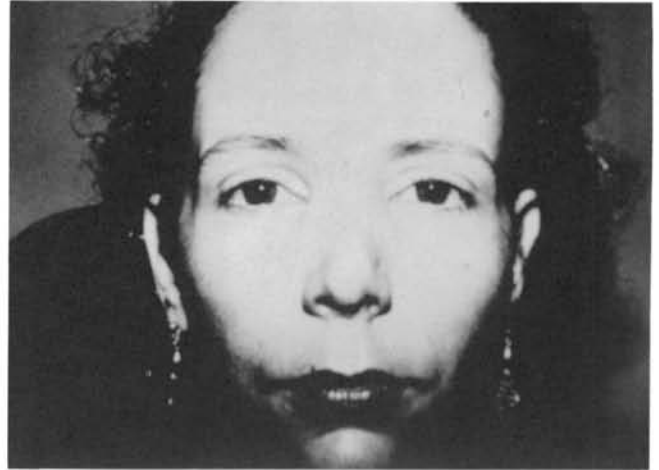

Figure 3F - Preoperative aspect of patient showing the endonasal pincement. Cartilage missing on the lateral area

## RESUMO

**Objetivo:** Apresentação de 62 casos de deformidades nasais secundárias tratados por incisão externa. **Resultados e Conclusão:** Foram verificadas diversas formas de deformidades de ponta, que foram classificadas e reparadas. Quando foi constatada ressecção excessiva utilizamos enxerto de cartilagem local, enxerto de septo ou cartilagem conchal.

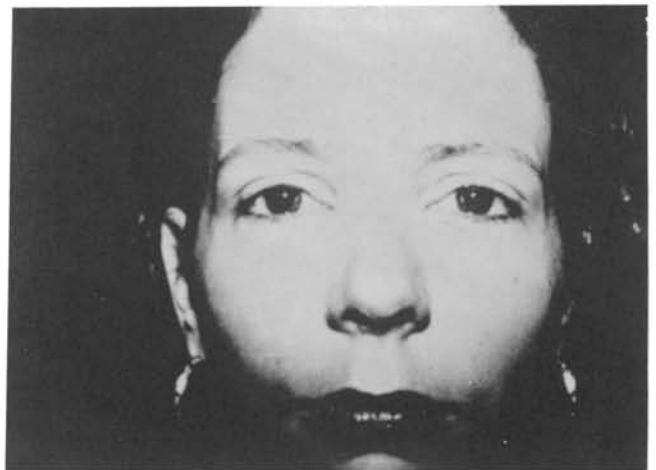

Figure 3G - Postoperative aspect, after restoration with septal cartilage grafting

## REFERENCES

1. GOODMAN, W.S. - External approach to rhinoplasty. *Can J Otolaryngol* 2:207, 1973.
2. GOODMAN, W.S. - Recent advances in external rhinoplasty. *J Otolaryngol* 10:433., 1981.
3. PADOVAN, I. - External approach to rhinoplasty (decortication) *Ann Otol Rhinol Laryngol* 3-4: 354, 1966.
4. RETHI, A. - Operation to shorten an excessively long nose. *Rev Chir Plast* 2:85, 1934.
5. SERCER, A.: - Dekortication der Nase. *Chir Maxillofac Plast* 1:149, 1958.
6. SHEEN, J. - *Aesthetic Rhinoplasty*. Mosby, 1987.