

Antonio Santos Martins, Giuliano Molina de Melo
Alfio José Tincani, Henriette Toledo Lage,
Patrícia Sabino de Matos

Papillary carcinoma in a thyroglossal duct: case report

Head and Neck Service, Department of Surgery, Faculty of Medical Sciences,
Universidade Estadual de Campinas, Campinas, Brazil

ABSTRACT

INTRODUCTION

CONTEXT: Thyroglossal duct cysts are the most common congenital cervical abnormality in childhood. Malignant lesions are rare in thyroglossal duct cysts (about 1%).

OBJECTIVE: To report a case of papillary carcinoma in thyroglossal duct cysts.

DESIGN: Case report.

CASE REPORT: The patient was a 21-year-old female with a four-month history of an anterior midline neck mass but without other symptoms. The physical examination revealed a 4.0 cm diameter, smooth, painless, cystic nodule at the level of the hyoid bone. The thyroid gland was normal by palpation and no neck lymph nodes were found. Indirect laryngoscopy, fine-needle biopsy aspiration and cervical ultrasound were normal and compatible with the physical findings of a thyroglossal duct cyst. The patient underwent surgery with this diagnosis, under general anesthesia, and the mass was resected by the usual Sistrunk procedure. There were no local signs of invasion of the tissue surrounding the cyst or duct at surgery. The patient was discharged within 24 hours. Histopathological examination of the specimen showed a 3.5 x 3.0 x 3.0 cm thyroglossal cyst, partially filled by a solid 1.0 x 0.5 cm brownish tissue.

Histological sections showed a papillary carcinoma in the thyroid tissue of a thyroglossal cyst, with normal thyroid tissue at the boundary of the carcinoma. There was no capsule invasion and the margins were negative. The follow-up of the patient consisted of head and neck examinations, ultrasonography of the surgical region and thyroid, and total body scintigraphy. The patient has been followed up for two years with no further evidence of disease.

KEY WORDS: Thyroglossal duct cyst. Papillary carcinoma. Surgery.

The thyroid gland begins to develop on the 24th day of embryogenesis and is identifiable as a segment of mesodermal cells in the floor of pharynx, between the first and second pouches. The gland subsequently descends on an S-shaped path anterior to the trachea and reaches the thyroid cartilage by the 7th week. During this descent, the connection between the thyroid gland and the floor of the pharynx (foramen cecum) may persist to form a thyroglossal duct. Secretions by the cells lining the remnant duct form thyroglossal duct cysts. Thyroglossal duct cysts are the most common congenital cervical abnormality in childhood, with a frequency of 70% and about 7% in adults.¹ The condition is more common in women than in men (1.5:1 ratio). About 1% of the thyroglossal duct cysts are histologically malignant, but the prognosis is generally good.²

We describe a case of papillary carcinoma in a thyroglossal duct cyst, and discuss the current opinions concerning management of the thyroid gland.

CASE REPORT

The patient was a 21-year-old female with a four-month history of an anterior midline neck mass

but without other symptoms. The physical examination revealed a 4.0 cm diameter, smooth, painless, cystic nodule at the level of the hyoid bone. The thyroid gland was normal by palpation and no neck lymph nodes were found. Indirect laryngoscopy, fine-needle biopsy aspiration (FNA) and cervical ultrasound were normal and compatible with the physical findings of a thyroglossal duct cyst.

The patient underwent surgery with this diagnosis, under general anesthesia, and the mass was resected by the usual Sistrunk procedure. There were no local signs of invasion of the tissue surrounding the cyst or duct at surgery. The patient was discharged within 24 hours.

Histopathological examination of the specimen showed a 3.5 x 3.0 x 3.0 cm thyroglossal cyst, partially filled by a solid 1.0 cm x 0.5 cm brownish tissue. Histological sections showed a papillary carcinoma in the thyroid tissue of the thyroglossal cyst, with normal thyroid tissue at the boundary of the carcinoma. There was no capsule invasion and the margins were negative (Figures 1 and 2).

The follow-up of the patient consisted of head and neck examinations, ultrasonography of the surgical region and thyroid, and total body scintigraphy. The patient has been followed up for two years with no further evidence of disease.

DISCUSSION

Thyroglossal duct cyst carcinoma has been reported in just over 200 cases. Previous exposure to radiation has been described as a predisposing factor. The incidence of thyroglossal duct cyst carcinoma varies from 0.7 to 1% of thyroglossal duct cyst.^{1,3}

The most common symptom is the presence of an anterior neck mass indistinguishable from those of thyroglossal duct cysts. However, neoplasia must be suspected in cases of thyroglossal duct cyst with recent changes in the clinical features. Imaging tests (ultrasound, computer tomography) do not allow a preoperative diagnosis and fine needle aspiration yields a correct result in only 66% of the cases.⁴

The histological diagnosis of thyroglossal duct cyst carcinoma requires the presence of malignant cells and also the presence of normal

thyroid tissue within the cyst. Joseph & Komorowski² proposed criteria for the unequivocal diagnosis of thyroglossal duct cyst carcinoma which included: the presence of carcinoma in the duct or cyst, combined with squamous epithelium lining and normal thyroid follicle nests in the duct or cyst wall; and the presence of a normal thyroid gland. In addition, the diagnosis must distinguish between thyroglossal duct cyst carcinoma and metastasis from primary thyroid papillary carcinoma localized in the pyramidal lobe (which may have spread to the duct),⁵ and must also identify primary pyramidal lobe carcinoma without invasion of the duct.

The most common histological types of thyroglossal duct cyst carcinoma are papillary carcinoma (80%), mixed follicular-papillary carcinoma (8%), squamous cell carcinoma (6%), follicular carcinoma (3%), adenocarcinoma, and various unclassified tumors (3%).⁵ Medullar carcinoma has not been reported in thyroglossal duct cyst whereas anaplastic carcinoma is rare.³

The appropriate surgical treatment for thyroglossal duct cyst carcinoma is the Sistrunk procedure,¹ with a reported cure rate of 95%.³ However, Kristensen et al⁶ mentioned that there should be no extension of the tumor through the cystic wall and no lymph node involvement, in order to increase the safety of this procedure. These criteria have also been adopted by

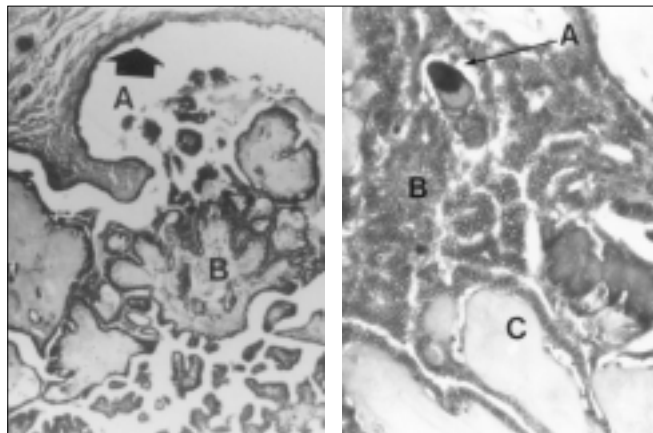


Figure 1 - Photomicrograph of the thyroglossal duct cyst capsule (A) and papillary carcinoma within the cyst (B). Hematoxylin/Eosin staining. 50X.

Figure 2 - Photomicrograph of a psammoma body (A); a cluster of clear cells with abundant vacuolated cytoplasm (B); and thyroid follicles (C). Hematoxylin/Eosin staining. 200X.

others.^{1,2,6,7} If abnormalities are detected in the thyroid gland by palpation or ultrasound, then a thyroidectomy must be considered, particularly since the reported incidence of primary thyroid carcinoma, concomitant with thyroglossal duct cyst carcinoma is between 11 and 33%. The foci of such carcinomas are small (sizes from 0.2 cm to 1.5 cm), and are frequently not palpable or undetectable by preoperative ultrasound.^{1,3,5}

Total or subtotal thyroidectomy has been recommended if there is cystic wall invasion by the carcinoma, or if the thyroglossal duct cyst carcinoma is greater than 1.0 cm (in our case the tumor measured 1 cm x 0.5 cm), because larger lesions are more likely to behave aggressively.³ We assume that the latter authors considered the possibilities of multifocal origins and possible lymphatic spread to the thyroid, based on embryology, in order to indicate total or subtotal thyroidectomy. In such cases there is a need for additional forms of therapy in the postoperative period. Complementary postoperative treatment with radioactive iodine (ablation dose) and suppressive T4 therapy is recommended in cases of total thyroidectomy. However, this indication is equally controversial in well-differentiated thyroid cancer. Neck dissection is performed only for proven cervical node metastasis.²

The prognosis for papillary thyroglossal duct cyst carcinoma is excellent, with occurrence of metastatic lesions in less than 2% of cases, whereas squamous cell carcinoma has a dismal prognosis.¹ In the present case, in accordance with the literature,^{6,8} the follow-up was both clinical and radiological, with no additional treatment. After two years the patient shows no evidence of disease.

In summary, resection of the thyroglossal duct

cyst carcinoma by the Sistrunk procedure¹ is an adequate surgical approach.

REFERENCES

1. Fernandez JF, Ordoñez NG, Schultz PN, Samaan NA, Hickey RC. Thyroglossal duct carcinoma. *Surgery* 1991;110:928-35.
2. Joseph TJ, Komorowski RA. Thyroglossal duct carcinoma. *Hum Pathol* 1975;6:717-29.
3. Heshmati HM, Fatourehchi V, Heerden JA, et al. Thyroglossal duct carcinoma: report of 12 cases. *Mayo Clin Proc* 1997;72:315-9.
4. Bardales RH, Suhrland MJ, Korourian S, et al. Cytologic findings in thyroglossal duct carcinoma. *Am J Clin Pathol* 1996;106:615-9.
5. Weiss SD, Orlich CC. Primary papillary carcinoma of a thyroglossal duct cyst: report of a case and literature review. *Br J Surg* 1991;78:87-9.
6. Kristensen S, Juul A, Morsener J. Thyroglossal cyst carcinoma. *J Laryngol Otol* 1984;98:1277-80.
7. Martin-Perez E, Larranaga E, Minon C, Monge F. Primary papillary carcinoma arising in a thyroglossal duct cyst. *Eur J Surg* 1997;163:143-5.
8. Novellino P, Iglesias ACRG, Filho PEP, Oliveira CAB. Carcinoma of the Thyroglossal duct cyst. *Rev Col Bras Cir* 1995;22(1):56-9.

Antonio Santos Martins - MD. Chief, Head and Neck Service, Department of Surgery – Faculty of Medical Sciences, State University of Campinas. Campinas, Brazil.
Alfio José Tincani - Assistant Professor, Head and Neck Service, Department of Surgery – Faculty of Medical Sciences, State University of Campinas. Campinas, Brazil.
Giuliano Molina de Melo - Resident, Head and Neck Service, Department of Surgery – Faculty of Medical Sciences, State University of Campinas. Campinas, Brazil.
Henriette Toledo Lage - Assistant Professor, Head and Neck Service, Department of Surgery - Faculty of Medical Sciences, State University of Campinas. Campinas, Brazil.
Patrícia Sabino de Matos - Assistant Professor, Pathology Department, Faculty of Medical Sciences, State University of Campinas. Campinas, Brazil.

Sources of funding: Not declared

Conflict of interest: Not declared

Last received: 2 February 1999

Accepted: 8 March 1999

Address for correspondence:

Antonio Santos Martins
 Rua Roxo Moreira, 1.234 - Cidade Universitária
 Campinas/SP - Brasil - CEP 13083-591
 E-mail: asmartin@mpc.com.br

RESUMO

CONTEXTO: Cisto de ducto tireoglosso é a anormalidade cervical congênita mais comum da infância. As lesões malignas de cisto de ducto tireoglosso são raras (cerca de 1%). **OBJETIVO:** Apresentar um relato de caso de um carcinoma papilífero originado em um cisto do ducto tireoglosso. **TIPO DE ESTUDO:** Relato de caso. **RELATO DE CASO:** Relatamos o caso de uma paciente de 21 anos com cisto de ducto tireoglosso, operada pelo método de Sistrunk, com punção aspirativa por agulha negativa para neoplasia. A histologia firmou o diagnóstico de carcinoma papilífero, com margens livres. Optou-se por não realizar tireoidectomia total ou parcial complementar, devido a não invasão da cápsula do cisto pelo tumor e pela ausência de lesões no parênquima tireoideano. No seguimento de dois anos a paciente não mostrou evidência de doença. São discutidas opiniões da literatura quanto à conduta referente à glândula tireoide.
PALAVRAS-CHAVE: Cisto ducto tireoglosso. Carcinoma papilífero. Cirurgia.