



Avian Mycoplasmosis Update

■ Author(s)

Nascimento ER*¹
Pereira VLA¹
Nascimento MGF²
Barreto ML³

- ¹ Departamento de Saúde Coletiva Veterinária e Saúde Pública. Faculdade de Veterinária Universidade Federal Fluminense - UFF
- ² Embrapa Agroindústria de Alimentos, Rio de Janeiro, RJ
- ³ Graduate student in Veterinary Medicine - Higiene Veterinária e Processamento de Produtos de Origem Animal, UFF, Niterói, RJ

■ Mail Address

Elmiro Rosendo Nascimento
UFF - Faculdade de Veterinária
Rua Vital Brazil Filho, 64, Vital Brazil
24.230-340. Niterói, RJ, Brazil
Tel.: +55 +21 2629-9532/9536
Fax: +55 +21 2629-9515

E-mail: elmiro@vm.uff.br

■ Keywords

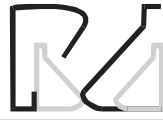airsacculitis, diagnosis, Mycoplasma, Mollicutes, poultry.

ABSTRACT

Avian mycoplasmas occur in a variety of bird species. The most important mycoplasmas for chickens and turkeys are *Mycoplasma gallisepticum* (MG), *M. synoviae* (MS), and *M. meleagridis*. Besides, *M. iowe* (MI) is an emerging pathogen in turkeys, but of little concern for chickens. Mycoplasmas are bacteria that lack cell wall and belong to the class Mollicutes. Although they have been considered extracellular agents, scientists admit nowadays that some of them are obligatory intracellular microorganisms, whereas all other mycoplasmas are considered facultative intracellular organisms. Their pathogenic mechanism for disease include adherence to host target cells, mediation of apoptosis, innocent bystander damage to host cell due to intimate membrane contact, molecular (antigen) mimicry that may lead to tolerance, and mitotic effect for B and/or T lymphocytes, which could lead to suppressed T-cell function and/or production of cytotoxic T cell, besides mycoplasma by-products, such as hydrogen peroxide and superoxide radicals. Moreover, mycoplasma ability to stimulate macrophages, monocytes, T-helper cells and NK cells, results in the production of substances, such as tumor necrosis factor (TNF- α), interleukin (IL-1, 2, 6) and interferon (α , β , γ). The major clinical signs seen in avian mycoplasmosis are coughing, sneezing, snicks, respiratory rales, ocular and nasal discharge, decreased feed intake and egg production, increased mortality, poor hatchability, and, primarily in turkeys, swelling of the infraorbital sinus(es). Nevertheless, chronic and unapparent infections are most common and more threatening. Mycoplasmas are transmitted horizontally, from bird to bird, and vertically, from dam to offspring through the eggs. Losses attributed to mycoplasmosis, mainly MG and MS infections, result from decreased egg production and egg quality, poor hatchability (high rate of embryonic mortality and culling of day-old birds), poor feed efficiency, increase in mortality and carcass condemnations, besides medication costs. Mycoplasmas are diagnosed by serologic tests, culture and PCR and are sensitive to antimicrobials whose action sites are other than the bacterial cell wall, such as tetracyclines, macrolides, quinolones and tiamulin. However, mycoplasma control is more efficiently achieved by acquisition of birds free of MG, MS, MM and/or MI, vaccination of layers, and monitoring of breeder flocks, followed by elimination of the infected flocks that are detected.

INTRODUCTION

The microorganisms of the class Mollicutes (*Mycoplasma*) were first identified in 1898 as the etiologic agent of the bovine contagious pleuropneumonia (BCPP) and thereafter, all similar agents were named pleuropneumonia-like (PPLo-like) organisms (Davis *et al.*, 1973). Avian



mycoplasmosis was primarily described in turkeys in 1926, and in chickens in 1936 (Charlton *et al.*, 1996). Delaplane & Stuart (1943) referred to it as chronic respiratory disease (CRD) of poultry. Markham & Wong (1952) associated the etiologic agent of CRD to the pathogen responsible for the infectious sinusitis of turkeys. It was then considered as a member of the PPLO group and later named as *Mycoplasma gallisepticum* (MG) (Yoder Jr., 1991b).

Infectious synovitis caused by *Mycoplasma synoviae* (MS) was described thereafter (Olson *et al.*, 1956; Kleven *et al.*, 1991; Kleven, 1997). The first reports of MS infection with arthritic involvement date from the decades of 50 and 60 in broiler flocks, but it was only in the 70's that the respiratory disease caused by MS was described (Rosales, 1991).

The first evidence of airsacculitis in day-old poult by mycoplasmas other than MG was obtained by Adler *et al.* (1958), who named this new mycoplasma "N strain". It was later called *Mycoplasma meleagridis* (MM), a mycoplasma that infects turkeys and other birds, but not chickens (Yamamoto, 1991).

Mycoplasma iowae (MI), considered an emerging pathogen and a mycoplasma of natural occurrence in turkeys, has also been reported in chickens and other birds. It was first diagnosed as the Iowa 695 strain (Yoder Jr. & Hofstad, 1962) and characterized later (Jordan *et al.*, 1982). MI and other mycoplasmas, including *M. iners*, *M. gallinarum*, *M. pullorum*, *M. gallopavonis*, *M. gallinaceum*, *M. columbinasale*, *M. columbinum*, *M. columborale*, *M. lipofaciens*, *M. glycophilum*, *M. cloacale*, *M. anseris*, *Uraaplasma galorale*, and *Acholeplasma laidlawii*, are not pathogens of major concern to the poultry industry because of very low, or even lack of, pathogenicity (Nascimento, 2000). The same applies to *M. immitans*, which cross reacts serologically with MG, but has not yet been isolated from poultry (Fiorentin, 2004). Therefore, this review will focus on MG and MS infections and, to a less extent, to MM infection.

ETIOLOGY AND PATHOGENICITY

Mycoplasma is a trivial designation to the prokaryotes belonging to the class Mollicutes (mollis=soft and cutes=skin), i.e., bacteria that lack cell wall, which make them resistant to antimicrobials that act on this cell structure, such as penicillin. They have been considered extracellular agents, but scientists nowadays admit that some of them are obligatory intracellular parasites, whereas all other mycoplasmas

are facultative intracellular organisms (Razin *et al.*, 1998). More detailed information on mycoplasma taxonomy and pathogenicity can be found elsewhere (Yamamoto, 1990; Razin *et al.*, 1998; Nascimento, 2000).

In order to survive within the host organism, induce disease and evade the host immune system, mycoplasmas use some pathogenicity tools and mechanisms. These include adherence to host target cells, mediation of apoptosis, innocent bystander damage to host cell due to intimate membrane contact, molecular (antigen) mimicry that may lead to tolerance, and mitotic effect for B and/or T lymphocytes, which could lead to suppressed T-cell function and/or production of cytotoxic T cell, besides mycoplasma by-products, such as hydrogen peroxide and superoxide radicals. Moreover, mycoplasma ability to stimulate macrophages, monocytes, T-helper cells and NK cells, results in the production of substances, such as tumor necrosis factor (TNF- α), interleukin (IL-1, 2, 6) and interferon (α , β , γ). These mechanisms may explain the transient suppression of humoral and cellular immune responses during mycoplasma infection in birds, the immune tolerance and auto immune diseases, as well as the massive lymphoid cell infiltration in the respiratory tract and joint tissues of infected fowls (Razin & Tully, 1995; Yamamoto, 1990; Razin *et al.*, 1998).

Besides these mechanisms that may be used by MG, MS and MM, latency is common to avian mycoplasmas. Thus, these pathogens induce disease after the host is affected by other disease-causing agents such as bacteria and viruses and/or after an episode of host weakness (Yoder Jr, 1991a; Whitford *et al.*, 1994). The latent status, i.e., when the mycoplasma is not recognized by the host immune system, may be explained by its intracellular location due to environmental pressure, as can be exemplified by the presence of antimicrobials in host tissues for the treatment of MG, MS or MM infection of birds (Razin *et al.*, 1998). Recent experimental evidences that MS causes immune depression by affecting the chicken cellular and humoral immune system have been found when complete hemogram was analyzed in chicks submitted to four conditions: negative control, Newcastle disease-vaccinated (ND-vaccinated), MS-infected, and MS infection plus ND vaccination (Nascimento *et al.*, 2003; Silva, 2003).

Moreover, mycoplasmas are more susceptible to mutations than other bacteria (Woese *et al.*, 1985), and this can be explained by their defective DNA repair system, as demonstrated in the case of MG (Ghosh *et*



al., 1977). The frequent changes on surface antigens (antigenic variations) allow mycoplasmas to evade the host immune system, and facilitate their survival when adhered to the host respiratory tract, as noticed for MG (Markhan *et al.*, 1994). Cytadherence and/or cytoadhesin membrane surface proteins that undergo changes are represented by pMGAs (hemagglutinins), MGC1, MGC2 and PvpA for MG, and MSPA and MSPB for MS (Razin *et al.*, 1998; Bencina, 2002).

SYMPTOMS AND LESIONS

The classic diseases caused by avian mycoplasmas are: CRD, an upper respiratory disease primarily seen in chickens and infectious sinusitis of turkeys, caused by MG; and infectious synovitis, caused by MS, and airsacculitis caused by MG, MS and MM. However, chronic and asymptomatic infections are the most common and of a major concern, due to the losses they cause (Yoder Jr, 1991a).

The clinical manifestations of MG are coughing, sneezing, snicks, rales, ocular and nasal discharge, decrease in feed consumption and egg production, increased mortality, poor hatchability, and, primarily in turkeys, swelling of the infraorbital sinus(es). In chickens, turkeys and other birds, a milder form of some of these symptoms can be seen in MS infections, besides lameness, pale comb and head, swollen hocks and foot pad. Acutely affected birds may show green feces, but respiratory infection caused by MS is usually asymptomatic. Most of the symptoms of MM infection are mild or unapparent, and are characterized by impaired hatchability and embryo pipping, increased embryo mortality, poor weight gain, and, occasionally, the same symptoms are seen in chickens affected by MS (Charlton *et al.*, 1996).

Gross lesions in birds with mycoplasmosis include catarrhal inflammation of sinuses, trachea, and bronchi. Air sacs are often thickened and opaque, and may contain mucous or caseous exudate, besides hyperplastic lymphoid follicles on the walls. At slaughter, carcass condemnation may result from the presence of airsacculitis, fibrinous perihepatitis and adhesive pericarditis; interstitial pneumonia and salpingitis, which are often seen in chickens and turkeys (Yamamoto, 1991; Charlton *et al.*, 1996).

The observed histological alterations are mononuclear cell infiltration, mucosal glandular hyperplasia and lymphoid follicular reaction, with tendency to affect also the connective tissue. In the lungs, it can be observed interstitial pneumonia,

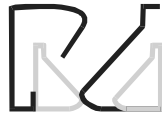lymphoid follicular reactions and, less frequently, granulomas (Yoder Jr., 1991b; Ficken, 1996; Lay & Yoder Jr. 1997; Rodrigues *et al.*, 2001). Air sacs are affected mostly due to the physiology of the avian respiratory system, in which part of the inspired air goes first through the bronchi to this serosa and afterwards to the lungs (Nascimento, 2000).

TRANSMISSION AND HOSTS

Mycoplasmas may be transmitted horizontally, through infectious aerosols coughed and sneezed by infected birds and through contaminated feed, water, contact personal and communicant animals, mainly birds. Transmission occurs vertically from parents to their offspring, through contamination of laid eggs (transovarian transmission), as previously mentioned (Charlton *et al.*, 1996). Mycoplasma is commonly transmitted within species and/or between closely related species, that is, they are host-specific, with rare exceptions (Nascimento, 2000). MG and MS infections occur mostly in chickens and turkeys. However, they have been frequently isolated from quails (*Coturnix coturnix*) as reported previously (Nascimento & Nascimento, 1986; Nascimento *et al.*, 1997; Nascimento *et al.*, 1998), and from several avian species (Stipkovitis & Kempf, 1996; Lobão *et al.*, 2003). MM can infect other avian species, but reports on isolation from Japanese quails, peacocks and pigeons have not been confirmed (Yamamoto, 1991; Stipkovitis & Kempf, 1996).

ECONOMIC IMPORTANCE

Losses attributed to mycoplasmosis, mainly MG infection, are due to decrease in egg production and egg quality, poor hatchability (high rate of embryonic mortality and culling of day-old birds), poor feed efficiency, increase in mortality and carcass condemnations, besides medication costs (Mohammed, *et al.*, 1987; Yoder Jr, 1991b; Lay & Yoder Jr, 1997). According to previous studies, a MG-infected chicken lays 15.7 eggs less than a healthy one, contributing to a loss of 127 million eggs in the USA in 1984, which corresponded to an annual loss of 125 million dollars (Mohammed *et al.*, 1987). In Brazil, using slaughter data from the Federal Inspection Service, there was a loss of 34 thousand tons of broilers in the end of the production cycle due to respiratory diseases, which corresponded to 30 million dollars in 1994 (Projeto, 1994). Particularly for MS, losses have been attributed



to transient immune depression, increase of 1 to 4% in the mortality rate of broilers in the final phase of production (Shapiro, 1994), decrease of 5 to 10% in egg production and 5 to 7% in hatchability (Mohammed *et al.*, 1987; Stipkovits & Kempf, 1996). Moreover, MG infection alone is considered one of the diseases that cause more losses to the poultry industry (Yoder Jr, 1991b; Charlton *et al.*, 1996; Lay & Yoder Jr, 1997).

In Brazil, the prevalence of MS in chicken flocks is increasing since the 80's, overcoming that of MG in breeding flocks (Balén & Fiorentin, 1990). Although MS is mostly involved in asymptomatic infections and sometimes considered harmless to chickens, it is pathogenic for birds (Stipkovits & Kempf, 1996). Besides, MS has been proven to affect the humoral response of chicks vaccinated with a La Sota strain of Newcastle disease virus (ND). Hemagglutination inhibition protection values for Newcastle (ND HI) (GMT ≥ 4.0 , titer $\geq 1:16$) were detected in non-MS-infected birds up to 45 days after a single ND vaccination, but not in birds that were MS-infected and ND-vaccinated. Protection of MS-infected broilers was induced only after a second dose of vaccine (Nascimento *et al.*, 2003; Silva, 2003).

DIAGNOSIS

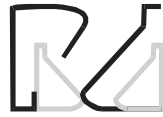Serologic tests commonly used are seroagglutination reaction (SAR) and hemagglutination inhibition (HI), which can be followed by isolation and identification, and PCR. Agglutination can also be performed with egg yolk samples and results are considered positive, suspicious and negative for titers equal or higher than 1:10, 1:5 and lower, than 1:5, respectively (Yoder Jr., 1991b; Brasil, 1994; USA, 1997). However, there has been situations in which birds were considered negative by SAR (titer $< 1:5$), but positive by HI (Nascimento *et al.* 1999b). On the other hand, under experimental conditions, chickens exposed to live vaccines (TS11 and 6/85) and low virulent MG strains showed seroconversion as measured by SAR, but only when serum samples were not diluted (Nascimento, 2002). Considering that HI titers equal or higher than 1:80 are regarded as positive and titers between 1:20-1:40 are suspicious, whereas negative titers are below 1:20 (Brasil, 1994; USA, 1997). Nevertheless, results of 1:40 are fairly common in most of the tested birds in observational studies (Nascimento *et al.*, 1999b). Consequently, HI interpretation should be standardized, and positivity for MG and MS should consider a cut-off point of 1:40, as previously suggested for MG (Kleven, 1994a; Mendonça *et al.*, 2001).

Other serologic tests can also be used. ELISA is the most promising technique to substitute SAR (Stipkovits & Kempf, 1996) or even HI (USA, 1997), but according to a previous field study (Nascimento *et al.*, 1999b), ELISA and SAR evidenced negative results whereas HI and PCR were positive. On the contrary, SPF chickens exposed to live vaccines (MG-F, MGTS-11 and 6/85) and a low virulent MG strain (MG-70) were positive in ELISA as early as 21 days post exposure. Positivity for MG-F in exposed chickens was detected by SAR and HI only at 35 and 42 days post-exposure, respectively, whereas positivity for the other MG strains (TS11 6/85 and MG-70) in SAR and HI could be detected only after challenge with MG-R, at 63 days post exposure (Nascimento *et al.*, 1999b).

Serologic diagnosis can be influenced by a number of factors. It is worth noting that pullets exposed to two vaccinations responded serologically better by SAR and HI than those exposed to a single vaccination, regardless of the vaccine used (Polo *et al.*, 2002), although this was not related to protection. Furthermore, commercial layers vaccinated twice with MG-F and infected with wild MG yielded the highest titers (HI and SAR) and percentage of positive birds. Birds vaccinated and infected with MG had intermediate titers, and non-vaccinated birds infected with MG had the lowest titers. These results indicated that the serologic response was higher when birds were exposed more times to vaccine and/or wild MG strains (Mendonça *et al.*, 2001).

Disagreeing results of the same and/or different serologic tests may be ascribed to changes in mycoplasma surface antigens due to mutations (Ghosh *et al.*, 1977; Razin *et al.*, 1998). Cross-reactions between MG and MS were not seen under controlled experimental conditions (Nascimento *et al.*, 1998; Nascimento *et al.*, 2002; Silva *et al.*, 2003), indicating that this phenomenon depends on environmental conditions. These conflicting reports on serologic test results, favor the idea of considering the SAR reaction at undiluted sera as suspicious result, and the adoption of 1:40 HI title as positive diagnosis

Mycoplasma can be detected in tissue fragments of affected organs like trachea, air sacs and lungs. Besides synovial, ocular and infraorbital sinus exudates, good sources are swabs from trachea and air sacs, and pipped embryos (Yamamoto, 1991; Yoder Jr, 1991b; Lay & Yoder Jr, 1997; Nascimento *et al.*, 1994). Swabs from trachea and choanal cleft constitute excellent specimens, mainly for isolation or PCR, which are used as confirmation tools for monitoring MG and



MS infections in live birds (Kleven, 1994b; Nascimento ER *et al.*, 1998; Brasil, 2001). Cloacal swabs are preferred for MM and MI assessment, but it can also be used for MG diagnosis. Culturing of specimens from culled and pipped embryos increase the chance of agent detection, and should be used in the monitoring of breeding flocks (USA, 1997). Samples collected for culture or PCR can be placed in a 50% solution of Frey's medium or phosphate buffered saline (pH 7.8) in glycerol and kept in freezer before being processed (Nascimento & Nascimento, 1984; Mendonça *et al.*, 2000; Polo *et al.*, 2002).

PCR detection was primarily developed for MG (Nascimento & Yamamoto, 1991; Nascimento *et al.*, 1991, 1993) and was accepted worldwide for detection of all avian mycoplasmas, either in specific DNA amplification for diagnosis (Lauerman, 1998; Nascimento *et al.*, 1998) or in nonspecific DNA banding pattern (RAPD) for strain identification (Fan *et al.*, 1995). The drawback of nonspecific amplification is that it requires previous culturing for purification and cloning of the putative mycoplasma isolate. An alternative to the nonspecific PCR procedure for strain identification is the direct sequencing of the amplified products (amplicons) from a specific PCR with primers directed to the 16S rRNA gene (Ward *et al.*, 1990), but this technique requires sophisticated laboratories. Besides, the technique still needs optimization and it is not yet available for avian mycoplasmas. Sequencing is more accessible nowadays and mycoplasma sequencing, including MG, has been facilitated because they have such a small genome (Papazisi *et al.*, 2003).

Gross and microscopic examinations have been used to help the diagnosis of avian mycoplasmosis in naturally infected birds and are similar to the lesions described in experimentally infected birds (Yoder Jr., 1991b; Lay & Yoder, 1997). In the case of experimental CRD in broilers, with MG and *E. coli*, suggestive gross lesions were observed, denoted by edematous airsacculitis with fibrin deposition extending to pericarditis and perihepatitis. Besides, it was seen hemorrhagic tracheitis with strong mononuclear cell infiltration, obliterate bronchiolitis with mononuclear cell infiltration, diffuse airsacculitis and air sac hyperplasia with monophil and heterophil cell infiltration and multiple granulomas in the lungs rich in multinucleated giant cells, besides necrosis (Rodrigues *et al.*, 2001). MS and ND-vaccinated chicks experimentally infected with MS (WVU 1853) showed histological alterations, including nodular and diffuse airsacculitis, lymphocytic hyperplasia in trachea and

bronchi, and multifocal lymphoid cell infiltration in the lungs (Pereira, 2004).

Even MG vaccine strains are capable of inducing histopathological lesions in exposed chicks. Experimentally exposed chicks were assessed by tracheal scoring, where score 0 indicated no lesion or 1-3 discrete lymphoid aggregates (DLA) without submucosa invasion; score 0.5 indicated either 1-3 DLA with at least one invading the submucosa or more than four DLA per microscope field; score 1.0 indicated DLA associated with lymphoid aggregates in follicular pattern (LAFP) but not in the submucosa; and scores 2 to 3 were combinations of ALD and LAFP invading the submucosa in increasing intensity. Based on these criteria, at 35 days post exposure, the scores of vaccinated chickens (MG-6/85 = 1.0; MG-TS11 = 1.4; and MG-F = 1.4) were significantly higher than the scores of negative control birds (0.37) and birds vaccinated with MG-70 (0.6), which is a low virulent strain (Demarque, 2004). These findings evidence diagnosis problems that are becoming very common with the advent of live vaccines and the appearance of low virulent strains of MG, MS and MM.

TREATMENT AND IMMUNOPROFILAXIS

The treatment of mycoplasma-infected breeders with antimicrobials decreases the rate of clinical manifestations and consequently the risk of transovarian transmission to a level inferior than 0.1% (Ortiz *et al.*, 1995). Although this procedure is recommended for laying hens, it does not eliminate MG, MS or even MM from the flock (Stipkovits & Kempf, 1996). Mycoplasmas are resistant to antibiotics that act on cell wall, such as penicillin, but are sensitive to tetracyclines (oxytetracycline, chlortetracycline and doxycycline), macrolides (erythromycin, tylosin, spiramycin, lincomycin, and kitasamycin), quinolones (imequil, norfloxacin, enrofloxacin and danofloxacin) or tiamulin. Drugs that accumulate in high concentrations in the mucosal membranes of the respiratory and genitourinary tracts, such as tiamulin and enrofloxacin (Nascimento *et al.*, 1999a), are often preferred (Stipkovits & Kempf, 1996). The etiologic diagnosis of MG, MS and MM, and other mycoplasmas is compromised by these potent antimicrobials, because they block or reduce the immune response and force the mycoplasmas to evade from or hide in affected tissues, making them unavailable for detection by culture or PCR. This situation can be reverted by suspending the drug treatment, so that infective



mycoplasmas become again detectable (Kempf, 1991, Nascimento *et al.*, 1999a). This phenomenon may be explained by the intracellular location of the mycoplasma due to antimicrobial pressure, and subsequent unavailability of the agent to induce immune response (Razin *et al.*, 1998).

The protection mechanism conferred by MG and/or MS live vaccines is not fully understood, although it is known that antibodies play a role, at least in the local respiratory humoral defense (Whithear, 1996). The importance of the cell-mediated immunity has not been assessed yet (Whithear, 1996), but it also seems to have some functions in animal protection. Histopathological findings in SPF chicks experimentally exposed to five MG strains, including vaccine strains F, TS11 and 6/85, showed cell mobilization toward protection before antibodies could be detected (Demarque, 2004).

Currently, inactivated and live attenuated vaccines are available to poultry farmers. Although inactivated vaccines (bacterins only for MG) were not well accepted in the past, they are often preferred today, mainly because there is no risk of infection and because they do not affect MG detection. Live MG vaccines used nowadays are effective in reducing egg losses (Carpenter *et al.*, 1981; Yoder Jr, 1991b; Lay & Yoder Jr, 1997) and, to a certain extent, in replacing the MG field strain (Whithear, 1996). Considering the replacement of wild MG by MG-F, the vaccine did not exhibit a 100% competitive exclusion of wild MG in a field study (Mendonça *et al.*, 2000). There is no vaccine for MM infection and the live MS vaccine is not available in Brazil. On the other hand, the use of live and inactivated MG vaccines is recommended for layers and prohibited for breeders because they affect MG diagnosis and monitoring (Brasil, 1994; USA, 1997). Apart from governmental restriction, live and inactivated mycoplasma vaccines can be used for any kind of birds, and in certain circumstances, the combination of antimicrobial treatment and inactivated MG or MS vaccines is recommended (Stipkovits & Burch, 1994). Currently, there is MG and MS in oil-emulsion vaccines (Charlton *et al.*, 1996) and live MS vaccine (Whithear, 1996), but the live MS one is not used in Brazil. However, due to the natural low virulence and pathogenicity of MS, it would be difficult to prove the efficacy of these vaccines in commercial poultry.

CONTROL OF MYCOPLASMAS (MG, MS, AND/OR MM)

The first step toward mycoplasma control is

the acquisition of fertile eggs and birds (chicken, turkeys and other fowls) free from MG, MS and/or MM. Regarding genetic stocks (pure line breeders), birds free of MG, MS and/or MM have been produced by treatment of fertile eggs, such as heat treatment at 46°C for 12-14 hours or, more efficiently, by antibiotic treatment, either by in ovo injection or, by dipping eggs in antimicrobial solutions (Nascimento & Nascimento, 1994; Stipkovits & Kempf, 1996; Nascimento, 2000). Government certification programs have been successfully employed to help mycoplasma control in many countries, such as the National Poultry Improvement Plan in the USA (USA, 1997), National Sanitary and Hygienic Control Programme in France (Stipkovits & Kempf, 1996), and the National Avian Sanitary Program – PNSA in Brazil (Villa, 1998). The above mentioned health guidelines focus on the maintenance of primary, secondary and tertiary breeder flocks that are free from MG, MS and/MM. In the Brazilian PNSA, imported birds or fertile eggs are tested on arrival and breeder flocks should be monitored for MG, MS and/or MM at intervals no greater than 90 days. Monitoring is performed using SAR, ELISA and/or HI, and confirmation by mycoplasma detection, which is more easily accomplished by PCR (Brasil, 1994; Nascimento *et al.*, 1991; Nascimento *et al.*, 1994; Nascimento *et al.*, 1998; Nascimento, 2000). Assessment of mycoplasmas is performed in each breeder flock using an appropriate number of randomly chosen birds. According to PNSA guidelines, monitoring should start when pullets are 6-7 weeks old, and 300 birds should be tested for MG and 150 for MS in each flock. From the laying onset until the birds are culled, 150 birds should be tested for MG and 75 birds for MS in each flock (Brasil, 1994; 2001; Nascimento, 2000). According to the most recent Brazilian law, all breeders should be free of MG, MS and/or MM, regardless of species. Tertiary breeder flocks, which produce broiler and layer chicks to be commercialized, are still not required to be MS-free (Brasil, 2001).

REFERENCES

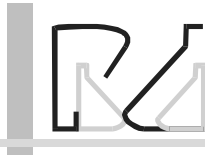
- Adler HE, Fabricant J, Yamamoto R, Berg J. Isolation and identification of pleuropneumonia-like organisms of avian origin. In: Symposium on chronic respiratory diseases of poultry. American Journal of Veterinary Research 1958; 19:440-7.
- Balen LO, Fiorentin L. O Mycoplasma synoviae e seu impacto econômico sobre a avicultura. In: Conferência Apinco 1990 de Ciência e Tecnologia Avícolas; 1990; Campinas, São Paulo. Brasil. p. 35-140.



- Bencina D. Hemmagglutinins of pathogenic avian mycoplasmas. *Avian pathology* 2002; 31:535-47.
- Brasil. Ministério da Agricultura, Pecuária e Abastecimento. Instrução Normativa Nº 44, de 23 de Agosto 2001, Brasília, Distrito Federal 2001. [Acessado em: 20 dez.2004]. Disponível em: URL: <http://www.agricultura.gov.br>.
- Brasil. Ministério da Agricultura, Pecuária e Abastecimento. Programa Nacional de Sanidade Avícola, Brasília, Distrito Federal 1994. [Acessado em: 20 dez.2004]. Disponível em: URL: <http://www.agricultura.gov.br>.
- Carpenter TE, Mallinson ET, Miller KF, Gentry RF, Schwartz LD. Vaccination with F-strain *Mycoplasma gallisepticum* to reduce production losses in layer chickens. *Avian Diseases* 1981; 25:404-9.
- Charlton BR, Bermudez AJ, Boulianne M, Eckroade RJ, Jeffrey JS, Newman LJ, Sander JE, Wakenell PS. In: Charlton BR, editor. *Avian disease manual*. Kennett Square, Pennsylvania, USA: American Association of Avian Pathologists; 1996. p.115-25.
- Davis BD, Dulbecco R, Eisen HN, Ginsberg HS, Wood WB. *Infecções bacterianas e micóticas*. São Paulo (SP): EDART; 1973.
- Delaplane JP, Stuart HO. The propagation of a virus in embryonated chicken eggs causing a chronic respiratory disease of chickens. *American Journal of Veterinary Research* 1943; 4:325-32.
- Demarque KC. *Histopatologia e morfometria da traquéia de aves (Gallus gallus) expostas a diferentes cepas de Mycoplasma gallisepticum* [dissertação]. Niterói (RJ): Universidade Federal Fluminense; 2004.
- Fan HH, Kleven SH, Jackwood MW. Application of polymerase chain reaction with arbitrary primers to strain identification of *Mycoplasma gallisepticum*. *Avian Diseases* 1995; 39:729-35.
- Ficken M. Respiratory System. In: Ridell C, editor. *Avian histopathology*. Kennett Square, Pennsylvania, USA: American Association of Avian Pathologists; 1996. p.89-109.
- Fiorentin L. Participação das Micoplasmoses nos problemas respiratórios. In: VIII Seminário Nordeste de Pecuária – PECNORDESTE; 2004; Fortaleza, Ceará. Brasil. p.57-63
- Ghosh A, Das J, Maniloff J. Lack of repair of ultraviolet light damage in *Mycoplasma gallisepticum*. *Journal of Molecular Biology* 1977; 116:337-44.
- Jordan FTW, Erno H, Cottew GS, Hinz KH and Stipkovits L. Characterization and taxonomic description of five mycoplasma serovars (serotypes) of avian origin and their elevation to species rank and further evaluation of the taxonomic status of *Mycoplasma synoviae*. *Japanese Journal of Systematic Bacteriology* 1982; 32:108-15.
- Kempf I. Influence of the administration of antibiotics on the diagnosis of *Mycoplasma gallisepticum* infection in chickens. *Point-Veterinaire* 1991; 23:767-73.
- Kleven SH, Rowland GN, Olson NO. *Mycoplasma synoviae* infection. In: Calnek BW, Burnes HJ, Beard CW, Yoder Jr. HW, editors. *Diseases of poultry*. Ames, Iowa, USA. Ames: Iowa State University Press; 1991. p. 223-31.
- Kleven SH. Avian Mycoplasmas. In: Whitford HW, Rosenbusch RF, Lauermann LH, editors. *Mycoplasmosis in animals: laboratory diagnosis*. Ames, Iowa, USA. Ames: Iowa State University Press; 1994a. p.31-8.
- Kleven SH. El Desafio de las Infecciones Respiratorias Mixtas. *Indústria Avícola* 1994b; 41:4-8.
- Kleven SH. *Mycoplasma synoviae* infection. In: Calnek BW, Burnes HJ, Beard CW,
- McDougald LR, Saif YM, editors. *Diseases of poultry*. Ames, Iowa, USA. Ames: Iowa State University Press; 1997. p. 220-8.
- Lauerman LH. *Mycoplasma* PCR Assays. In: _____. *Nucleic acid amplification assays for diagnosis of animal diseases*. Alabama, USA: Department of Agriculture and Industries; 1998.
- Lay DH, Yoder Jr. HW. *Mycoplasma gallisepticum* infection. In: Calnek BW, Barnes H, Beard CW, McDougald, LR, Saif YM. *Disease of poultry*. Ames, Iowa, USA. Ames: Iowa State University Press; 1997. p. 194-207.
- Lobão ML, Lima CBS, Nascimento ER, Santos MG, Medeiros MIM, Barreto ML, Lemos M, Silva RCF, Pereira VLA. Micoplasmoses em Avestruzes (*Struthio camelus*). In: 8ª Semana de Extensão da UFF; 2003; Niterói, Rio de Janeiro. Brasil. p.181-2.
- Markham FS, Wong SC. Pleuropneumonia-like organisms in the etiology of turkey sinusitis and chronic respiratory disease of chickens. *Poultry Science* 1952; 31:902-4.
- Mendonça GA, Nascimento ER, Lignon GB, Nascimento MGF, Danelli MGM. Efeito da vacina MG-F de *Mycoplasma gallisepticum* na soroconversão de galinhas poedeiras com sintomas respiratórios. *Revista Brasileira de Medicina Veterinária* 2001; 23 (4):160-2.
- Mendonça GA, Nascimento ER, Lignon GB, Nascimento MGF, Polo PA. PCR na detecção de *Mycoplasma gallisepticum* (MG) em galinhas poedeiras vacinadas com MG-F e com doença respiratória. *Brazilian Journal of Poultry Science* 2000; Supl. 2:83.
- Mohammed HO, Carpenter TE, Yamamoto R. Economic impact of *Mycoplasma gallisepticum* and *Mycoplasma synoviae* in commercial layer flocks. *Avian Diseases* 1987; 31:477-82.
- Nascimento ER, Nascimento MGF. Eradication of *Mycoplasma gallisepticum* and *M. synoviae* from a chicken flock in Brasil In: The 43th Western Poultry Disease Conference; 1994; Sacramento, Califórnia, USA. p.58.
- Nascimento ER, Ferreira Neto SM, Galletti MCM, Nascimento MGF, Lignon GB, Mendonça GA. Chicken *Mycoplasma gallisepticum* infection, diagnosed by agent detection, hemagglutination inhibition, but not agglutination. In: AVMA Conference/AAAP Meeting, 1999b; New Orleans, USA. p.56.



- Nascimento ER, Nascimento MGF, Danelli MGM, Machado SL, Lignon GB, Polo PA. Comparison of PCR kits for the detection of *Mycoplasma gallisepticum* and *M. synoviae* (MS) in MS infected and uninfected chickens. In: Proceedings of the 47^o Western Poultry Disease Conference; 1998; Sacramento, Califórnia, USA. p.84-86.
- Nascimento ER, Nascimento MGF, Rodrigues OP, Mendonça GA, Lignon GB, Dias SAC, Ito JY. Avaliação de antimicrobianos no tratamento da doença respiratória crônica por *Mycoplasma gallisepticum* e *Escherichia coli* em frangos de corte. Brazilian Journal of Poultry Science 1999a; Supl: p.72.
- Nascimento ER, Polo PA, Nascimento MGF, Lignon G. Isolamento de *Mycoplasma gallisepticum* e *M. synoviae* de codornas (*Coturnix coturnix japonica*). In: 25^o Congresso Brasileiro de Medicina Veterinária; 1997; Gramado, Rio Grande do Sul. Brasil. p.171.
- Nascimento ER, Polo PA, Pereira VLA, Barreto ML, Nascimento MGF, Zuanaze MAF, Scanavini-Neto H. Serologic responses and recovery of *Mycoplasma gallisepticum* in SPF vaccinated chickens. In: The Western Poultry Disease Conference; 2002; Puerto Vallarte. Mexico. p.307-308
- Nascimento ER, Silva RCF, Platenik MO, Pereira VLA, Barreto ML, Correa ARA. Effect of *Mycoplasma synoviae* infection on serologic response to Newcastle La Sota vaccine. In: 13^o Congress of the World Veterinary Poultry Association and American Association of Avian Pathologists/American Veterinary Medical Association Annual Meetin; 2003; Denver, Colorado, USA. p.65.
- Nascimento ER, Yamamoto R, Damassa AJ, Ortmayer HB, Nascimento MGF. PCR versus isolamento e sorologia no diagnóstico da infecção por *Mycoplasma gallisepticum* em galinhas e perus. In: Conferência APINCO 1994 de Ciência e Tecnologia Avícolas; 1994; Santos, São Paulo. Brasil. p.89-90.
- Nascimento ER, Yamamoto R, Herrick KR, Tait RC. Polymerase chain reaction for detection of *Mycoplasma gallisepticum*. Avian Diseases 1991; 35:62-9.
- Nascimento ER, Yamamoto R, Khan MI. *Mycoplasma gallisepticum* F-vaccine strain-specific polymerase chain reaction. Avian Diseases 1993; 37:203-11.
- Nascimento ER, Yamamoto R. Simplification of *Mycoplasma gallisepticum*-polymerase chain reaction. In: 40th of the Western Poultry Disease Conference; 1991; Sacramento, Califórnia, USA. p.94-95.
- Nascimento ER. Mycoplasmoses. In: Macari M, Berchieri Jr. A, editores. Doenças das aves. Campinas: FACTA; 2000. p.217-24.
- Nascimento MGF, Nascimento ER. Estocagem e sobrevivência de várias espécies de micoplasma à -20°C. In: 19^o Congresso Brasileiro de Medicina Veterinária; 1984; Belém, Pará. Brasil. p.307.
- Nascimento MGF, Nascimento ER. Infectious sinusitis in coturnix quails in Brazil. Avian Diseases 1986; 30:228-30.
- Nascimento MGF, Polo PA, Nascimento ER, Lignon GB. Search for *Mycoplasma gallisepticum* and *M. synoviae* in an outbreak of sinusitis and arthritis in quails. In: Proceedings of the 47^o Western Poultry Disease Conference; 1998; Sacramento, Califórnia, USA. p.83-84.
- Olson NO, Shelton DC, Bletner JK, Munro DA, Anderson GC. Studies of infectious synovitis in chickens. American Journal of Veterinary Research 1956; 17:747-54.
- Ortiz A, Froyman R, Kleven SH. Evaluation of enrofloxacin against egg transmission of *Mycoplasma gallisepticum*. Avian Diseases 1995; 39:830-6.
- Papazisi L, Gorton TS, Markham PF, Browning GF, Nguyen DK, Swartzell S, Madan A, Mahairas G, Geary JS. The complete genome sequence of the avian pathogen *Mycoplasma gallisepticum* strain R_{low}. Microbiology 2003; 149:2307-16.
- Pereira PGD. Análise histopatológica do trato respiratório de aves (*Gallus gallus*) SPF infectadas por *Mycoplasma synoviae* e vacinadas contra a doença de Newcastle [dissertação]. Niterói (RJ): Universidade Federal Fluminense; 2004.
- Polo PA, Nascimento ER, Pereira VLA, Barreto ML, Nascimento MGF, Zuanaze MAF, Scanavini-Neto H, SILVA, RCF. Perfil sorológico de galinhas SPF Imunizadas com vacinas e cepa atenuada de *Mycoplasma gallisepticum* Diferenciadas Por PCR-RAPD. Revista Brasileira de Ciência Avícola 2002; Supl. 4:118.
- Projeto identifica problema que afeta a produção de frangos no Brasil. Revista Nacional de Carne 1994; 207:21-35.
- Razin S, Tully JG. Molecular and diagnostic procedures in mycoplasma: molecular characterization. San Diego (CA): Academic Press; 1995. v.1.
- Razin S, Yogev D, Naot Y. Molecular biology and Pathogenicity of mycoplasmas. Microbiology and Molecular Biology Reviews 1998; 62:1094-156.
- Rodrigues OD, Nascimento ER, Tortelli R, Voguel J, Nascimento MGF, Lignon GB, Mendonça GA. Lesões causadas em frangos de corte pela ação experimental de *Mycoplasma gallisepticum* e *Escherichia coli*. Revista Brasileira de Medicina Veterinária 2001; 23(6):240-3.
- Rosales AG. Enfermidades Respiratórias en el Pollo de Engorde. In: Conferência APINCO 1991 de Ciência e Tecnologia Avícolas; 1991; Campinas, São Paulo. Brasil. p.163-176.
- Shapiro DP. Observations of mycoplasmosis in an integrated poultry operation. In: Poultry Mycoplasma Workshop, American College of Poultry Veterinarians, Western Poultry Disease Conference, University of California; 1994; Davis, Califórnia, USA.
- Silva RCF, Nascimento ER, Pereira VLA, Barreto ML, Nascimento MGF, Almeida JF. Influência da infecção por *Mycoplasma synoviae* na resposta vacinal de aves (*Gallus gallus*) SPF contra a doença de Newcastle. Revista Brasileira de Ciência Avícola 2003; Supl.5: 135.
- Silva RCF. Vacinação contra a doença de Newcastle em aves *Gallus gallus* SPF infectadas por *Mycoplasma synoviae* [dissertação]. Niterói (RJ): Universidade Federal Fluminense; 2003.



Stipkovits L, Burch DGS. Comparative studies on the efficacy of Mycoplasma gallisepticum bacterin and Tiamulin treatment of breeder hens. In: 9^o European Poultry Conference; 1994; Glasgow. United Kingdom. p.171-172.

Stipkovits L, Kempf I. Mycoplasmoses in poultry. *Revue Scientifique et Technique*, Office International des Epizooties 1996; 15:1495-525.

USA. United States Department of Agriculture. National Poultry and Improvement Plan and Auxiliary Provisions. Washington, DC; 1997.

Villa MFG. Programa Nacional de Sanidade avícola: 1994 a 1998. In: Conferência APINCO 1998 de Ciência e Tecnologia Avícolas; 1998; Campinas, São Paulo. Brasil. p.34-46.

Ward DM, Weller R, Batson MM. 16S rRNA sequences reveal numerous uncultured microorganisms in a natural community. *Nature* 1990; 345:63-5.

Whitford WH, Rosebush RF, Lauerma LH, editors. Mycoplasmosis in animals: Laboratory diagnosis. Ames, Iowa. Ames: Iowa State University Press; 1994.

Whithear KG. Control of avian mycoplasmoses by vaccination. *Revue Scientifique et Technique*, Office International des Epizooties 1996; 15:1527-53.

Woese CR, Stackebrandt E, Luwig W. What are mycoplasmas: the relationship of tempo and mode in bacterial evolution. *Journal of Molecular Evolution* 1985; 21:305-16.

Yamamoto R. Mollicutes. In: Biberstiein EL, Zee YC, editors. Review of veterinary microbiology. Chicago:Blackwell Scientific Publications; 1990. p.213-27.

Yamamoto R. Mycoplasma meleagridis infection. In: Calnek BW, Burnes HJ, Beard CW, Yoder Jr. HW, editors. Diseases of poultry. Ames, Iowa, USA. Ames: Iowa State University Press; 1991. p.212-23.

Yoder Jr. HW, Hofstad MS. A previously unreported serotype of avian Mycoplasma. *Avian Diseases* 1962; 6:147-60

Yoder Jr. HW. Mycoplasma gallisepticum infection. In: Calnek BW, Burnes HJ, Beard CW, Yoder Jr. HW, editors. Diseases of poultry. Ames, Iowa, USA. Ames: Iowa State University Press; 1991b.p. 198-212.

Yoder Jr. HW. Mycoplasmosis. In: Calnek BW, Burnes HJ, Beard CW, Yoder Jr. HW, editors. Diseases of poultry. Ames, Iowa, USA. Ames: Iowa State University Press; 1991a. p. 196-8.