



Epididymal Lithiasis in *Gallus gallus domesticus*

■ Author(s)

Rocha Jr. JM¹
Mahecha GAB²
Dornas RAP²
Kuana SL³
Martins NRS^{1*}

- ¹ Escola de Veterinária.
² Instituto de Ciências Biológicas.
³ Perdigão Agroindustrial S.A.

■ Mail Address

NRS Martins
Universidade Federal de Minas Gerais
Av. Antônio Carlos, 6627
Campus Pampulha
31.270-010. Belo Horizonte, MG, Brazil.

E-mail: rodrigo@vet.ufmg.br

■ Keywords

Epididymal lithiasis, *Gallus gallus domesticus*, infertility, rooster, testicular calculus.

■ Acknowledgements

The authors thank Dr. Sandra Fernandez and Dr. José Scarpelini for supplying some of the field materials. This research study was partially funded by CNPq, FAPEMIG, and Fundação de Ensino e Pesquisa em Medicina Veterinária e Zootecnia da Escola de Veterinária da UFMG.

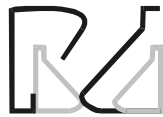ABSTRACT

A study on the occurrence of epididymal lithiasis (EL) in *Gallus gallus domesticus* of different breeds and from different geographical regions of Brazil was carried out. Forty breeding roosters were collected in the states Santa Catarina, São Paulo, Minas Gerais, Espírito Santo and Goiás, representing two specific pathogen free Leghorn lines (SPF), one commercial Leghorn layer breeder (Hy-Line) line, two commercial broiler breeder lines (Ross and Cobb), and two backyard chicken flocks. In commercial poultry breeders, EL was observed mainly after 55 weeks of age, and lithus resulted in lower fertility caused by inadequate maturation of spermatozoa and testicular atrophy, which evolved to more severe testicular dysfunction at 100 weeks of age. One hundred percent of the sampled roosters of the evaluated SPF lines presented epididymal lithiasis, which was also observed in all commercial genetic lines. The analysis of EL occurrence revealed no differences among regions and breeds: all regions and genetic lines presented epididymal calculi and the occurrence seemed higher in the more intensively-reared chickens. As for the backyard roosters, 50% presented calculi. Considering the occurrence of EL in the SPF flocks, its primary association with infectious bronchitis virus (IBV) infection was discarded, despite its contribution to fertility loss.

INTRODUCTION

The domestic chicken (*Gallus gallus domesticus*) is the most important domestic avian species for the industrial production of meat and eggs. In the Brazilian economy, these activities may reach 1.5% of the gross domestic product, and directly and indirectly generate 4.8 million jobs (Avicultura Brasileira, 2008). Under natural conditions, chickens present seasonal reproduction, and their sexual activity is dependent on the daylight stimulation of the pineal gland. In order to obtain maximum progeny output in intensive poultry reproduction, fertility must be continuous during the birds' adult life.

Epididymal lithiasis results in progressive precocious involution of the testes and reduced fertility in male breeders (Mahecha *et al.*, 2002). In 1995, a rooster fertility pathology causing spermatid count reduction in the ejaculate was described in Cornish and White Rock chicken breeds, resulting in sperm retention and premature fertility decline. By 110 weeks of age, male fertility is reduced to 5%, despite the natural potential of a 10-year-long fertility (Muncher *et al.*, 1995). Janssen *et al.* (2000) reported in adult Leghorn roosters epididymal lithiasis, with calculi composed mainly of calcium (48%), and reduced fertility, with the daily sperm production and testosterone levels that were significantly lower at 62 weeks of age as compared to normal roosters. In Brazil, Mahecha *et al.* (2002) described the occurrence of efferent ductule calculi (43.5%



calcium) in 94.3% of free-range or industrial roosters in Minas Gerais State, but not in other twenty-one different avian species of several Orders, and therefore, it was considered as disease of chickens. Boltz *et al.* (2004) studied Leghorn SPF chickens with EL, and demonstrated testicular mass reduction ($12.01 \pm 0.76\text{g}$) as compared to normal birds ($15.2 \pm 0.81\text{g}$), reduction of blood testosterone (lithiasis $3.6 \pm 0.3 \text{ ng/ml}$ vs. normal $7.0 \pm 1.63 \text{ ng/ml}$), and lower sperm number in EL as compared to normal birds ($5.03 \pm 0.31 \times 10^8$ sperm cells/testis/day vs. $7.43 \pm 0.52 \times 10^8$ sperm cells/testis/day).

Considering that male breeders fertility loss has been a frequent complaint in industrial breeder production in the last few years, and that EL was previously detected in local free-range and commercial flocks (Mahecha *et al.*, 2002), the objective of the present study was to evaluate the occurrence of EL in male breeders of commercial chicken lines as compared to backyard chickens reared in regions distant from industrial chicken production regions.

MATERIALS AND METHODS

Both testes of at least 20 roosters from each flock of commercial Hy-Line egg-type breed, Ross and Cobb meat-type (broiler) breeds, two SPF flocks, and two backyard chicken flocks of three Brazilian regions (Mid-West, Southeast, and South) were collected in 2007 (Table 1). All commercial roosters were obtained from culled flocks that were removed from reproduction, and that were older than 60 weeks of age. All backyard roosters were between two and three years of age.

Testes were analyzed in the Laboratory of Avian Diseases (Veterinary College, UFMG) and at the Reproduction Biology Laboratory (LABRE, ICB-UFMG). Calculi were counted per epididymis, and the condition was considered severe when 20 or more stones, occupying most of the tubular spaces, were counted. For histological and morphometric analyses, 5 testes from line and origin were collected. Each testis with epididymis was fixed in Bouin or 10% formaldehyde PBS (phosphate buffered saline solution) for dispatch, and weighed (0.01 g precision, Sartorius BP 2105 scale) in the laboratory. Sections were placed in 70% alcohol wash, decalcified in Perenji solution, dehydrated in absolute ethanol, cleared in xylol, and embedded in paraffin. Thin sections ($0.7\mu\text{m}$) were stained with hematoxylin-eosin. Twelve tissue cross-sections were evaluated per testis.

Data were submitted to analysis of variance using GLM procedures, and means were compared by the test of Duncan (Sampaio, 1998).

RESULTS AND DISCUSSION

Calculi were found in the epididymis of all rooster genetic lines and regions of origin, but with different intensities and prevalence (Table 1). The occurrence of EL in roosters of all regions and lines examined, including those from industrial and backyard flocks, suggests that the etiology and predisposing conditions of EL pathogenesis are present in different environments, and it is possibly associated to a particular *Gallus gallus domesticus* susceptibility, as EL has not been detected yet in other avian species (Mahecha *et al.*, 2002).

Table 1 - Prevalence of epididymal lithiasis according to region of origin and genetic line.

Region of origin	Line	Prevalence
Triângulo Mineiro - MG	Leghorn - SPF ¹	100%
Grande Belo Horizonte - MG	Leghorn ²	100%
Zona da Mata - MG	Free-range ³	60%
Castelo - ES	Free-range ³	40%
Grande São Paulo - SP	Leghorn - SPF ¹	80%
Noroeste de São Paulo - SP	Hy-Line ²	100%
Oeste de Santa Catarina - SC	Cobb ⁴	100%
Sul de Goiás - GO	Ross ⁴	100%

Notes: 1 - Leghorn SPF were confined in controlled environment chickens; 2 - Leghorn industrial egg-type breeder; 3 - Isolated unselected free-range flocks; 4 - Industrial meat-type (heavy) breeder.

The number of stones per epididymis was higher in industrial roosters as compared to backyard birds. Severe cases of calculi formation were frequent in industrial and SPF breeds, and amounted to 20 stones or more per epididymis.

Stones were irregular in shape and light (whitish) in color (Figure 1), varying from fine granules up to 3mm in length, which is consistent with an earlier detailed description of epididymal stones (Mahecha *et al.*, 2002). The microscopical examination of the efferent ductules revealed lithiasis within the ductule, which was dilated and presented epithelial folding loss, vacuolization, sloughing, and mononuclear infiltration (Figure 2).

There may be an association between intensive rearing and EL severity, as the more intensively reared and confined roosters presented had higher EL severity, with 100% prevalence in industrial breeds, including SPF, as compared to the lower incidence (40-60%) in backyard roosters. Considering that the free-range roosters examined derived from isolated flocks that

were reared distant from industrial production areas and did not employ industrial chickens inputs, such as vaccines and balanced feeds, it is possible that there may be a natural environmental cause for EL, which was present in at least two different geographical regions -one backyard flock was reared in Minas Gerais and the other, in Espírito Santo.

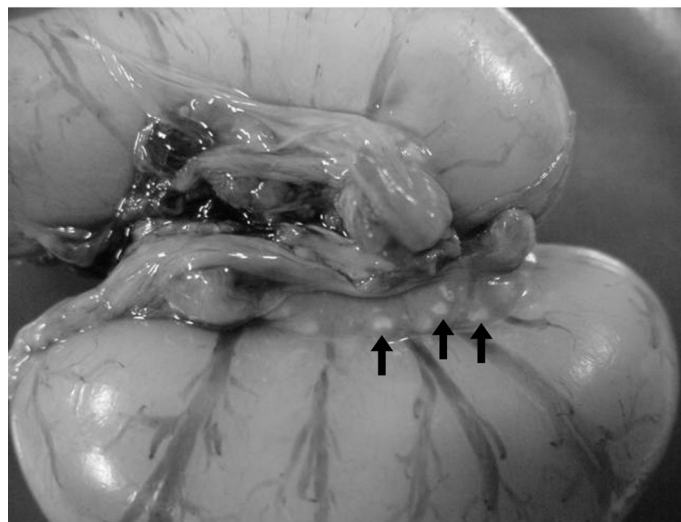


Figure 1 - Testes and epididymis of a 10⁸-week-old industrial rooster. Abundant calculi are present in various sizes and with irregular shapes in the epididymis (arrows).

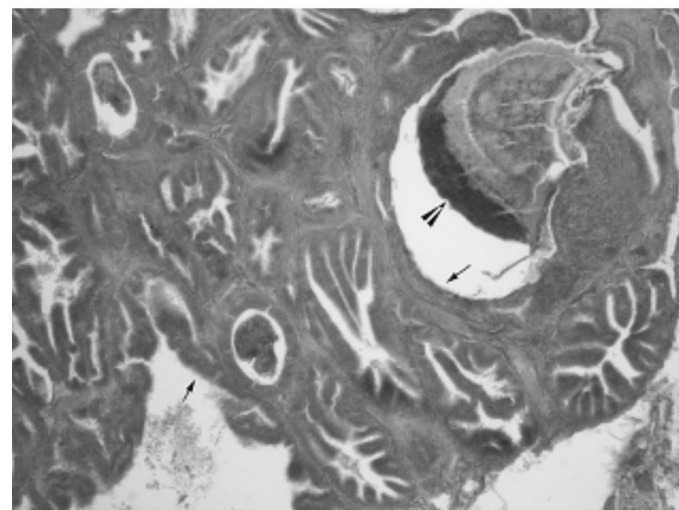


Figure 2 - Microphotograph of the efferent ductule of a 35-week-old industrial rooster. The efferent ductule is dilated, with epithelial folding loss (arrows) and with calculus (arrow head) in its interior (100x - HE).

The prevalence of EL was determined for different rooster lines and regions of origin. The two evaluated specific pathogen free (SPF) chicken lines, both certified controlled-environment origin flocks, presented high prevalence of EL, that is, both presented lithiasis in the epididymis. One SPF flock, reared in Minas Gerais state,

had 100% prevalence and the other, from São Paulo state, presented 80% prevalence. The presence of EL in SPF flocks is a relevant finding when investigating EL etiology. For instance, the previous suggestion that EL was caused by a disease primarily caused by IBV must be discarded, at least when the IBV strains employed for monitoring the SPF flocks are considered, as opposed to the findings of Boltz *et al.* (2004). However, it is recognized and emphasized that IBV may exert a significant role in the pathogenesis and aggravation of epididymal lithiasis in the field. It is also relevant to take into account that SPF flocks are regularly monitored for antibodies and antigens of several other viruses and bacteria, in addition to IBV.

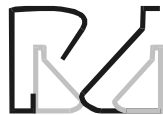Janssen *et al.* (2000) observed that epididymal lithiasis may cause chronic inflammation, with abundant mononuclear, mainly lymphocytic, infiltrates and epithelial sloughing, which may evolve to the complete destruction of the epididymal epithelium. Those authors considered as possible EL causes IBV or the elevated dietary concentration of calcium or vitamin D₃. In contrast, however, a high prevalence (80-100%) of severe EL was found in roosters from two independent commercial SPF flocks in the present study, both maintained in environmentally-controlled houses and regularly monitored for IBV.

No difference was found in EL incidence between commercial meat-type and egg-type breeds of chickens, all of which showed high EL prevalence (100%), irrespective of origin; however, backyard roosters, presented lower prevalence, of 40-60%.

The theoretical economic impact of EL is worth considering. Intensive breeding requires a ratio of one male per every ten females. Depending on male fertility, each hen is capable of laying an average of 180 eggs per cycle of about 52 weeks, and each rooster may potentially fertilize 1,800 eggs during the period of reproductive activity. Considering that in Brazil, in 2007, approximately 39 million broiler and layer breeders were in activity, a 1% loss in fertility - a relatively conservative reduction - may represent (one percent of 39 million times 1,800) a reduction of approximately 7 million chicks. In addition, a longer fertility lifespan will increase the output, reduce the need of replacement males as well as the cost of raising a new flock of breeders (Renden & Pierson, 1982).

CONCLUSION

The present study showed that EL is highly prevalent in the main chicken genetic lines and Brazilian poultry



production regions. The most surprising finding was the presence of EL in SPF flocks, considering that the etiology of EL is unknown and may be of infectious origin, although not primarily due to IBV. The pathogenesis of EL is possibly multifactorial, and may be exacerbated by interacting factors present in the poultry industrial production, such as infections by IBV and other pathogens, as well as nutritional factors. As to IBV, it has come to our knowledge that, in regions with multiple-age flocks receiving multiple live IBV vaccinations, the severity of EL was higher.

REFERENCES

Avicultura Brasileira. Audiência Pública da Comissão de Agricultura, Pecuária, Abastecimento e Desenvolvimento Rural [citado 2009 fev 10]. Disponível em: <http://www2.camara.gov.br/comissoes/capadr/audiencias-2008/rap270508tomelin.ppt>

Boltz DA. *et al.* Avian infectious bronchitis virus: a possible cause of reduced fertility in the rooster. *Avian Diseases* 2004; 48:909-915.

Janssen SJ. *et al.* Identification of the epididymal stones in diverse rooster populations. *Poultry Science* 2000; 79:568-574.

Mahecha GAB. *et al.* Epididymal lithiasis in roosters and efferent ductule and testicular damage. *Reproduction* 2002; 124: 821-834.

Muncher Y. *et al.* Intratesticular retention of sperm and premature decline in fertility in the domestic rooster, *Gallus domesticus*. *Journal of Experimental Zoology* 1995; 273: 76-81.

Renden JA, Pierson ML. Long term reproductive performance of broiler breeder males selected for semen production. *Poultry Science* 1982; 61(6):1214-1217.

Sampaio IBM. Estatística aplicada à experimentação animal. Belo Horizonte: Fundação de Ensino e Pesquisa em Medicina Veterinária e Zootecnia; 1998. 221 p.