



Enterobacteria Isolation in Ostrich Eggs (*Struthio camelus*)

■ Author(s)

Knöbl T¹
Cappellete CP²
Vigilato MAN²

- 1 Faculdade de Medicina Veterinária e Zootecnia, Universidade de São Paulo.
- 2 Faculdade de Medicina Veterinária – Complexo Educacional FMU.

■ Mail Address

Terezinha Knöbl
Departamento de Patologia
Faculdade de Medicina Veterinária e Zootecnia da Universidade de São Paulo
Av. Prof. Dr. Orlando Marques de Paiva 87,
Cidade Universitária
05.508-000. São Paulo, SP, Brazil.

E-mail: tknobl@usp.br

■ Keywords

Enterobacteria, *Hafnia alvei*, ostriches, reproduction, *Struthio camelus*.

■ Acknowledgements

The authors thank FAPESP for funding this study under grant 05/57500-9.

ABSTRACT

This study was conducted to determine the presence of enterobacteria in the eggs of ostriches reared on a farm with a history of reproductive failure. Ninety samples from twenty eggs were submitted to bacteriological tests. The results showed Enterobacteria growth in 100% of the eggs. The microorganisms isolated were *Hafnia alvei* in 50% (10/20), *Serratia* spp. in 20% (4/20), *Escherichia coli* in 15% (3/20), and *Citrobacter freundii* in 15% (3/20). All eggs presented poor eggshell quality, which favored enterobacteria contamination. *Hafnia alvei* was present only in the internal egg structures (albumen and yolk sac), suggesting the possibility of vertical infection.

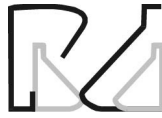INTRODUCTION

Reproductive failure in ostriches often results from poor eggshell quality, allowing egg contamination by bacteria present in the gut flora. Eggshell thickness, high pore density, deficient cuticle deposition and low eggshell strength are associated with low hatchability and high embryonic mortality during artificial incubation (Perelman, 2009). Eggshell quality may be affected by several factors, such as nutritional calcium and vitamin imbalances, presence of mycotoxins in feeds, and bacterial and viral infections (Almeida, 2007).

In chickens, changes in lay and eggshell quality are related to viral infections, mainly by coronavirus (Infectious Bronchitis virus) (Cubillus, 2009). Cadman *et al.* (1994) suggested that ostriches may be infected with the Chicken Infectious Bronchitis virus, but were not able to isolate it. Villareal *et al.* (2007) reported the detection of avian coronavirus by RT-PCR and suggested the virus transmission transmission to ostriches breeders, due to reproductive tract infection.

High eggshell porosity favors the contamination of the eggs by microorganisms present in the feces and by the gut flora. De Reu *et al.* (2006) made an experimental trans-shell egg contamination study with seven selected bacterial strains: *Staphylococcus warneri*, *Acinetobacter baumannii*, *Alcaligenes* sp., *Serratia marcescens*, *Carnobacterium* sp., *Pseudomonas* sp. and *Salmonella* Enteritidis. The results showed that all these strains were able to penetrate the eggshell after four to five days and the authors concluded that the Gram-negative, motile and non-clustering bacteria penetrated the eggshell most frequently. The contamination of eggs by *Escherichia coli*, *Pseudomonas aeruginosa*, *Klebsiella* spp. and *Salmonella* spp. can result in embryonic death (Perelman, 2009).

The objective of this study was to detect the presence of enterobacteria in ostrich eggs from a commercial breeding farm located in the São Paulo state, and to discuss the possible infectious causes of reproductive failure in female ostriches (*S. camelus*).



MATERIAL AND METHODS

Twenty embryonated eggs from ostriches with reproductive disorders were transported to the laboratory for bacteriological examination. Thirteen eggs were in the first half of the incubation period (1-21 days) and seven eggs were in the second half of the incubation period (22-42 days). All eggs presented stress lines (Figure 1), and the quality of the eggshells was poor, with deformities and high porosity, resulting in embryonic death (Figure 2). The eggs were produced by ostriches housed in farms with no history of health, nutritional or management failures that might justify those symptoms.



Figure 1 - Stress lines in the eggshell of an ostrich egg.

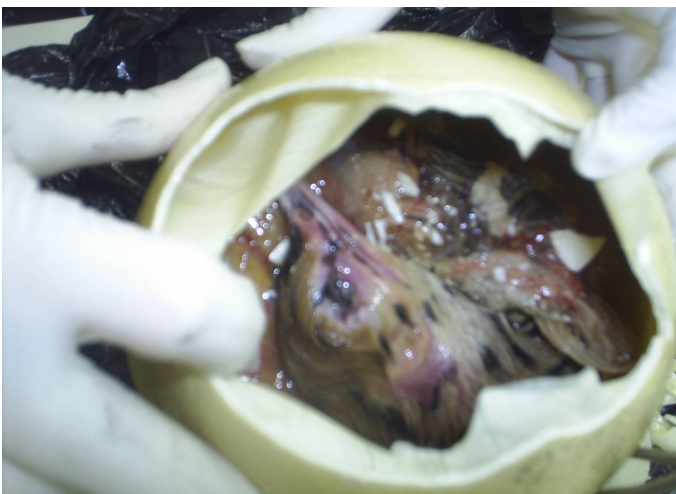


Figure 2 - Dead ostrich embryo.

Eggs were transported under refrigeration and their gross examination was performed under aseptic

conditions. Each part (eggshell, shell membrane, albumen, yolk and intestinal contents of developing embryos) was separated. Samples were transferred to BHI broth, incubated at 37 °C for 18 hours. Bacterial isolation was performed by cultivation on MacConkey agar and blood agar at 37 °C for 24 hours.

Samples used for *Salmonella* spp identification were cultivated in 1% peptone water at 37 °C by 24 hours, transferred to sodium tetrathionate broth, incubated at 37 °C for 24 h (selective enrichment), and then cultured XLT4 agar (Difco, Detroit, ML, USA), for 24 h at 37 °C.

The identification of the infecting agent was performed by biochemical tests, according to the information of Bergey's Manual of Bacteriological Identification (Holt *et al.*, 1994).

RESULTS

Culture results showed *Hafnia alvei* growth in 50% (10/20) of the eggs, *Serratia* spp in 20% (4/20), *Escherichia coli* in 15% (3/20) and *Citrobacter freundii* in 15% (3/20) (Table 1). *Hafnia alvei* and *Serratia* spp. were isolated in eggs with early embryonic mortality, while infections by *E. coli* and *Citrobacter freundii* affected embryos in later stages of development until immediately after hatching. Half of the eggs (50%) presented yolk sac and albumen contamination, but no bacterial growth was detected in the eggshell or eggshell membrane, whereas in the other half (50%), the contamination affected both the internal and external egg structures (Table 1).

DISCUSSION AND CONCLUSION

Cabassi *et al.* (2004) reported a high prevalence of *Escherichia coli* and *Enterobacter* spp. in eggs from ostriches with reproductive disorders. The authors analyzed 534 eggs, but the presence of *Hafnia alvei* was not detected. In chickens, *Hafnia alvei* infection was described in layers, which presented decrease in egg production and death (Real *et al.*, 1997; Proietti *et al.*, 2004). The presence of *Hafnia alvei* in the yolk sac of chickens was described by Cox *et al.* (2006). This is possibly the first report of *Hafnia alvei* infection in ostriches. It is likely that the infection was vertically transmitted, because the agent was isolated from the internal egg structures and was absent in the shell and the shell membrane (Table 1).

None of the eggs analyzed were contaminated with *Salmonella* spp. Species of the genus *Salmonella* are

**Table 1** - Bacteriological results obtained from ostrich eggs.

Microorganisms	Contaminated eggs (n)	Internal and external contamination (n*)	Only internal contamination (n**)
<i>Hafnia alvei</i>	10	1	-
<i>Escherichia coli</i>	4	4	-
<i>Citrobacter freundii</i>	3	3	-
<i>Serratia liquefaciens</i>	3	3	-
Total	20	10 (50%)	10 (50%)

* Contamination of the eggshell, eggshell membrane, albumen and yolk sac; ** Contamination of the albumen and yolk sac.

the most prevalent and hazardous agents associated with egg products. Food-poisoning by *Salmonella* has been reported in many countries. In Brazil, a *Salmonella* control program was implemented in 1994 by the Brazilian Ministry of Agriculture (MAPA). Since 1998, ostriches are monitored for *S. pullorum* test, and those infected are sacrificed to prevent vertical transmission (BRASIL, 2010).

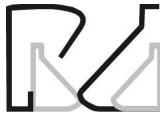Citrobacter spp and *Serratia* spp. contamination is also a public health concern, since these agents are associated with resistance to antimicrobials and disinfectants. There are several reports of localized and systemic diseases caused by these bacteria in humans with immunodeficiency syndromes or due the nosocomial infections (Zúñiga *et al.*, 1991; Drinka *et al.* 2003; Hess *et al.*, 2004). In ratites, citrobacteriosis is a rare and highly fatal disease, primarily caused by *Citrobacter freundii* infection that affects ostrich chicks (Rupley, 1999).

Pelerman (2009) reported egg contamination by pathogenic *E. coli* (APEC) during incubation. Colibacillosis clinical signs emerge between 24 hours after hatch until 15 days of age, and include omphalitis, neurological disorders, septicemia and death. In the present study, the three ostrich embryos from *E. coli*-contaminated eggs presented omphalitis (Figure 2).

The results of the present study suggest that *Escherichia coli*, *Citrobacter freundii* and *Serratia liquefaciens* infected the eggs by fecal contamination due to eggshell deformity. However, *Hafnia alvei* was the most frequent agent detected and may be associated with salpingitis in ostriches. Doneley (2006) reported that the presence of stress lines in the eggshells is associated with copper deficiency or salpingitis. There are few reports on reproductive diseases of ostrich hens. Further studies are needed to confirm the vertical transmission of enterobacteria, such as *Hafnia alvei*, and the possible impacts of the contamination by these agents on ratite reproduction.

REFERENCES

- Almeida MA. Struthioniformes (Ema, avestruz). In: Cubas ZC, Silva GCR, Catão-Dias JL, editors. Tratado de Animais Selvagens. São Paulo: Rocca; 2007. p.136.
- BRASIL. Ministry of Agriculture. Livestock and Food Supply – MAPA [cited 2010 jul 14]. Available from: www.agricultura.gov.br/portal.
- Cabassi CS, Taddei S, Predari G, Galvani G, Ghidini F, Schiano E, Cavirani S. Bacteriological findings in ostrich (*Struthio camelus*) eggs from farms with reproductive failures. Avian Diseases 2004; 48(3):716-722.
- Cadman HF, Kelly PJ, Zohu R, Davellaar F, Mason PR. A serosurvey using enzyme linked immunosorbent assay for antibodies against poultry pathogens in ostriches (*Struthio camelus*) from Zimbabwe. Avian Diseases 1994; 38(3):621-625.
- Cox NA, Richardson LJ, Buhr RJ, Northcutt JK, Fedorka-Cray PJ, Bailey JS, Fairchild BD, Mauldin JM. Natural occurrence of *Campylobacter* species, *Salmonella* serovars and other bacteria in unabsorbed yolks of marked age commercial broilers. The Journal of Applied Poultry Research 2006; 15(4):551-557.
- Cubillos A. Bronquite Infecciosa Aviária. In: Revolledo L, Ferreira AJP, editores. Patologia Aviária. São Paulo: Manole; 2009. p.158.
- De Reu K, Grijspeerdt K, Messens W, Heyndrickx M, Uyttendaele M, Debevere J, Herman L. Eggshell factors influencing eggshell penetration and whole egg contamination by different bacteria, including *Salmonella enteritidis*. International Journal of Food Microbiology 2006; 112(3):253-260.
- Doneley B. Management of captive ratites. In: Harrison GJ, Lighfoot TL, editors. Clinical Avian Medicine. Florida: Spix Publishing; 2006. p.982-983.
- Drinka PJ, Gauerke C, Miller J, Stemper ME, Kurt BS, Reede D. Apparent transmission of *Citrobacter koseri* in catheterized residents on a 17-bed nursing home wing. Journal of the American Geriatrics Society 2003; 51(1):140-141.
- Hess P, Altenhöfer A, Khan AS, Daryab N, Kim KS, Hacker J, Oelschlaeger TA. A *Salmonella* fim homologue in *Citrobacter freundii* mediates invasion *in vitro* and crossing of the blood-brain barrier in the rat pup model. Infection and Immunity 2004; 72(9):5298-5307.
- Holt JG, Krieg NR, Sneath PHA, Staley JT, Williams ST. Determinatively anaerobic gram-negative rods. 9 ed. In: Holt JG, Krieg NR, Sneath PHA, Staley JT, Williams ST, editors. Bergey's manual of determinative bacteriology. 9th ed. Baltimore: Williams & Williams; 1994. p.75-289.
- Perelman B. Doença das avestruzes. In: Revolledo L, Ferreira AJP, editores. Patologia Aviária. São Paulo: Manole; 2009. p.492.



Proietti PC, Passamonti F, Franciosini MP, Asdrubali G. *Hafnia alvei* infection in pullets in Italia. Avian Pathology 2004; 33(2):200-204.

Real F, Fernández A, Acosta F, Acosta B, Castro P, Déniz S, Orós J. Septicemia associated with *Hafnia alvei* in laying hens. Avian Diseases 1997; 41(3):741-747.

Rupley AE. Manual de clínica aviária. São Paulo: Editora Roca; 1999.

Villareal LYB, Knobl T, Sandri TL, Cappellete CP, Richtzenhain L, Brandão PE. Natural vertical transmission of infectious bronchitis virus in ostrich. Proceedings of Conferência Apinco de Ciência e Tecnologia avícolas; 2008; Santos, São Paulo. Brasil. Campinas:FACTA; 2008. p. 238.

Zúñiga, JM, González PA, Henríquez AM, Fernández AV. Bacteremic pneumonia by *Citrobacter diversus*: report of a case. Revista Médica do Chile 1991; 119(3):303-307.