



■ Author(s)

Maiorka Aⁱ
Silva AVFⁱ
Santin Eⁱ
Bruno LDGⁱⁱ
Boleli ICⁱⁱⁱ
Macari Mⁱⁱⁱ

ⁱ Universidade Federal do Paraná 80035-050
Curitiba PR Brasil Tel: 55 41 33505732 Fax:
55 41 32524149

ⁱⁱ Universidade Estadual do Oeste do Paraná
– CCA CEP 85960-000 – Marechal Cândido
Rondon - PR – Brasil Tel: +55 45 3284 7935
Fax: +55 45 3284 7879

ⁱⁱⁱ Faculdade de Ciências Agrárias e
Veterinárias – Unesp 14884-900 Jaboticabal
SP Brasil Tel: 55 16 32092654 Fax: 55 16
3202 4275

■ Mail Address

Corresponding author e-mail address

Alex Maiorka

Universidade Federal do Paraná/Setor de
Ciências Agrárias - Departamento de
Zootecnia

Rua dos Funcionários, 1540

80035-050, Curitiba-PR, Brazil.

Phone: +(41) 3350-5732

Email: amaiorka@ufpr.br

■ Keywords

Broiler breeder age, embryo, microvillus,
small intestine, villus.

Effect of Broiler Breeder Age on the Intestinal Mucosa Development of the Embryos at 20 Days of Incubation

ABSTRACT

This study investigated the effect of broiler breeder age on the morphological development of the small intestine broiler embryos (villus height, crypt depth, microvillus height, and villus density) at 20 day of incubation. Eggs obtained from 30- and 60-wk-old broiler breeders were used. The results showed that embryos from older broiler breeders presented longer villi in the duodenum, jejunum, and ileum compared with younger broiler breeders. In addition, embryos from older broiler breeders presented deeper crypts in the jejunum and ileum, longer microvilli in jejunal enterocytes, and lower villus density (microvillus number/ μm^2) in the duodenum and ileum than younger breeders. These results suggest that breeder age influences the gut mucosa development of broiler embryos. Embryos from older broiler breeder showed greater development of the small intestine mucosa than those from younger broiler breeder.

INTRODUCTION

Although the digestive tract of poultry is anatomically complete at hatch (Overton & Shoup, 1964), its physiological capacity for digestion and absorption is lower compared with mature birds. The requirements for more nutrients for body development post hatch causes morphological and physiological changes in the digestive tract, particularly in the intestines (Ferrer *et al.*, 1995). The intestinal mucosa is essential for the digestion and absorption of many nutrients through enterocyte membrane receptors and cytosol proteins, which indicates that the digestion and absorption are related to luminal surface of the intestine.

Many factors influence the development of the intestinal mucosa of broiler embryos during incubation, especially breeder age. Day-old turkey poults from older breeders presented longer villi and higher capacity to metabolize glucose than those from younger breeders. (Applegate *et al.*, 1999, Applegate & Lilburn, 1999). This indicates that the intestinal mucosa of turkey poults from older breeders are physiologically and morphologically more developed than that of younger breeders, and therefore are better prepared to utilize feed nutrients. Shanawany (1984) observed that this more advanced development of the intestinal mucosa was related to egg weight at setting and embryo weight, as older broiler breeders lay larger eggs and consequently produce larger chicks than young breeders.

Broiler breeder age also influences the duration of incubation. Mather & Laughlin (1979) showed that eggs from older broiler breeders hatch first than those from younger broiler breeders, and argued this may be related to embryo development.

In this context, the objective of this study was to evaluate the effect of broiler breeder age on structural and ultra-structural intestinal mucosa morphology in embryos at 20 days of incubation.



MATERIALS AND METHODS

Fertilized eggs from 30-wk-old and 60-wk-old Cobb-500 broiler breeders, obtained from a commercial hatchery, were incubated at 37.8° C and 60% relative humidity. On day 20 of incubation, eight embryos from each broiler breeder age were sacrificed by cervical dislocation, and their small intestines collected for morphological analyses. Samples of approximately 2 cm in length were collected from each segment of the small intestine (duodenum: from the pylorus to the distal duodenal loop; jejunum: from the distal duodenal loop to Meckel's diverticulum, and ileum: between Meckel's diverticulum and the opening of the ceca).

Light Microscopy

The collected intestinal samples were submitted to the Laboratory of Animal Morphology and Physiology of São Paulo State University, Jaboticabal campus, Brazil. Samples were fixed in Bouin's solution, dehydrated in standard graded alcohol-toluene series (50, 60, 70, 80, 90, and 100% for 15 minutes each), and embedded in paraffin. Five-micrometer sections were prepared and stained with hematoxylin-eosin (HE). Slides were observed under a light microscope. Villus height (µm) and crypt depth (µm) from each segment were measured in 60 microscopic fields using an image analysis system (Video Plan, Carl Zeiss, Germany).

Scanning electron microscopy

Scanning electron microscopy of the intestinal segments was carried out at the Laboratory of Electronic Microscopy of São Paulo State University, Jaboticabal campus, Brazil.

The contents of the collected intestinal segments were washed using saline solution buffered with 0.1 M phosphate (pH 7.4), and tissue samples were fixed in 2% glutaraldehyde in phosphate buffer for 24 h at 4° C. Subsequently, samples were washed with phosphate buffer and post-fixed for two hours in 1% osmium tetroxide. Samples were then washed again

with the same buffer solution and dehydrated in graded ethanol series (50, 60, 70, 80, 90, and 100% for 15 minutes each).

Samples were dried in a critical-point drier with liquid carbon dioxide. The material was then placed on an appropriate specimen tray, covered with a 30-nm layer of gold and observed under a scanning electron microscope (model JSM 25SII, Jeol, USA). Villus density (number of villus/segment) was obtained by counting the number of villus in six areas measuring 103,269 µm² each.

Transmission electron microscopy

Transmission electron microscopy of the intestinal segments was carried out at the Laboratory of Electronic Microscopy of São Paulo State University, Jaboticabal campus, Brazil.

Samples of the intestinal segments, measuring approximately 1 mm², were infiltrated with 1:1 ethanol-Epon 812 resin at room temperature for two hours, and embedded in Epon 812 resin at 60° C for 72 hours. The samples were then sectioned, stained with lead citrate and uranyl acetate, and electron-microphotographed using transmission electron microscopy.

Longitudinal sections of the enterocytes were evaluated by image analysis in order to measure: enterocyte tip diameter (µm), microvillus height and width (µm); and microvillus density (microvillus number/µm²). The average of each measurement corresponded to the measurements of 10 samples per bird.

The surface area of the tip of the enterocytes was calculated based on the tip diameter (C_d) and the microvillus amplification factor (MAF), according to Ferrer *et al.* (1995), according to the equation:

$S = \pi \times C_d^2 / 4 \times \text{MAF}$, where $\text{MAF} = \pi \times H \times d \times D + 1$ (L = microvillus height; d = microvillus width, and D = microvillus number/µm²) (Ferraris *et al.*, 1989).

Statistical Analysis

A completely randomized experimental design with two treatments (breeder age) and eight replicates each

Table 1 – Villus height (µm), crypt depth (µm) and microvillus height (µm) of the small intestine (duodenum, jejunum and ileum) of embryos at 20 days of incubation.

Segment	Broiler breeder age (weeks)	Villus height	Crypt depth	Microvillus height
Duodenum	60	101 ± 11.11 ^a	53 ± 16.06	0.859 ± 0.09
	30	77 ± 6.06 ^b	44 ± 4.88	0.860 ± 0.15
Jejunum	60	45 ± 5.07 ^a	37 ± 2.17 ^a	1.090 ± 0.17 ^a
	30	39 ± 4.43 ^b	31 ± 2.90 ^b	0.874 ± 0.09 ^b
Ileum	60	41 ± 5.79 ^a	31 ± 3.82 ^a	1.241 ± 0.20
	30	31 ± 3.31 ^b	26 ± 3.04 ^b	0.983 ± 0.24

a-b: Means within a column for each variable with no common superscript differ significantly (p<0.05). Each value represents the mean ± SEM. Number of birds/group= 8



was applied. Data were submitted analysis of variance and means were compared by the t-test using software SAS University Edition.

RESULTS

Table 1 and Figures 1 and 2 show the results of villus and microvillus height and crypt depth of the embryos.

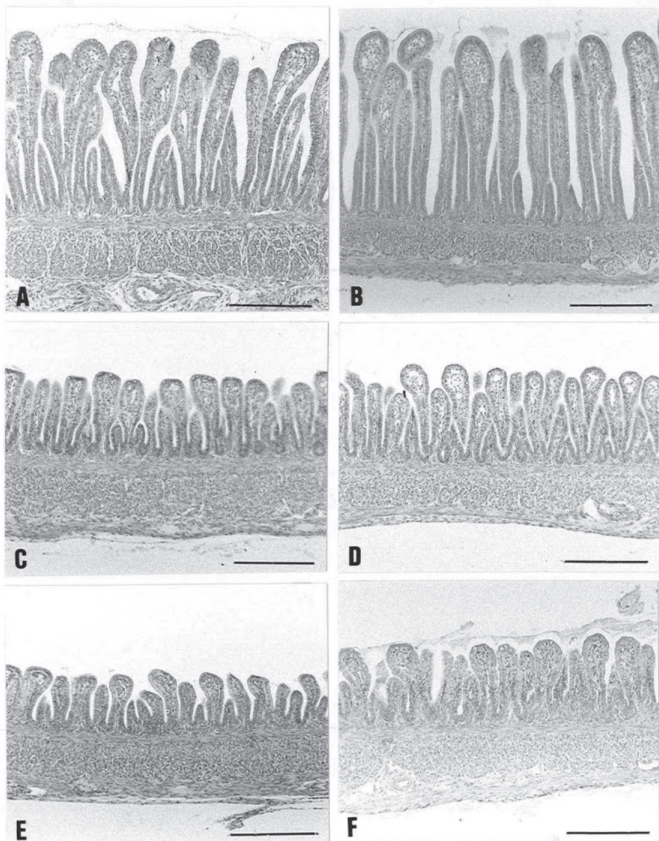


Figure 1 – Microphotograph of intestinal mucosa villi of embryos at 20 days of incubation, from broiler breeders of different ages. Duodenum of embryo from 30-wk-old broiler breeder (A), duodenum of embryo from 60-wk-old broiler breeder (B), jejunum of embryo from 30-wk-old broiler breeder (C), jejunum of embryo 60-wk-old broiler breeder (D), ileum of embryo from 30-wk-old broiler breeder (E), ileum of embryo from 60-wk-old broiler breeder (F).

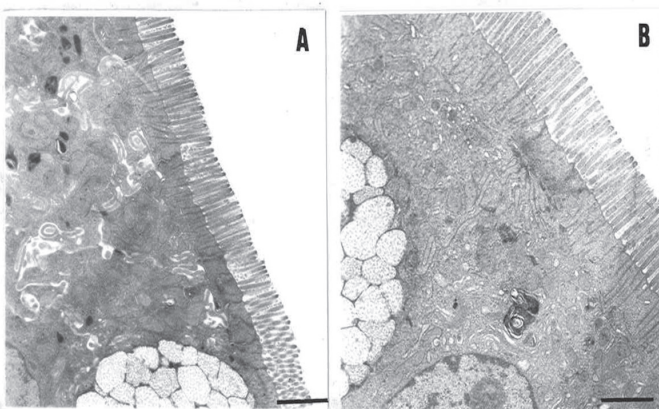


Figure 2 – Transmission electron-microphotograph of the jejunum of an embryo from 30-wk-old broiler breeder (A), and of an embryo from 60-wk-old broiler breeder (B) (5,000 X) on day 20 of incubation.

Embryos from older (60-wk-old) broiler breeders presented significantly longer villi in the duodenum, jejunum, and ileum than those from younger (30-wk-old) broiler breeders, as well as deeper crypts in the jejunum and ileum. Embryos from older broiler breeders presented longer microvilli than those from younger broiler breeder only in the jejunum. On the other hand, embryos from younger broiler breeders presented higher villus density (villus number/103.269 μm^2) in the duodenum, jejunum, and ileum than those from younger broiler breeders, (Table 2 and Figure 3).

Table 2 – Villus density (number of the villus/103.269 μm^2) in the duodenum, jejunum, and ileum of embryos from 60- and 30-wk-old broiler breeders at 20 days of incubation.

Segment	Broiler breeder age (weeks)	
	60	30
Duodenum	281 \pm 21 ^b	378 \pm 16 ^a
Jejunum	381 \pm 99 ^b	443 \pm 97 ^a
Ileum	483 \pm 83 ^b	614 \pm 82 ^a

a-b: Means within a row for each variable with no common superscript differ significantly ($p < 0.05$). Each value represents the mean \pm SEM. Number of birds/group = 8




Figure 3 – Scanning electron-microphotograph of embryos, at 20 days of incubation, from broiler breeders of different ages. Duodenum of embryo from 30-wk-old broiler breeder (A), duodenum of embryo from 60-wk-old broiler breeder (B), jejunum of embryo from 30-wk-old broiler breeder (C), jejunum of embryo from 60-wk-old broiler breeder (D) (X 100); ileum of embryo from 30-wk-old broiler breeder (E), ileum of embryo from 60-wk-old broiler breeder (F) (X 100).



No differences in enterocyte tip surface area were observed in the duodenum, jejunum, or ileum (Table 3) between embryos from different broiler breeder age.

Table 3 – Surface area (μm^2) of the tip of enterocytes in the duodenum, jejunum, and ileum of embryos from 60- and 30-wk-old broiler breeders at 20 days of incubation.

Segment	Broiler breeder age (weeks)	
	60	30
Duodenum (μm^2)	132 \pm 17	131 \pm 29
Jejunum (μm^2)	107 \pm 13	102 \pm 11
Ileum (μm^2)	119 \pm 18	108 \pm 21

Each value represents the mean \pm SEM.

Number of birds/group= 8.

DISCUSSION

Broiler breeder age influences chick size, hatching time (Mather & Laughlin, 1979) and intestinal mucosa development (Applegate *et al.*, 1999; Applegate & Lilburn, 1999). Intestinal mucosa development is directly and indirectly influenced by lipid transfer to the egg, and older breeders deposit more lipids in the egg yolk because they produce less eggs. According to Applegate & Lilburn (1999), day-old turkey poults from older (48-wk-old) turkey breeders present longer intestinal villi than those from younger (34-wk-old) breeders.

Uni *et al.* (1998), studying the physiology of the intestinal mucosa of broilers, observed that enterocytes proliferate in the crypt, from which they migrate and mature until reaching the tip of villus, increasing villus length (Moran Jr., 1985). In the present study, embryos from older broiler breeder presented deeper crypts than those from younger broiler breeders, suggesting higher enterocyte turnover rate, and consequently better yolk absorption.

Considering the morphometric observations from this study, embryos from older broiler breeders also showed longer villi and microvilli, indicating larger digestion and absorption area, and therefore, better post-hatch performance compared with embryos from younger breeders. However, in the study of Applegate *et al.* (1999), the intestinal mucosa differences between day-old turkey poults from older and younger breeder ages were no longer observed at one week of age. Glucose and cholesterol blood levels of younger breeders' turkey poults were higher than those from older breeders, suggesting lower fat metabolism and lipoprotein transfer and higher clearance time of these nutrients. This indicates incomplete adaptation to the physiological changes that occur after feeding and longer time needed to utilize nutrients (Applegate & Lilburn, 1999).

The results of the present study show influence of broiler breeder age on the intestinal mucosa development. However, further studies are required to understand the effects of the greater development of the intestinal mucosa of chicks from older broiler breeders on feed digestion and absorption, as well as on live performance. The results may allow nutritionists to adopt different nutritional programs for starter broilers from younger and older breeders, or even to apply *in-ovo* nutrition techniques of embryos from younger breeders.

CONCLUSION

Broiler breeder age influences the development of small intestine mucosa of the offspring. Embryos from 60-wk-old broilers breeders showed a more advanced development of the intestinal mucosa (villus and microvillus height, in particular) compared with those from 30-wk-old broiler breeders.

ACKNOWLEDGEMENTS

The authors thank Fundação de Amparo à Pesquisa do Estado de São Paulo (FAPESP) for financial support (Proc. 98/11304-9) and Electronic Microscopy Laboratory of UNESP/Jaboticabal for the analyses.

REFERENCES

- Applegate TJ, Dibner JJ, Kitchell ML, Uni Z, Lilburn MS. Effect of turkey (*Meleagris gallopavo*) breeder hen age and egg size on poult development. 2. Intestinal villus growth, enterocyte migration and proliferation of the turkey poult. *Comparative Biochemistry and Physiology Part B* 1999;124:381-389.
- Applegate TJ, Lilburn MS. Effect of turkey (*Meleagris gallopavo*) breeder hen age and egg size on poult development. 1. Intestinal growth and glucose tolerance of the turkey poult. *Comparative Biochemistry and Physiology Part B* 1999;124:371-380.
- Ferraris RP, Lee PP, Diamond JM. Origin of regional and species differences in intestinal glucose uptake. *American Journal of Physiology* 1989;257:G689-697.
- Ferrer R, Planas JM, Moretó M. Cell apical surface area in enterocytes from chicken small and large intestine during development. *Poultry Science* 1995;74:1995-2002.
- Mather CM, Laughlin KF. Storage of hatching eggs: the interaction between parental age and early embryonic development. *British Poultry Science* 1979;20:595-604.
- Moran Jr ET. Digestion and absorption of carbohydratases in fowl and events though perinatal development. *Journal of Nutrition* 1985;115:665-674.
- Overton J, Shoup J. Fine structure of cell surface specializations in the maturing duodenal mucosa of the chick. *Journal Cell Biology* 1964;21:75-82.
- SAS Institute. SAS university edition: installation guide for windows. Cary; 2014.
- Shanawany MM. Inter-relationship between egg weight, parental age and embryonic development. *British Poultry Science* 1984;25:449-455.
- Uni Z, Platin R, Sklan D. Cell proliferation in chicken intestinal epithelium occurs both in the crypt and along the villus. *Comparative Biochemistry and Physiology Part B* 1998;168:241-247.