

Unsuccessful treatment of sideroblastic anaemia with chloroquine

Insucesso da cloroquina no tratamento da anemia sideroblástica

Carmen S. P. Lima¹
 Osias F. Souza²
 Sara T. O. Saad³
 Valder R. Arruda³

¹Haematology and Haemotherapy Centre.

²Department of Ophthalmology.

³Department of Internal Medicine.

Faculty of Medical Sciences, State University of Campinas, Campinas-SP – Brazil.

To the Editor

Sideroblastic anaemias (SA) are a heterogeneous group of acquired and inherited bone marrow disorders defined by the presence of pathologic iron deposits in the erythroblast mitochondria.¹ The clinical manifestations of SA are for the most part dependent upon the severity of anaemia.¹

The mainstay of treatment for SA patients is red blood cell (RBC) transfusion. Low-dose chloroquine was used with success in porphyria cutanea tarda² which suggests that the drug interfered with haeme metabolism. Anecdotal reports^{3,4} pointed to a beneficial effect of chloroquine in sporadic SA patients.

In this study, six patients (2 men, 4 women, mean age: 47 years, range: 27 to 74), who presented a confirmed diagnosis of SA,^{5,6} and had a performance status less than or equal to 2 (WHO criteria)⁷ were treated with 300mg daily of chloroquine for six months. Written informed consent was obtained from all patients. Two of them presented the inherited form of the disease and the remaining patients presented acquired SA. All patients were anaemic and four patients were RBC transfusion-dependent. Patients with active co-morbid medical conditions or pregnancy were excluded from the study. Ring sideroblast (RS) count in bone marrow and ophthalmologic evaluation were performed before the study began, and repeated six months later. Blood count, liver and renal functional tests were assessed once a month. In transfusion-dependent patients, the mean RBC transfusion requirement was calculated from the 6-month interval before the beginning of the study and after a 6-month interval of treatment. Epigastric

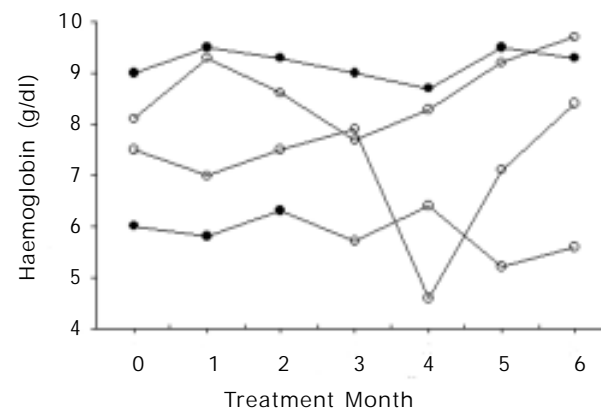


Fig. 1 – The haemoglobin levels (l;O) in four sideroblastic anaemia patients during the administration of chloroquine. The open symbols (O) represent the haemoglobin levels in red blood cell dependent-patients

pain was the only observed side effect, and was referred to by five out of six patients. It was severe enough to determine chloroquine interruption in two of them.

Two out of the four patients that were in fact studied had never received RBC transfusion. Two units of RBC were administered to one of them after two months of the beginning of the study. The transfusion requirement (two units and four units per month) remained the same as before chloroquine treatment in the remaining two patients. Neither significant increase in haemoglobin levels (Hb) nor significant reduction in RS count were observed in these patients with the treatment (Figure 1).

Unfortunately, our results are quite different from previous promising data.^{3,4} This difference apparently could not be attributed to the dose of chloroquine used, duration of the treatment or if the disease was inherited or acquired. Drénou et al (1995)³ treated one congenital SA patient with the same dose of chloroquine as we used and the Hb rose to normal values and RS disappeared from the bone marrow two months later. In addition, Garcia-Perez et al (1996)⁴ also administered chloroquine at a dose of 300mg per day to one patient with acquired SA and the Hb increased and there was no necessity for transfusion after one month of treatment.

The difference between our results and those previously reported may be explained by the multiple mechanisms involved in the different types of this yet poorly understood syndrome.^{8,9}

Severe epigastric pain was the only observed side effect in our patients. Although no side effects were reported in the previous analysed cases,^{3,4} severe gastrointestinal symptoms were described in about 25%

of patients with rheumatological diseases during chloroquine administration.¹⁰

The absence of response and the side effects observed in this study suggest that chloroquine treatment is not a good choice for SA patients. However, the small number of patients enrolled in the study indicates that larger studies must be performed for obtaining consistent conclusions on this matter.

Resumo

As anemias sideroblásticas representam um grupo de moléstias heterogêneas. O seu tratamento é restrito e baseado em transfusões de sangue. Relatos descrevem um potencial benéfico no uso da cloroquina na anemia sideroblástica (AS). Neste estudo, seis pacientes com AS foram tratados pelo período de seis meses com 300g/dia de cloroquina. Epigastralgia foi um sintoma freqüente nos pacientes do estudo obrigando à interrupção do tratamento em dois deles. A necessidade transfusional permaneceu a mesma em dois pacientes e não ocorreu em nenhum paciente o aumento dos níveis de hemoglobina ou a redução do percentual de sideroblastos em anel. A ausência de resultados e os efeitos colaterais sugerem que o uso de cloroquina seja inadequado para o tratamento de AS.

References

1. Bottomley S. Sideroblastic anaemia. In: Jacobs, A. Clinics in Haematology. W B Saunders Company, London. 1982.
2. Kordak V, Semradova M. Treatment of porphyria cutanea tarda with chloroquine. Br J Dermatol 1974;90:95-100.
3. Drénou B, Guyader D, Turlin B, Fauchet R. Treatment of sideroblastic anemia with chloroquine. N Engl J Med 1995;332:614.
4. Garcia Perez A, Viejo A, Pérez Solaz A, Ena J. Es util la chloroquine en el tratamiento de la anemia refractaria sideroblastica ? Sangre 1996;41:162.
5. Bennett JM, Catovsky D, Daniel MT, Flandrin G, Galton DAG, Gralnick HR, Sultan C. Proposals for the classification of myelodysplastic syndromes. Br J Haematol 1998;51:189-99.
6. Bennett JM. Classification of the myelodysplastic syndromes. Clin Haematol 1986;15(4):909-23.
7. World Health Organization (Switzerland): WHO Handbook For Reporting Results of Cancer Treatment. World Health Organization. Geneva. 1979.
8. Alcindor T, Bridges KR. Sideroblastic anaemias. Br J Haematol 2002;116:733-43.
9. Fleming MD. The genetics of inherited sideroblastic anemias. Semin Hematol 2002;39:270-81.
10. Maksymowych W, Russel AS: Antimalarials in rheumatology: efficacy and safety. Semin Arthritis Rheum 1987;16:206-21.

Recebido: 20/01/03

Aceito: 18/02/03

Correspondence to: Carmen S. P. Lima; MD, PhD
Hemocentro - Unicamp
Cidade Universitária Zeferino Vaz – Distrito de Barão
Geraldo
Caixa Postal 6198; CEP: 13083-970 – Campinas-SP –
Brasil
Fax: (19) 3788-8600 – Tel: (19) 3788-8729
E-mail: carmenl@unicamp.br