

Advanced non-small cell lung cancer associated with hemophagocytic syndrome in a cachectic patient

Nobuhiro Asai¹
 Yoshihiro Ohkuni¹
 Ryo Matsunuma¹
 Kei Nakashima¹
 Kanichi Iwama²
 Makoto Narita³
 Norihiro Kaneko¹

¹ Department of Pulmonology, Kameda Medical Center, Kamogawa, Japan

² Department of Hematology, Kameda Medical Center, Kamogawa, Japan

³ Department of Pathology, Kameda Medical Center, Chiba, Japan

It is generally known that some viral infections, autoimmune diseases and hematologic malignancies, such as malignant lymphoma, can cause hemophagocytic syndrome (HPS).⁽¹⁻³⁾ In contrast, non-hematologic malignancies associated with HPS have rarely been reported. A case of malignancy-associated hemophagocytic syndrome (MAHS) by non-small cell lung cancer in a cachectic patient to our knowledge has never been reported. Thus, this is the first reported case of MAHS in a lung cancer patient with cachexia syndrome.

A 56-year old man had presented with the chief complaint of high fever and general fatigue for 2 days prior to being referred to us. He has a history of rheumatic arthritis for which had not required any medication. He had stage IV (cT4N3M1, BRA) non-small cell lung cancer (adenocarcinoma) in a cachectic state (body mass index = 17.7 kg/m²) and had received chemotherapy of pemetrexed alone for 2 weeks.

An empirical intravenous therapy of tazobactam/piperacillin was begun for febrile neutropenia because bicytopenia appeared (leukocytes = 3 x 10³/μL; hemoglobin = 9.1 g/dL; platelets = 171 x 10⁹/L). All viral antigen tests including flu, sputum and blood cultures were negative and chest radiography showed no abnormality except for cancer tumor shadow. Seven days after admission, he had fever

associated with pancytopenia (leukocytes = 2.4 x 10³/μL; hemoglobin = 8.9 g/dL; platelets = 83 x 10⁹/L) without any other related symptoms. A bone marrow biopsy revealed HPS (Figure 1) and he was diagnosed as HPS associated with lung cancer. No evidence of cancer metastasis was seen in the bone marrow. Dexamethasone was administered intravenously for 4 days and the pancytopenia improved. As a result the lung cancer progressed and respiratory failure developed. He died on day 28.

While malignant lymphomas associated with HPS have been sporadically demonstrated, secondary HPS caused by non-hematologic malignancies is extremely rare. The pathophysiological mechanism for HPS is still unknown.^(1,2) Some authors have demonstrated that HPS is associated with the release of large numbers of cytokines; cytokine storm.^(1,2) Also, it has previously been described that the level of cytokines such as IL-6 or TNF-α is high in patients with cancer cachexia.^(4,5) Since cytokine storm may be related to the origin of HPS, we can presume that cachectic cancer patients might be at risk for HPS. For clinicians, except for hematologists, HPS is not so common and thus might unfortunately be overlooked. Since pancytopenia can be lethal, it should be cautiously monitored. HPS may possibly develop to disseminated intravascular coagulation and multiple organ dysfunction

Conflict-of-interest disclosure:
 The authors declare no competing financial interest

Submitted: 10/7/2011
 Accepted: 12/4/2011

Corresponding author:
 Nobuhiro Asai
 Department of Pulmonology,
 Kameda Medical Center
 929 Higashi-cho, Kamogawa-city,
 Chiba, Japan
 Phone: 81-4-7099-2211
 nobuhiro0204@hotmail.com

www.rbhh.org or www.scielo.br/rbhh

DOI: 10.5581/1516-8484.20120017

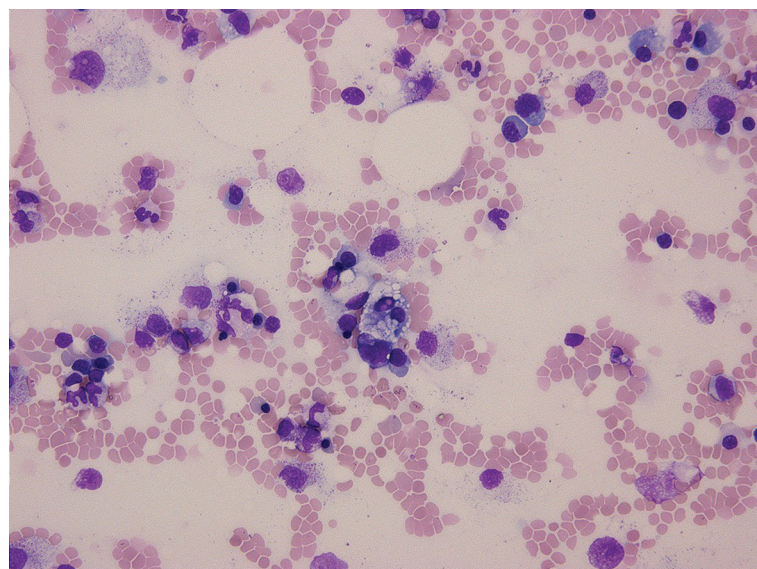


Figure 1 – Bone marrow smear showing macrophages with hemophagocytosis

with high mortality.⁽⁶⁾ On treating with chemotherapy, oncologists tend to regard pancytopenia as related to hematologic toxicities and thus insufficient testing, such as bone marrow aspiration or biopsy, is carried out. We suggest that every clinician should be aware of the possibility of HPS in cancer patients or poor outcomes may result.

In conclusion, cancer patients with cachexia syndrome might be at risk for HPS because of the release of high levels of cytokines such as IL-6 or TNF- α . We suggest that clinicians should keep HPS in mind when treating cancer patients.

Acknowledgement

We are grateful for the diligent and thorough critical reading of our manuscript by Mr. John Wocher, Executive Vice President and Director, International Affairs/International Patient Services, Kameda Medical Center (Japan).

References

1. Fisman DN. Hemophagocytic syndromes and infection. *Emerg Infect Dis.* 2000;6(6):601-8.
2. Karras A, Hermine O. [Hemophagocytic syndrome]. *Rev Med Interne.* 2002;23(9):768-8. French.
3. Kumakura S, Ishikura H, Kondo M, Murakawa Y, Masuda J, Kobayashi S. Autoimmune-associated hemophagocytic syndrome. *Mod Rheumatol.* 2004;14(3):205-15.
4. Dewys WD, Begg C, Lavin PT, Band PR, Bennett JM, Bertino JR, et al. Prognostic effect of weight loss prior to chemotherapy in cancer patients. Eastern Cooperative Oncology Group. *Am J Med.* 1980;69(4):491-7.
5. Esper DH, Harb WA. The cancer cachexia syndrome: a review of metabolic and clinical manifestations. *Nutr Clin Pract.* 2005; 20(4):369-76.
6. Dellinger RP. Inflammation and coagulation: implications for the septic patient. *Clin Infect Dis.* 2003;36(10):1259-65.