

Myelophthisis as first manifestation of failure of chemotherapy in breast cancer

Leonardo Rodrigues de Oliveira
 Thaís Camargos Ferreira
 Antônio Carlos Oliveira de Meneses

Universidade Federal do Triângulo Mineiro -
 UFTM, Uberaba, MG, Brazil

Myelophthisis is a form of bone marrow failure due to the substitution of hematopoietic tissue and its stroma by abnormal tissue^(1,2). We report a case of a 38-year-old woman under investigation for bicytopenia during maintenance chemotherapy (tamoxifen) for breast cancer (diagnosed 3 years previously). Her physical examination was unremarkable except for pallor. There was no hepatosplenomegaly, lymphadenopathy or breast lesions. Laboratory tests showed normochromic and normocytic anemia (Hb 9.1 g/dL) and thrombocytopenia ($117 \times 10^9/L$). A peripheral blood smear showed a typical leukoerythroblastic picture. Bone marrow aspiration (with resistance) and biopsy revealed extensive infiltration by breast ductal carcinoma.

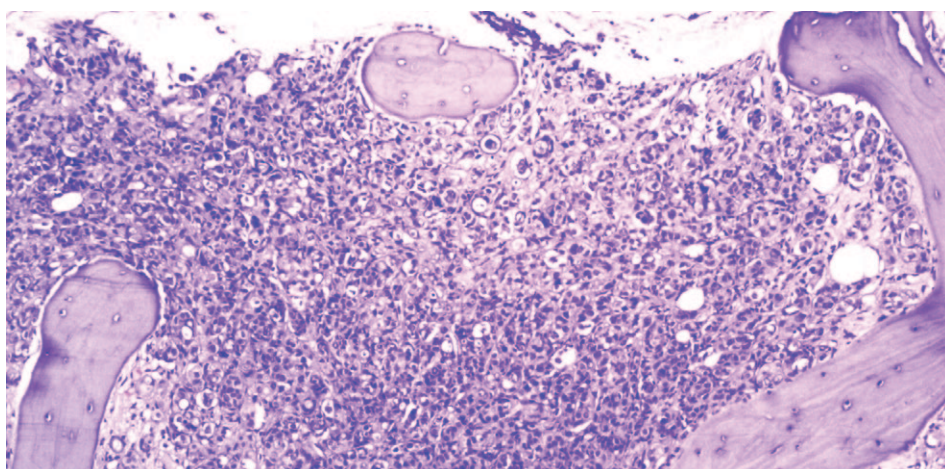


Figure 1 - Bone marrow replaced with metastatic breast ductal carcinoma, H&E stain, original magnification 200X

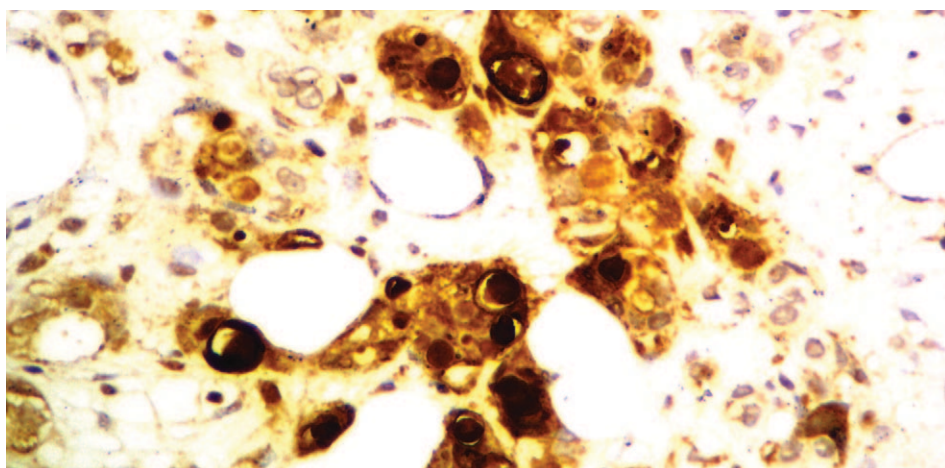


Figure 2 - GCDFP-15 positive breast ductal carcinoma metastatic to bone marrow, immunohistochemistry, original magnification 400X

Conflict-of-interest disclosure:
 The authors declare no competing financial interest

Submitted: 2/25/2012
 Accepted: 4/9/2012

Corresponding author:
 Leonardo Rodrigues de Oliveira
 Central de Quimioterapia - Hospital de
 Clínicas da Universidade Federal do Triângulo
 Mineiro - UFTM
 Rua Getúlio Guaritá, s nº
 38025-440 Uberaba, MG, Brazil
 leonardorodoli@hotmail.com

www.rbhh.org or www.scielo.br/rbhh

DOI: 10.5581/1516-8484.20120059

References

1. Makoni SN, Laber DA. Clinical spectrum of myelophthisis in cancer patients. *Am J Hematol.* 2004;76(1):92-3.
2. D'Angelo G, Hotz AM. Myelophthisis in breast cancer. *Am J Hematol.* 2011;86(1):70-1.