

Article - Human and Animal Health

The Protective Effect of Lercanidipine on Indomethacin-Induced Gastric Ulcers in Rats

Durdu Altuner¹

<https://orcid.org/0000-0002-5756-3459>

Tuğba Kaya¹

<https://orcid.org/0000-0002-7519-4239>

Halis Suleyman^{1*}

<https://orcid.org/0000-0002-9239-4099>

¹Erzincan Binali Yıldırım University, Faculty of Medicine, Department of Pharmacology, Erzincan, Turkey.

Received: 2019.05.19; Accepted: 2019.11.25

*Correspondence: halis.suleyman@gmail.com; Tel.: +90-446-2261818

HIGHLIGHTS

- Indomethacin-induced gastric ulcer model was established in rats.
- The area of ulcer formation in rats given lercanidipine was smaller.
- Lercanidipine changed the oxidant/anti-oxidant balance in favour of the anti-oxidants.
- Lercanidipine inhibited the indomethacin-induced reduction of COX-1 activity.

Abstract: Nonsteroidal anti-inflammatory drugs (NSAID) are among the aggressive factors causing gastric ulcer. They cause oxidative damage in the gastric tissue and lead to intracellular calcium deposition. Lercanidipine is a calcium channel blocker derived from the third generation dihydropyridine. The aim of this study is to analyse the effect of lercanidipine on indomethacin-induced gastric ulcers. A total of 24 albino Wistar male rats were divided into four groups; those who received indomethacin 25 mg/kg (IND), 5 mg/kg lercanidipine +25 mg/kg indomethacin (LC-5), 10 mg/kg lercanidipine+25mg/kg indomethacin (LC-10) and healthy rats who received 0.5 mL distilled water. Six hours after the application of indomethacin, the animals were sacrificed by high dose thiopental sodium. The stomachs of the animals were excised to perform a macroscopic analysis and the ulcerous region was measured on millimeter paper. All the stomachs were subjected to a biochemical analysis. Macroscopic analysis revealed hyperaemia on the gastric surface of the indomethacin group. Ulcerous tissues formed by oval, circular or irregular mucosal defects in varying diameters and depths were observed on the whole surface of the stomach. Hyperaemia was lower and ulcerous region was smaller in groups LC-5 and LC-10 compared to IND group. Malondialdehyde and myeloperoxidase levels were significantly lower and total glutathione and cyclooxygenase-1 activity were higher in groups LC-5 and LC-10. Lercanidipine did not change the cyclooxygenase-2 activity. Lercanidipine in doses 10 mg/kg is more effective compared to 5 mg/kg. Lercanidipine can be useful in the treatment of NSAID-induced gastric damage.

Keywords: lercanidipine; indomethacin; gastric ulcer.

INTRODUCTION

Gastric ulcer occurs when the balance between the aggressive and protective factors gets destroyed in favour of the aggressive factors [1]. Distress, haemorrhagic shock, sepsis, alcohol, smoking, steroid and nonsteroidal anti-inflammatory drugs (NSAID) are among the most well-known aggressive factors today [2]. These factors damage the permeability of the gastric mucosa and lead to intracellular calcium deposition [3]. There are studies reporting that calcium ion induces gastric acid release in in-vivo conditions and leads to gastric mucosal injury [3,4]. Although the aggressive factors causing ulcer may vary, the increased amount of reactive oxygen species (ROS) plays a significant role in the mechanism of the gastric damage caused by all [5]. In addition, the high content of oxidants and low content of anti-oxidants in the damaged tissue shows the significance of the change of the oxidant vs. anti-oxidant balance in favour of the oxidants in the pathogenesis of ulcer [6-8]. The increased concentration of calcium-ion leads to an increase in the production of SOR [9].

Indomethacin, which we used in our study to form an ulcer model, is an indole-derivate NSAID. Indomethacin is preferred in forming an experimental ulcer model owing to its high ulcerogenic potential compared to other NSAIDs [10]. Indomethacin suppresses prostaglandin synthesis by inhibiting the enzymes of both cyclooxygenase-1 (COX-1) and cyclooxygenase-2 (COX-2). COX-2 enzyme is responsible for the anti-inflammatory effect of indomethacin whereas COX-1 enzyme inhibition is responsible for its gastro-intestinal side effect [11]. In literature, indomethacin is reported to be leading to gastric damage by inhibiting the generation of COX-1 enzyme derivative prostaglandin E-2 (PGE-2), bicarbonate and mucus, by promoting the gastric acid secretion, increasing the oxidant parameters and reducing the level of antioxidant parameters [10,12,13].

In our study, we aim to analyse the protective effect of lercanidipine, which is a third generation dihydropyridine derivative calcium channel blocker, on indomethacin-induced gastric ulcer. Comparative therapeutic results showed that lercanidipine was as effective as other dihydropyridine derivatives. Owing to its low potential of side effects, lercanidipine is used in patients who cannot respond to or tolerate antihypertensive drugs [14]. Moreover, lercanidipine was shown to have an antioxidant activity just like other dihydropyridine derivatives [15]. These literature data indicate that lercanidipine could protect the gastric tissue against the indomethacin-induced oxidative damage. The aim of this study is to analyse the effect of lercanidipine on indomethacin-induced gastric ulcers in rats in terms of pharmacology and bio-chemistry.

MATERIAL AND METHODS

Animals

In the experiment, 24 albino Wistar male rats weighing 280-295 grams were used. Before the experiment, the animals were housed and fed in groups at normal room temperature (22 °C) under appropriate conditions. The animals were divided into four groups (n=6, each group); 25 mg/kg indomethacin (IND), 5 mg/kg lercanidipine+25 mg/kg indomethacin (LC-5), 10 mg/kg lercanidipine+25 mg/kg indomethacin (LC-10) and given 0.5 mL distilled water healthy (HG) groups.

Chemicals

Thiopental sodium used in the experiment was obtained from İ.E. Ulagay (Turkey). Lercanidipine was obtained from Recordati Pharma (Turkey) and indomethacin was obtained from Deva Holding (Turkey).

Experimental procedure

Rats were kept hungry for 24 hours for the experiment and then groups LC-5 and LC-10 were gavaged with 5 and 10 mg/kg doses of lercanidipine. Groups HG and IND received equal amounts of distilled water as a solvent. All rat groups (except for HG) were gavaged with 25 mg/kg indomethacin 5 minutes after the application of drugs. The animals were killed, using a high dose of anaesthetic agent (thiopental sodium) six hours after the application of indomethacin. Stomachs of the dead animals were excised to perform a macroscopic analysis on the ulcerous tissues on the gastric surface. The width of these ulcerous regions were measured on a millimetre paper. Then, malondialdehyde (MDA), myeloperoxidase (MPO), total glutathione (tGSH), COX-1 and COX-2 levels of the gastric tissues were measured.

Biochemical analysis

Preparation of samples

The phosphate buffer containing 0.5% hexadecyltrimethyl ammonium bromide pH=6 for the determination of MPO, the potassium chloride solution of 1.15% for the determination of MDA were used. For the other measurements, it was adjusted to 2 mL in phosphate buffer (pH 7.5) and homogenized on ice. Then, it was centrifuged at 10000 rpm at +4 °C for 15 minutes. The supernatant was used as analysis sample.

MDA analysis

The barbituric acid test was used by assessment MDA to define the amount of lipid peroxidation in gastric tissue [16]. MDA levels are expressed as $\mu\text{mol/g}$ protein.

MPO analysis

MPO activity was measured according to the method of Bradley and coauthors [17]. MPO activity are expressed as U/g protein.

tGSH analysis

The amount of tGSH in the stomach tissue was performed according to the method defined by Sedlak and Lindsay [18]. The tGSH levels in the gastric tissue are expressed as nmol/g protein.

Measurement of COX activity

Measurement of COX enzyme activity was performed using commercial kit as previously described [19]

Statistical analysis

The results were shown as “mean \pm standart error of the mean” ($\bar{x}\pm\text{SEM}$). The differences between the groups were defined using one-way ANOVA and followed it Fisher’s post-hoc Tukey test. “SPSS for Windows 18.0” software used for data analysis, and $p<0.05$ was considered statistically significant.

RESULTS

Macroscopic examination

Macroscopic examination of the rats in the indomethacin group revealed ulcerous regions in the stomachs of rats. The gastric surface was evidently hyperaemic. Ulcerous regions were evenly diffused on the gastric surface. These ulcerous regions were formed by oval, circular and irregular mucosal defects in varying diameters and depths. The base of the ulcerous region was whitish, had regular contour and clear borders. There was swelling around the ulcerous region. Hyperaemia was less severe and the ulcerous region was smaller in lercanidipine group compared to indomethacin group. Hyperaemia was less severe in Group LC-10 compared to Group LC-5. Ulcerous region was smaller in Group LC-10 compared to Group LC-5 (Figure 1).

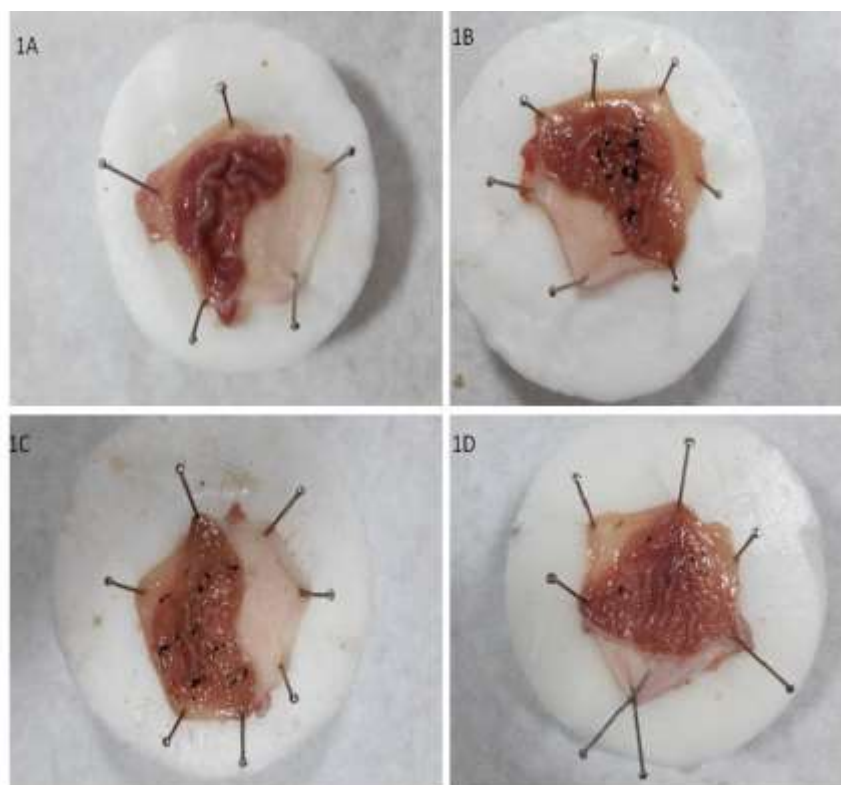


Figure 1. Macroscopic view of ulcer areas in stomach tissues of experimental groups. **1A:** HG group, **1B:** IND group, **1C:** LC-5 group, **1D:** LC-10 group

Ulcerous region measurements

As can be seen on Table 1, the ulcerous region was $58.83 \pm 10.51 \text{ mm}^2$ in IND group and $26.17 \pm 3.92 \text{ mm}^2$ and $13.5 \pm 3.51 \text{ mm}^2$, respectively, in groups LC-5 and LC-10. Lercanidipine is understood to be significantly reducing indomethacin-induced ulcers in 5 and 10 mg/kg doses ($p < 0.005$ and $p < 0.0001$, respectively).

Table 1. Surface measurement of ulcer areas in stomach tissues of experimental groups

Groups	HG	IND	LC-5	LC-10
Surface area (mm^2)	0	$58,83 \pm 10,51$	$26,17 \pm 3,92$	$13,5 \pm 3,51$
Statistical significance (p)	-	< 0.0001	< 0.05	> 0.05

MDA, MPO and tGSH analysis results

The amount of MDA was significantly increased in the animal group subjected to indomethacin, compared to the HG group ($p < 0.0001$). The amount of MDA was significantly less in groups LG-5 and LG-10 compared to IND group ($p < 0.0001$). There was no significant difference between groups HG and LG-10 in terms of the amount of MDA ($p > 0.05$) (Figure 2).

Indomethacin promoted MPO activity in the gastric tissue of the animals. MPO activity in IND group was significantly increased compared to HG group ($p < 0.0001$). MPO activity of groups LG-5 and LG-10 was significantly reduced compared to IND group ($p < 0.0001$). MPO activity of groups HG and LG-10 was similar ($p > 0.05$) (Figure 2).

Indomethacin reduced the amount of tGSH in the gastric tissue. The amount of tGSH in IND group was significantly lower than HG ($p < 0.0001$). The amount of tGSH was significantly increased in the gastric tissue of groups LG-5 and LG-10, whereas there was no significant difference between the amounts of tGSH in groups HG and LG-10 ($p > 0.05$) (Figure 2).

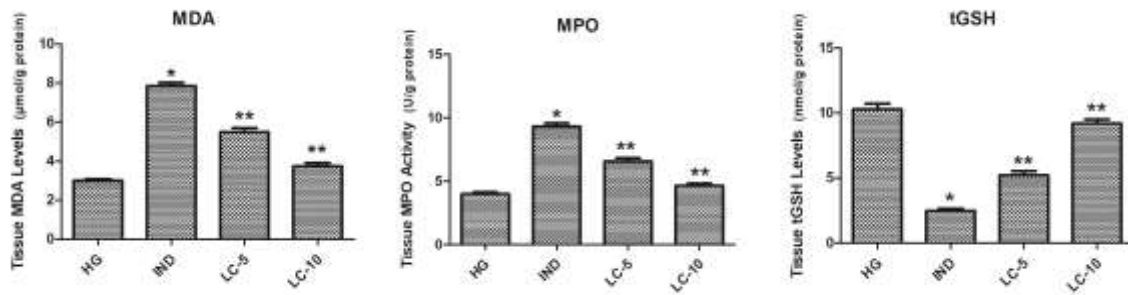


Figure 2. MDA, MPO and tGSH levels in stomach tissues of experimental groups

* $p < 0.0001$, according to HG group

** $p < 0.0001$, according to IND group

COX-1 and COX-2 enzyme activity results

Indomethacin significantly inhibited COX-1 activity in gastric tissue compared to group HG ($p < 0.0001$). COX-1 activity was significantly higher in groups LG-5 and LG-10 compared to IND group ($p < 0.0001$). There was no significant difference between COX-1 activities of groups HG and LG-10 ($p > 0.05$). Indomethacin significantly reduced COX-2 activity in gastric tissue compared to HG ($p < 0.0001$). However; lercanidipine failed to inhibit the reduction of COX-2 activity in 5 and 10 mg/kg doses ($p > 0.05$) (Figure. 3).

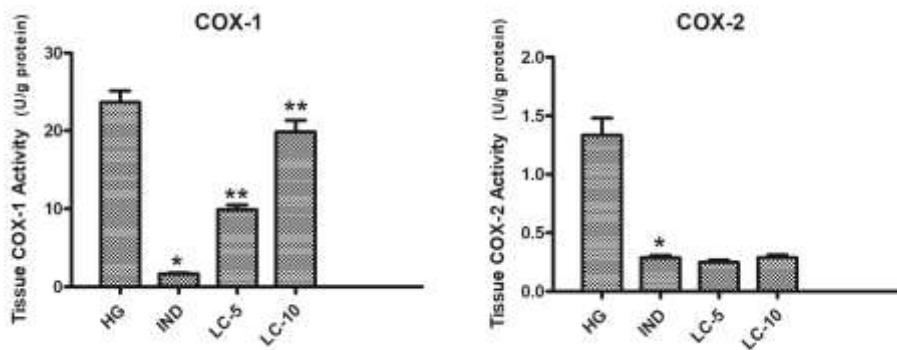


Figure 3. COX-1 and COX-2 activity levels in stomach tissues of experimental groups

* $p < 0.0001$, according to HG group

** $p < 0.0001$, according to IND group

DISCUSSION

NSAIDs are known to increase the prevalence of gastric ulcer and the risk for peptic ulcer at a rate of 15% in endoscopic examination [20]. Indomethacin, among the NSAIDs, is known to be used in the formation of experimental ulcer model in animals, owing to its high ulcerating capacity [6,7,10]. In this study, anti-ulcerating activity of lercanidipine was analysed in indomethacin-induced ulcer model in rats.

25 mg/kg indomethacin was directly gavaged into the stomach in order to form ulcer in the gastric tissue of the animals. In previous studies, 25 mg/kg indomethacin is reported to lead to evident gastric damage [21-24]. In literature, the indomethacin-induced gastric damage is also referred to as the gastric ulcer [25,26]. Our experiment results revealed that indomethacin led to evident ulcer in gastric tissue, which complies with the literature. In a recent study, indomethacin was reported to lead to oxidative damage and multiple gastric ulcers [25]. There are studies suggesting that ROS play a significant role in the pathogenesis of indomethacin-induced gastric damage [27]. ROS cause oxidation of the cellular membrane lipids, and turn them into toxic products, such as the MDA [28]. MDA can significantly damage the membrane proteins by inactivating the membrane receptors and membrane-related enzymes through the cross-linking and polymerization of the components of the membrane [29]. In our study, the increased amount of MDA in the indomethacin group is determined to have reduced owing to the dose used in the group of lercanidipine, which is the Type-L calcium channel antagonist. These results indicate that calcium ions induce the oxidative stress. In a previous study, cytosolic calcium levels were reported to be associated with the lipid peroxidation reaction [30]. There are studies reporting that lipid peroxidation disturbs the cellular calcium homeostasis [31].

Lercanidipine is known to be inhibiting the oxidative stress and lipid peroxidation in extra-gastric tissues [32]. However; we found no study reporting that it protects the gastric tissue from oxidative damage.

In addition, lercanidipine was understood to be inhibiting indomethacin-induced increase of MPO in the gastric tissue more powerfully in 10 mg/kg dose compared to 5 mg/kg dose. Both oral and parenteral application of indomethacin is reported to be increasing MPO activity and to be leading to oxidative damage [33]. There are studies, though limited, supporting that lercanidipine suppresses MPO activity [34]. In a previous study, calcium receptors were reported to exist in polymorph nuclear leucocytes (PMNL) and to be contributing to the regulation of MPO secretion [35]. PMNLs play a significant role in the development of inflammation and tissue damage, by releasing ROS and various inflammatory mediators. Intracellular calcium increase is responsible for the activation of PMNLs and PMNLs are suggested to have a role in the pathogenesis of indomethacin-induced gastric ulcers [36].

Calcium is suggested to play a role not only in the increase of oxidant parameters but also in the reduction of anti-oxidant parameters [37]. Our research findings revealed that the amount of tGSH, which is an endogenous anti-oxidant molecule, significantly decreased in IND group compared to HG. In another study, animals who received indomethacin were reported have increased levels of MDA and MPO and a reduced level of GSH [38]. There are studies reporting that indomethacin reduced the amount of tGSH in gastric tissue [39]. Lercanidipine is known to be protecting the brain tissue from oxidative damage by inhibiting the reduction of the level of GSH [40]. However, we found no study reporting that lercanidipine inhibited the reduction of tGSH in the gastric tissue.

Lercanidipine inhibited the indomethacin-induced reduction of COX-1 activity owing to the dose factor. However, it failed to inhibit the indomethacin-induced reduction of COX-2. While COX-1 and COX-2 are similar, they are different in terms of their functions [41]. COX-1 is a structural enzyme available in tissues and cells. COX-1 produces cyto-protective prostaglandin and is responsible for the maintenance of normal cellular functions. Suppressing COX-1 could result in the reduction of prostaglandin synthesis which reduces mucosal secretion and mucosal blood flow, delays the cellular repair and which could damage the gastric mucosal barrier. COX-2 is reported to show an increase in damaged gastric tissue [42]. We found no study reporting about the effect of lercanidipine on COX in the gastric tissue. However, calcium channel blockers were reported to be inhibiting the gastric basal and stimulated acid secretion and motility [43]. Furthermore, calcium channel blockers were suggested to be protecting the gastric mucosa by increasing the gastric blood flow [44].

CONCLUSION

Indomethacin led to evident oxidative damage in the gastric tissue. It changed the oxidant vs. anti-oxidant balance in favour of the oxidants. Furthermore, it inhibited the structural gastro-protective COX-1 activity. Lercanidipine prevented that the oxidant vs. anti-oxidant balance changed in favour of the oxidants through indomethacin. It inhibited the indomethacin-induced reduction of gastro-protective COX-1 enzyme activity. However, it had no impact on COX-2 enzyme activity. 10 mg/kg dose of lercanidipine was understood to be preventing indomethacin-induced gastric tissue damage better compared to 5 mg/kg dose. These data indicate that lercanidipine could be useful in the treatment of the NSAID-induced gastric damage.

Funding: This research was funded by Scientific Research Projects Unit of Erzincan Binali Yıldırım University, grant number TYL-2017-496.

Conflicts of Interest: The authors declare no conflict of interest.

REFERENCES

1. Monici LT, Zeitune JMR, Lorena SLS, Mesquita M and De Magalhaes AFN. Peptic Ulcer [Úlcera Péptica]. Rev Bras Med. 2003.
2. Woolf A and Rose R. Gastric Ulcer. StatPearls. Treasure Island (FL)2019.
3. Szabo S, Trier J, Brown A and Schnoor J. Early vascular injury and increased vascular permeability in gastric mucosal injury caused by ethanol in the rat. Gastroenterology. 1985;88:228-36.
4. Aadland E and Berstad A. Effect of verapamil on gastric secretion in man. Scand J Gastroentero. 1983;18:969-71.
5. Itoh M and Guth PH. Role of oxygen-derived free radicals in hemorrhagic shock-induced gastric lesions in the rat. Gastroenterology. 1985;88:1162-7.
6. Albayrak A, Alp HH and Suleyman H. Investigation of antiulcer and antioxidant activity of moclobemide in rats. The Eurasian Journal of Medicine. 2015;47:32.

7. Polat B, Albayrak Y, Suleyman B, Dursun H, Odabasoglu F, Yigiter M, et al. Antiulcerative effect of dexmedetomidine on indomethacin-induced gastric ulcer in rats. *Pharmacol Rep.* 2011;63:518-26.
8. Polat B, Suleyman H and Alp HH. Adaptation of rat gastric tissue against indomethacin toxicity. *Chem-Biol Interact.* 2010;186:82-9.
9. Schaffer S, Roy R and McMcord J. Possible role for calmodulin in calcium paradox-induced heart failure. *Eur Heart J.* 1983;4:81-7.
10. Suleyman H, Albayrak A, Bilici M, Cadirci E and Halici Z. Different mechanisms in formation and prevention of indomethacin-induced gastric ulcers. *Inflammation.* 2010;33:224-34.
11. Suleyman H, Demircan B and Karagoz Y. Anti-inflammatory and side effects of cyclo-oxygenase inhibitors. *Pharm Rep.* 2007;59:247.
12. Willoughby DA, Moore AR and Colville-Nash PR. COX-1, COX-2, and COX-3 and the future treatment of chronic inflammatory disease. *Lancet.* 2000;355:646-8.
13. Naito Y, Yoshikawa T, Yoshida N and Kondo M. Role of oxygen radical and lipid peroxidation in indomethacin-induced gastric mucosal injury. *Digest Dis Sci.* 1998;43:30S-4S.
14. Meier P and Burnier M. Lercanidipine, a third generation calcium antagonist. Which advantages? *Rev Med Suisse.* 2006;2: 2047-50, 52-3.
15. Tomlinson B and Benzie I. Antioxidant effect of lercanidipine. *Hypertension* 2003;42.
16. Ohkawa H, Ohishi N and Yagi K. Assay for lipid peroxides in animal tissues by thiobarbituric acid reaction. *Anal Biochem.* 1979;95:351-8.
17. Bradley PP, Priebe DA, Christensen RD and Rothstein G. Measurement of cutaneous inflammation: estimation of neutrophil content with an enzyme marker. *J Invest Dermatol.* 1982;78:206-9.
18. Sedlak J and Lindsay RH. Estimation of total, protein-bound, and nonprotein sulfhydryl groups in tissue with Ellman's reagent. *Anal Biochem.* 1968;25:192-205.
19. Cimen O, Cimen FK, Gulaboglu M, Bilgin AO, Cekic AB, Eken H, et al. The effect of metyrosine on oxidative gastric damage induced by ischemia/reperfusion in rats. Biochemical and histopathological evaluation. *Acta Cir Bras.* 2018;33:259-67.
20. Shin SJ, Noh C-K, Lim SG, Lee KM and Lee KJ. Non-steroidal anti-inflammatory drug-induced enteropathy. *Intest Res.* 2017;15:446.
21. Suleyman H, Cadirci E, Albayrak A, Polat B, Halici Z, Koc, F, et al. Comparative study on the gastroprotective potential of some antidepressants in indomethacin-induced ulcer in rats. *Chem-Biol Interact.* 2009;180:318-24.
22. Kuruuzum-Uz A, Suleyman H, Cadirci E, Guvenalp Z and Demirezer LO. Investigation on anti-inflammatory and antiulcer activities of *Anchusa azurea* extracts and their major constituent rosmarinic acid. *Z Naturforsch C.* 2012;67:360-6.
23. Albayrak F, Odabasoglu F, Halici Z, Polat B, Dursun H, Uyanik A, et al. The role of erythropoietin in the protection of gastric mucosa from indometacin-induced gastric injury and its relationship with oxidant and antioxidant parameters in rats. *J Pharm Pharmacol.* 2010;62:85-90.
24. Albayrak A, Polat B, Cadirci E, Hacimuftuoglu A, Halici Z, Gulapoglu M, et al. Gastric anti-ulcerative and anti-inflammatory activity of metyrosine in rats. *Pharmacol Rep.* 2010;62:113-9.
25. Hafez H, Morsy M, Mohamed M and Zenhom N. Mechanisms underlying gastroprotective effect of paeonol against indomethacin-induced ulcer in rats. *Hum Exp Toxicol.* 2019;38:510-8.
26. Rofaeil RR and Gaber SS. Gastroprotective effect of memantine in indomethacin-induced peptic ulcer in rats, a possible role for potassium channels. *Life Sci.* 2019;217:164-8.
27. Tarnasky PR, Livingston EH, Jacobs KM, Zimmerman BJ, Guth PH and Garrick TR. Role of oxyradicals in cold water immersion restraint-induced gastric mucosal injury in the rat. *Dig Dis Sci.* 1990;35:173-7.
28. Kisaoglu A, Borekci B, Yapca OE, Bilen H and Suleyman H. Tissue damage and oxidant/antioxidant balance. *The Eurasian Journal of Medicine.* 2013;45:47.
29. Goulart M, Batoreu M, Rodrigues A, Laires A and Rueff J. Lipoperoxidation products and thiol antioxidants in chromium exposed workers. *Mutagenesis.* 2005;20:311-5.
30. Şahin E, Yeşim Göçmen A, Gümüşlü S, Sahin M, Koçak H and Tuncer M. Lipid Peroxidation and Parathyroid Hormone Influence the Cytosolic Calcium Levels of Erythrocytes in Peritoneal Dialysis Patients. *Clin Lab.* 2011;57:551.
31. Bhatti G, Bhatti J, Kiran R and Sandhir R. Alterations in Ca²⁺ homeostasis and oxidative damage induced by ethion in erythrocytes of Wistar rats: ameliorative effect of vitamin E. *Environ Toxicol Phar.* 2011;31:378-86.
32. Digiesi V, Fiorillo C, Cosmi L, Rossetti M, Lenuzza M, Guidi D, et al. Reactive oxygen species and antioxidant status in essential arterial hypertension during therapy with dihydropyridine calcium channel antagonists. *La Clinica Terapeutica.* 2000;151:15-8.

33. Minaiyan M, Sajjadi S-E and Amini K. Antiulcer effects of *Zataria multiflora* Boiss. on indomethacin-induced gastric ulcer in rats. *Avicenna journal of phytomedicine*. 2018;8:408.
34. Derosa G, Bonaventura A, Romano D, Bianchi L, Fogari E, D'Angelo A, et al. Effects of enalapril/lercanidipine combination on some emerging biomarkers in cardiovascular risk stratification in hypertensive patients. *J Clin Pharm Ther*. 2014;39:277-85.
35. Zhai T-y, Cui B-h, Zou L, Zeng J-y, Gao S, Zhao Q, et al. Expression and Role of the Calcium-Sensing Receptor in Rat Peripheral Blood Polymorphonuclear Neutrophils. *Oxidative medicine and cellular longevity*. 2017; Article ID 3869561.
36. Murakami K, Okajima K, Harada N, Isobe H, Liu W, Johno M, et al. Plaunotol prevents indomethacin-induced gastric mucosal injury in rats by inhibiting neutrophil activation. *Aliment Pharm Ther*. 1999;13:521-30.
37. Fang X, Wu C, Li H, Yuan W and Wang X. Elevation of intracellular calcium and oxidative stress is involved in perfluorononanoic acid-induced neurotoxicity. *Toxicol Ind Health*. 2018;34:139-45.
38. Kolgazi M, Cantali-Ozturk C, Deniz R, Ozdemir-Kumral ZN, Yuksel M, Sirvanci S, et al. Nesfatin-1 alleviates gastric damage via direct antioxidant mechanisms. *J Surg Res*. 2015;193:111-8.
39. Tarique M, Siddiqui HH, Khushtar M and Rahman MA. Protective effect of hydro-alcoholic extract of *Ruta graveolens* Linn. leaves on indomethacin and pylorus ligation-induced gastric ulcer in rats. *J Ayurveda Integr Med*. 2016;7:38-43.
40. Gupta S, Sharma U, Jagannathan NR and Gupta YK. Neuroprotective effect of lercanidipine in middle cerebral artery occlusion model of stroke in rats. *Exp Neurol*. 2017;288:25-37.
41. Crofford LJ. COX-1 and COX-2 tissue expression: implications and predictions. *J Rheumatol Suppl*. 1997;49:15-9.
42. Dubois RN, Abramson SB, Crofford L, Gupta RA, Simon LS, Van De Putte LB, et al. Cyclooxygenase in biology and disease. *FASEB J* 1998;12:1063-73.
43. Nielsen ST and Sulkowski TS. Protection by the calcium antagonist Wy-47,037 against stress ulceration in the rat. *Pharmacol Biochem Be*. 1988;29:129-32.
44. Ghanayem BI, Matthews HB and Maronpot RR. Calcium channel blockers protect against ethanol- and indomethacin-induced gastric lesions in rats. *Gastroenterology*. 1987;92:106-11.



© 2020 by the authors. Submitted for possible open access publication under the terms and conditions of the Creative Commons Attribution (CC BY NC) license (<https://creativecommons.org/licenses/by-nc/4.0/>).