

FALSE POSITIVE REACTION DUE TO ENDOGENOUS BIOTIN ACTIVITY IN GLANDULAR EPITHELIUM OF DECIDUA

Liliana Cruz Spano^{1*}; Paulo Roberto Merçon de Vargas^{1,2}; José Paulo Gagliardi Leite³; Jussara Pereira do Nascimento⁴

¹Departamento de Patologia e Núcleo de Doenças Infecciosas, Centro Biomédico, Universidade Federal do Espírito Santo, Vitória, Espírito Santo, Brasil. ²Laboratório de Patologia, Hospital Universitário Cassiano Antônio de Moraes, Universidade Federal do Espírito Santo, Brasil. ³Laboratório de Virologia Comparada, Departamento de Virologia, Instituto Oswaldo Cruz, FIOCRUZ, Rio de Janeiro, Brasil. ⁴Departamento de Microbiologia e Parasitologia, Instituto Biomédico da Universidade Federal Fluminense, Niterói, RJ, Brasil.

Submitted: April 14, 2004; Returned to authors for corrections: October 28, 2004; Approved: June 28, 2005

ABSTRACT

Biotin-labeled probe was used in an *in situ* hybridisation assay to localize virus infection in formalin-fixed, paraffin embedded tissues taken from eleven abortion cases. Probes for human cytomegalovirus (HCMV), human Parvovirus B19 (B19) and human adenovirus type 2 (HAD2), were labeled with biotin-11-dUTP by nick-translation reaction. Streptavidin-alkaline-phosphatase (SAP) was used to detect biotin, followed by 4-nitroblue tetrazolium/5-bromo-4-chloro-3-indolyl phosphate (NBT/BCIP) solution. Positive reaction was observed in nucleus of glandular epithelium cells of decidua either in positive or in negative control at first and second gestational trimester. The reaction was not inhibited with blocking solution for alkaline phosphatase endogenous activity and it persisted even with probes omission. The use of adequate negative control permitted to reveal the presence of nuclear biotin in glandular epithelium of decidua, responsible for false positivity in detection systems involving streptavidin biotin system (StrepABC). The stained cells resembled to cytophatic effect due to herpesvirus, which could induce further misinterpretation. The results obtained in this study strongly recommend that DNA detection by *in situ* hybridisation reaction in gestational endometrium should be done without using StrepABC system.

Key words: endogenous biotin, glandular epithelium of decidua, biotinylated probes, *in situ* hybridisation, citomegalovirus

INTRODUCTION

In situ hybridisation for viral nucleic acids has been used in clinical and research laboratories for the detection of DNA and RNA sequences, identifying the kind of infected cells and its tissue localization, beyond the possibility to localize the virus in different compartments, either nucleus or cytoplasm. Among distinct detection systems, biotin-avidin has attracted interest. The advantages of this system include rapid detection, improved microscopic resolution, stability on prolonged storage and avoidance of the risks involved when isotopic probes are used. Biotinylated probe is detected by incubation with

Streptavidin, which has been chemically coupled to an enzyme catalyzing a colorimetric reaction. The disadvantage is the pitfall that could result from endogenous biotin activity.

Human cytomegalovirus (HCMV) is the most common viral agent associated with congenital infections (1,25). Virus, viral antigens and nucleic acid were detected in conception tissues obtained from abortion cases (6,7,11,13,21,23,25,27), although the association with pregnancy loss is uncertain. The virus can infect different host tissues including endometrial cells, from where it can reactivate intermittently (10,16,19) and infect the placenta during gestation. High HCMV seroprevalence is reported worldwide, including Brazil (22).

*Corresponding Author. Mailing address: Departamento de Patologia e Núcleo de Doenças Infecciosas, Centro Biomédico, UFES. Av. Marechal Campos, 1468, Maruípe. 29040-091, Vitória, ES, Brasil. Tel.: (+5527) 3335-7210, Fax: (+5527) 3335-7206. E-mail: lspano@ndi.ufes.br

We explored the use of *in situ* hybridisation assay using biotinylated labeled HCMV-DNA probes to detect HCMV DNA on formalin fixed, paraffin embedded sections of products of conception, obtained from abortion cases. These tissues were previously submitted to HCMV DNA amplification by nestedPCR (25), what could represent only latent infection. Therefore, positive and negative cases were then studied.

The result here obtained reinforces the importance that *in situ* hybridisation and immunohistochemistry should be done with adequate positive and negative tissue control and in addition, stress the importance of the employment of different detection system available to avoid false positive results.

MATERIALS AND METHODS

Specimens

Eleven cases of abortion, five positive for HCMV gB glycoprotein by PCR/Nested-PCR and six negative were included in the study, some of them, previously described (25). One up to three paraffin embedded blocks from aborted products of each case were processed. They consisted of decidua and in most of them chorionic villi were represented. Fetal tissues were not obtained from these same cases. Five cases were at first and six cases were at second gestational trimester.

The specimens were obtained from HCMV seropositive patients in abortion process, attended at the Maternity Unit of the Federal University of Espírito Santo (UFES), or at Pró-Matre Hospital, both at Vitória city, the capital of Espírito Santo State, Southern Brazil. This study obtained the approval by the Ethical Research Council of Biomedical Center of UFES. Positive controls were tissues obtained from a fatal case of HCMV congenital infection.

Biotinylated probes

HCMV probes were constructed with *Hind*III fragments O, S and V cloned into pAT153 plasmid and were kindly provided by Dr Peter Greenaway (Public Health Laboratory Service, Salisbury, UK). B19 virus probe was constructed inserting 5.2Kb B19 DNA into pGEM-1 plasmid (17) and HAd2 probe, with a cloned insertion of the *Bam*HI fragments C and D of HAd2 into pAT153 plasmid (9). Probes labeling were carried out by incorporation of biotin-11-dUTP (Sigma Inc, Missouri, USA) using a Nick-Translation kit (Invitrogen, Galthersburg, USA) and following recommended protocol by manufacturer. Non-incorporated dNTPs were separated from the labeled DNA by exclusion chromatography on Sephadex G-50 (14). Biotinylated B19 virus and HAd2 probes were used as negative control, to check non-specific probe binding on each tested tissue.

Pretreatment of cells

Five micrometers slices of decidua and chorionic villi tissues were deparaffinized and rehydrated. Loosening of sections was

prevented by previous slides treatment with 3-aminopropyl-triethoxysilane (Sigma Inc), applied to the glass slides at a concentration of 2.5% in 100% ethanol. The sections were treated with 250 µg/mL proteinase K (Invitrogen) to allow the probe penetration.

Hybridisation reaction

In situ hybridisation reaction was performed as described by Nascimento *et al.* (18), excepting by the denaturation process. Hybridisation mixtures containing biotinylated probes with a final concentration of 10 ng/µL, were placed on the sections, covered with coverslip, and submitted to DNA denaturation in microwave for two min in high potency with water-bath protecting against parching. Hybridisation occurred at 37°C during two hours in a moist chamber. After hybridisation sections were washed in stringent conditions (18).

Developing

The sections were covered with streptavidin-alkaline-phosphatase conjugate (SAP, Amersham, New Jersey, USA), according to Nascimento *et al.* (18). The hybridisation signal was visualized by 4-nitroblue tetrazolium/5-bromo-4-chloro-3-indolyl phosphate (NBT/BCIP, Sigma Inc) system, according to recommended protocol (Invitrogen “BluGENE”). After color development, 20 min to 1 hour, the reaction was stopped dipping the slides in 0.15M PBS, pH 7.2.

Topographic determination

Histological routine staining with eosin in 8 from 11 cases did the determination of topographic positivity. The three remaining cases (negatives for HCMV by PCR/nestedPCR) could not be examined because the specimens or slides were no longer available.

RESULTS

Positive signals were observed in cells' nuclei. In many cells the marker was more intense at the periphery of nucleus, with a clear central zone, forming optically clear nucleus (OCN), sometimes resembling to herpesvirus inclusion (Fig. 1). However, the signal could be also observed when biotin labeled probe to B19 virus was used as a negative control. To exclude the possibility of viral coinfection, HCMV and B19 virus, biotinylated probe to HAd2 was employed and, once more, the positive signal was present. Periodic acid solution (0.109 µg/mL) added to exclude alkaline phosphatase endogenous activity did not abolish the reaction in negative controls. When biotinylated probes were excluded and only SAP was applied followed by the substrate solution, the reaction persisted positive, what clearly indicated that the SAP was binding to biotin present in tissue. The reaction was not observed with only substrate solution addition.

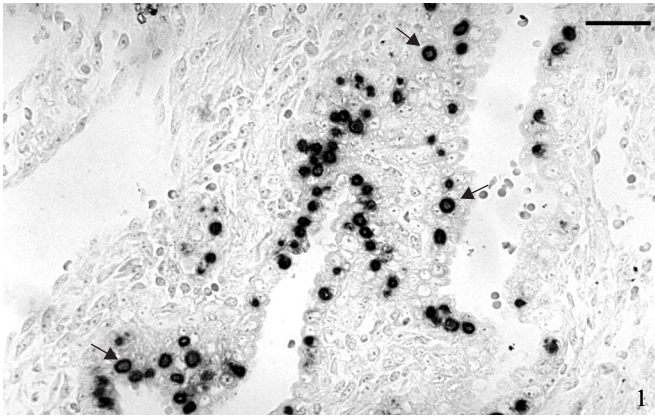


Figure 1. False positive staining of cell nuclei in the glandular epithelium of decidua, obtained from abortion case. Streptavidin-biotin reaction using biotinylated HCMV probe after developing with NBT/BCIP. Note more intense staining at the periphery of the nuclei leaving a clear central zone – OCN (arrow), resembling inclusion bodies. Bar = 30 μ m.

Table 1. Endogenous biotin activity obtained in abortion cases submitted to *in situ* hybridisation using biotinylated probe for HCMV detection: association with gestational age, number of cells with reaction for endogenous biotin and topography of tissue.

Cases	Block	Gest. Age ^a	Cells with Reaction ^b	Topography ^c					
				EV	EG	ES	TB	W	VS
1	A	12-13	1	∅	+	∅	∅	∅	∅
2	A	6	1	∅	+	∅	∅	∅	∅
	B		1-3	∅	+	∅	∅	∅	∅
	C		1	∅	+	∅	∅	∅	∅
3	A	10	1	∅	+	∅	∅	∅	∅
			1	∅	+	∅	∅	∅	∅
4	B	11	1	∅	+	∅	∅	∅	∅
5	A	13	2	∅	+	∅	-	-	-
	B		1-2	∅	+	∅	-	-	-
6	A	14	3	∅	+	∅	∅	∅	∅
	B		1	∅	+	∅	∅	∅	∅
7	A	17	3	∅	+	∅	-	-	-
	B		3	∅	+	∅	-	-	-
	C		3	∅	+	∅	-	-	-
8	A	6	0	∅	∅	∅	∅	∅	∅

^a Estimated gestational age in post-menstrual weeks at termination;

^b 0 no reaction, 1 few cells with positive reaction for endogenous biotin, 2 moderate positive cells, 3 many positive cells;

^c + present with positive reaction, ∅ present with negative reaction, - tissue not represented;

EV: endometrial vessels; EG: endometrial glands; ES: endometrial stroma; TB: trophoblast; VV: villous vessels; VS: villous stroma.

All positive reactions were present in glandular epithelium of decidua, mostly where there was Arias-Stella reaction. No positive reaction was observed after evaluation of trophoblast and villous or endometrial vessels and stroma. Positive signal was observed in different number of cells, varying from few to many positive cells by section in a same block or among different blocks from the same case (Table 1). From the positive cases, the gestational age at abortion varied from 5 up to 17 post-menstrual weeks. Although cases with greater number of cells with positive signal had been observed beyond 13 weeks of gestational age at abortion, in one case, at 6 weeks of gestational age at abortion (case 2), it varied among different blocks from few to many cells (Table 1).

Among 11 cases studied, 10 presented biotin reaction, making impossible any interpretation of the data regarding to HCMV infection. In three of them (cases 9, 10 and 11), it was not possible to determine the topographic location of the positive reaction due to the lack of available tissue.

DISCUSSION AND CONCLUSION

This study involved *in situ* hybridisation reaction with biotinylated probe to different regions of HCMV genome, aiming the detection of HCMV infection in decidua and chorionic villi tissues obtained from abortion cases. This *in situ* hybridisation methodology did not allow the viral localization in tissue, because the positive signal was also found in negative control, characterizing non-specific HCMV detection. The observed non-specificity was associated mostly where there was Arias-Stella reaction, which corresponds to a high excretive gland epithelium due to increased gonadotrophin and progesterone stimulation (2). These cells have been described consisting of hyperchromatic nuclei with a clear central area, a ground-glass appearance, given origin to the name of “optically clear nuclei” (OCN) (15). Through studies in electron microscopy, they are characterized by replacement of the central portion of the nucleus by filamentous substructures of chromatin, with heterochromatin margination (26).

Variation in amount and in topographic distribution of the positive signal in tissue from a same block or among blocks from a same case is an interesting finding. It suggests that cells with OCN could suffer some influence from the tissue around. In fact, Mazur *et al.* (15) suggested a paracrine effect of trophoblastic cells on clearing of endometrial epithelium nuclei.

Biotin is a coenzyme that participates in reactions where CO₂ is carried by carboxylase, transcarboxylase and decarboxylase (29). It has been described in some tissues as liver, kidney, adipose tissue and muscles

(5,28,29). When biotin is present in accumulated state it can interfere with reactions that might involve StrepABC by specific binding of avidin to endogenous biotin. The streptavidin used to detect biotinylated HCMV, B19 virus or HAd probes was in fact binding to nuclear cell biotin. Few studies previously reported called attention to the fact that endogenous biotin is observed in glandular epithelium of decidua, the gestational associated endometrium (20,31).

The explanation for the biotin accumulation in nucleus in some pathological process or in gestational endometrium is not currently known. In conformity to Yokoyama *et al.* (31), biotin is required for intense gluconeogenesis reaction during early gestation and thereafter the excess is stored in nucleus because it would be no more required for gluconeogenesis after placentation. Although Yokoyama *et al.* (31) observed biotin only beyond 16th gestational week age, Mazur *et al.* (15) and the present study showed that it could be detected in earlier gestational age. Therefore, detection system using biotinylated label, must be avoid even at first gestational trimester, mostly when decidua is present. However, there is no problem when chorionic villous is the tissue in study.

Diagnostic problem could emerge when cells with OCN, that have been showed to be associated with nuclear biotin deposit, is histologically confounded with human herpesviruses inclusion, as was observed, yielding to a mistaken diagnosis. Therefore, specific determination of viral infection is essential to avoid this problem with those less experienced in pathologic evaluation. On the other hand, when one decides to establish viruses' diagnosis using methodologies that involve avidin-biotin reaction, other alternatives for diagnostic marker have to be considered in cases of false positive reaction (3,8,12,30).

To resolve the problem of endogenous biotin, Wood and Warnke (28) suggested the use of free avidin and free biotin for blocking undesired reaction. Although Tanaka *et al.* (26) and Sickel and Sant'Agnes (20) blocked false-positive immunostaining by the avidin-biotin peroxidase complex method in pancreatoblastoma or in gestational endometrium, respectively, Cooper *et al.* (4) using this same methodology, did not avoid endogenous biotin activity in gestational endometrium.

Due to a cost reason, biotinylated probes were used in this study. However, considering the possibility of encountering false positive signals and the fact that biotin is not always effectively blocked by free avidin and biotin (4), we suggest the use of other probe labeling system, in order to overcome undesirable reactions from StrepABC. Furthermore, if adequate negative controls are included in the assay, one could safely detect false positive reaction, which will minimize misinterpretations.

ACKNOWLEDGEMENTS

We are grateful to medical staff of the Pró-Matre Hospital and of the Maternity Unit of the Federal University of Espírito

Santo (UFES), Brazil. We also thank to Dr Flavya de Souza Ribeiro for support in pathology service and to Fundação Oswaldo Cruz (FIOCRUZ), Rio de Janeiro, Brazil, where the technical proceedings were realized. This work was partially supported by grants from Coordenação de Pessoal de Nível Superior (CAPES), Conselho Nacional de Desenvolvimento Científico e Tecnológico (CNPq) and Fundação de Amparo à Pesquisa do Estado do Rio de Janeiro (FAPERJ), Brazil.

RESUMO

Reação falso positiva em epitélio glandular da decídua devido a atividade endógena de biotina

Sondas marcadas com biotina foram utilizadas neste trabalho para detecção de infecção viral por hibridização *in situ* em tecidos fixados com formalina e embebidos em parafina de 11 casos obtidos de abortamento. Sondas para citomegalovírus humano (HCMV), parvovírus B19 humano (B19) e adenovírus humano tipo 2 (HAd2), foram marcadas com biotina-11-dUTP através da reação de *nick-translation*. Estreptavidina conjugada com fosfatase alcalina (SAP) seguida por solução de 4-nitro-azul de tetrazolio/5-bromo-4-cloro-3-indolil fosfato (NBT/BCIP) foram utilizadas para detecção da biotina após a reação de hibridização. Reação positiva foi observada no núcleo de células do epitélio glandular da decídua tanto no controle positivo quanto no negativo em tecidos de primeiro e segundo trimestre gestacional. Esta reação não foi inibida com solução bloqueadora da atividade endógena de fosfatase alcalina e persistiu mesmo com a omissão das sondas. O uso de controles negativos permitiu revelar atividade endógena de biotina nuclear em epitélio glandular da decídua, responsável por reações falso positivas em sistemas de detecção estreptavidina-biotina (StrepABC). Os resultados obtidos neste estudo fortemente recomendam que a detecção de ADN por hibridização *in situ* em endométrio gestacional seja feita com outro sistema de detecção que não o StrepABC.

Palavras-chave: Biotina endógena, epitélio glandular da decídua, sondas biotiniladas, hibridização *in situ*, citomegalovírus

REFERENCES

1. Alford, C.A.; Stagno, S.; Pass R.F.; Britt, W.J. Congenital and perinatal cytomegalovirus infection. *Rev. Infect. Dis.*, 12(S7), 745-753, 1990.
2. Arias-Stella, J. The Arias-Stella reaction: facts and fancies four decades after. *Adv. Anat. Pathol.*, 9, 12-23, 2002.
3. Barker, F.G.; Ozua P.; Van Noorden, S. False positive immunoreaction in products of conception. *J. Clin. Pathol.*, 47, 1118-9, 1994.
4. Cooper, K.; Haffajee, Z.; Taylor, L. Comparative analysis of biotin intranuclear inclusions of gestational endometrium using the APAAP, ABC and the PAP immunodetection systems. *J. Clin. Pathol.*, 50, 153-156, 1977.

5. Dakshinamurti, K.; Mistry, S.P. Tissue and intracellular distribution of biotin- C^{14} OOH in rats and chicks. *J. Biol. Chem.*, 238, 294-296, 1963.
6. Dong, Z.W.; Yan, C.; Yi, W.; Cui, Y.Q. Detection of congenital cytomegalovirus infection by using chorionic villi of the early pregnancy and polymerase chain reaction. *Int. J. Gynecol. Obstet.*, 44, 229-231, 1994.
7. Fisher, S.; Genbacev, O.; Maidji, E.; Pereira, L. Human cytomegalovirus infection of placental cytotrophoblasts in vitro and in utero: implications for transmission and pathogenesis. *J. Virol.*, 74, 6808-6820, 2000.
8. Fox, H. Letter to the editor: Detection of *Herpes simplex* virus DNA in spontaneous abortions from HIV-positive women using non-isotopic *in situ* hybridization. *J. Pathol.*, 179, 125, 1996.
9. Gomes, S.A.; Nascimento, J.P.; Siqueira, M.M.; Krawczuk, M.M.; Pereira, H.G.; Russel, W.C. *In situ* hybridisation with biotinylated DNA probes: A rapid diagnostic test for adenovirus upper respiratory infections. *J. Virol. Methods.*, 12, 105-110, 1985.
10. Gradilone, A.; Vercillo, R.; Napolitano, M.; Cardinali, G.; Gazzaniga, P.; Silvestri, I.; Gandini, O.; Tomao, S.; Aglianò, A.M. Prevalence of human papillomavirus, cytomegalovirus, and Epstein-Barr virus in the cervix of healthy women. *J. Med. Virol.*, 50, 1-4, 1996.
11. Kriel, R.L.; Gates, G.A.; Wulpf, H.; Powell, N.; Pland, J.D.; Chin, T.D.Y. Cytomegalovirus isolations associated with pregnancy wastage. *Amer. J. Obstet. Gynec.*, 160, 885-892, 1970.
12. Leteurtre, E.; Boman, F.; Gosselin, B. Inclusions intranucléaires pseudoherpétiques riches en biotin. Un piège diagnostique. *Clin. Exp. Path.*, 1, 44-47, 1999.
13. Malhomme, O.; Dutheil, N.; Rabreau, M.; Armbruster-Moraes, E.; Schlehofer, J.R.; Dupressoir, T. Human genital tissues containing DNA of adeno-associated virus lack DNA sequences of the helper viruses adenovirus, herpes simplex virus or cytomegalovirus but frequently contain human papillomavirus DNA. *J. Gen. Virol.*, 78, 1957-1962, 1997.
14. Maniatis, T.; Fritsch, E.F.; Sambrook, J. *Molecular Cloning. A Laboratory Manual*. Cold Spring Harbor Laboratory, New York, 1982, p. 466-467.
15. Mazur, M.T.; Hendrickson, M.R.; Kempson, R.L. Optically clear nuclei. An alteration of endometrial epithelium in the presence of trophoblast. *Am. J. Surg. Pathol.* 7, 415-423, 1983.
16. Montgomery, R.; Youngblood, L.; Medearis, D.N.Jr. Recovery of cytomegalovirus from the cervix in pregnancy. *Pediatrics.*, 49, 524-531, 1972.
17. Mori, J.; Field, A.M.; Clewley, J.P.; Cohen, B.J. Dot blot hybridisation assay of B19 virus DNA in clinical specimens. *J. Clin. Microbiol.*, 27, 459-464, 1989.
18. Nascimento, J.P.; Hallam, N.F.; Mori, J.; Anne, M.F.; Clewley, J.P.; Brown, K.E.; Cohen, B.J. Detection of B19 Parvovirus in human fetal tissues by *in situ* hybridisation. *J. Med. Virol.*, 33, 77-82, 1991.
19. Schön, H.J.; Schurz, B.; Marz, R.; Knogler, W.; Kubista, E. Screening for Epstein-Barr and human cytomegalovirus in normal and abnormal cervical smears by fluorescent *in situ* cytohybridization. *Arch. Virol.*, 125, 205-214, 1992.
20. Sickel, J.K.; Sant'Agnes, A. Anomalous immunostaining of "optically clear" nuclei in gestational endometrium. A potential pitfall in the diagnosis of pregnancy-related herpesvirus infection. *Arch. Pathol. Lab. Med.*, 118, 831-833, 1994.
21. Sifakis, S.; Ergazaki, M.; Sourvinos, G.; Koffa, M.; Koumantakis, E.; Spandidos, D.A. Evaluation of B19, HCMV and HPV viruses in human aborted material using the polymerase chain reaction technique. *Eur. J. Obst. Reprod. Biol.*, 76, 169-173, 1998.
22. Spano, L.C.; Gatti, J.; Nascimento, J.P.; Leite, J.P.G. Prevalence of human cytomegalovirus infection in pregnant and non-pregnant women. *J. Infect.*, 48, 213-220, 2004.
23. Spano, L.C.; Pereira, F.E.L.P.; Basso, N.G.S.; Vargas, P.R.M. Human cytomegalovirus infection and abortion: an immunohistochemical study. *Med. Sc. Mon.*, 8, 230-235, 2002.
24. Spano, L.C.; Vargas, P.R.M.; Ribeiro, F.S.; Leite, J.P.G.; Nascimento, J.P. Cytomegalovirus in human abortion in Espírito Santo, Brazil. *J. Clin. Virol.*, 25, 173-178, 2002.
25. Stagno, S.; Pass, F.R.; Dworsk, M.; Alford, C.A. Maternal cytomegalovirus infection and perinatal transmission. *Clin. Obstet.*, 25, 563-573, 1982.
26. Tanaka, Y.; Ijiri, R.; Yamanaka, S.; Kato, K.; Nishihira, H.; Nishi, T.; Misugi, K. Pancreatoblastoma: optically clear nuclei in squamoid corpuscles are rich in biotin. *Mod. Pathol.*, 11, 945-949, 1998.
27. vanLisjnchoten, G.; Stals, F.; Evers, J.L.; Bruggeman, C.A.; Havenith, M.H.; Geraedts, J.P. The presence of cytomegalovirus antigens in karyotyped abortions. *Am. J. Reprod. Immunol.*, 32, 211-220, 1994.
28. Wood, G.S.; Warnke, R. Suppression of endogenous avidin-binding activity in tissues and its relevance to biotin-avidin detection systems. *J. Histochem. Cytochem.*, 29, 1196-1204, 1981.
29. Wood, H.G.; Barden, R.E. Biotin enzymes. *Ann. Rev. Biochem.*, 46, 385-413, 1977.
30. Wright, C.A.; Haffajee, Z.; van Iddekinge, B.; Cooper, K. Detection of *Herpes simplex* virus DNA in spontaneous abortions from HIV-positive women using non-isotopic *in situ* hybridization. *J. Pathol.*, 176, 399-402, 1995.
31. Yokoyama, S.; Kashima, K.; Inoue, S.; Daa, T.; Nakayama, I.; Moriuchi, A.A. Biotin-containing intranuclear inclusions in endometrial glands during gestation and puerperium. *Anat. Pathol.*, 99, 13-17, 1993.