



Effects of the anabolic steroid nandrolone on the soleum muscle of rats submitted to physical training through swimming: histological, histochemical and morphometrical study

José Carlos Silva Camargo Filho¹, Luiz Carlos Marques Vanderlei¹, Regina Celi Trindade Camargo¹, Fabiana Acorse Francischeti¹, Willian Dias Belangero² and Vitalino Dal Pai¹

ABSTRACT

The objective of this study was to analyze the histological, histochemical and morphometrical alterations of the fibers from the soleum muscle of rats submitted to a swimming program, associated or not to the administration of the anabolic steroid decanoate of nandrolone. 22 male Wistar rats were used, 12 of which received a muscle injection of steroid (5 mg/kg) and 10 received mineral oil (5 mg/kg), twice a week. The animals were submitted to 42 sessions of swimming during nine weeks (from Monday to Friday), with gradual load increase through the swimming time. After sacrifice, the left soleum muscle was removed, immersed in n-hexane and conditioned in liquid nitrogen. Third middle cuts of this muscle were made in microtome cryostat (-20°C), and stained through HE technique and through NADH-TR histochemical method. The animals submitted to physical training and steroid (TA) or mineral oil (TO) presented muscle fibers with bigger diameter when compared to the ones from the control group (NTA and NTO). There was not significant difference between NTA and NTO and between TA and TO groups fiber diameters measures. In the TA and NTA groups, severe process of phagocytes, rounding and hyalinization of muscle fibers was observed. On the other hand, in the TA, TO and NTA groups, loss of the oxidative enzymatic activity was seen. The results suggest that swimming produces muscle hypertrophy similarly, not only in the group that received steroid, but also in the one that received mineral oil. However, the group that received steroid presented clear signs of greater muscle degeneration.

INTRODUCTION

Anabolic steroids are synthetic substances derived from testosterone, which have been calling researchers' and health professionals' attention, due to their high doses and irregular use by athletes. It is estimated that they have been used 10 to 100 times more than in the therapeutic application⁽¹⁾, with the purpose to improve physical performance and increase muscular mass⁽²⁻⁴⁾.

These substances increase the protein synthesis and the cellular growth with little androgenic effect⁽⁵⁾. However, its use has been associated with undesired side effects in the liver, cardiovascular

Keywords: Histology. Hypertrophy. Injury.

system, reproductive system and in the psychological state of the user⁽⁶⁻⁹⁾.

Whenever used in physical training, these substances produce mass increase as well as muscular strength in the locomotive system, besides reducing the recovery time after physical training⁽⁵⁾, characteristics desirable for high performance athletes. The efficiency of the strength gain and the muscular mass increase promoted by the use of steroids is still quite controversial. The combination of anabolic steroids and intense physical training in animals did not produce significant increase in the muscular mass when compared to animals submitted to physical training alone⁽¹⁰⁾. On the other hand, other studies reported not only increase of the muscular strength but also high protein and calories consumption⁽¹¹⁾; it is also suspected that anabolic steroids produce hypertrophy even in immobilized muscles as well⁽¹²⁾.

One of the experimental models which can be used in order to imitate the physical training effects on the musculoskeletal system in laboratory animals is swimming, an experimental model that produces the physical activity itself as well as strong emotional stimulus which is related to the kind of non-habitual activity, to the runaway impossibility and the death eminence⁽¹³⁻¹⁴⁾. In swimming, the load imposed to the locomotion system is due to the medium viscosity, which produces resistance to the movement, and to the animal's floatation properties⁽¹⁵⁾. Moreover, other additional factors may influence the responses to the exercise in water, such as the hydrostatic pressure and its specific heat⁽¹⁶⁻¹⁷⁾.

Considering these premises, the aim of this study was to verify the histological, histochemical and morphometrical alterations produced in the muscle fibers of the soleum muscle in groups of rats (sedentary and non-sedentary), associated or not to the use of anabolic steroid.

MATERIAL AND METHODS

22 Wistar (*Rattus norvegicus*) male rats, with age range between 100 and 180 days, kept in plastic collective cages (30 x 16 x 19 cm) with five animals at most, were used for the experiments. Before being used, these animals were kept at the bioterium for a week for adaptation, with average temperature of 22 ± 2°C and light/dark cycle of 12 hours, with the light cycle beginning at 7:00 h. The animals were fed with standard food (Pro-bioterium food – Primus Brand) and tap water ad libitum. All the adopted procedures were approved by the Ethics Committee in Research of the College of Science and Technology (Resolution nº 035/2005) of the State University of São Paulo – FCT/UNESP.

The animals were divided in four groups: two with no physical activity (called sedentary) and two submitted to swimming (called

1. Faculdade de Ciências e Tecnologia – FCT/UNESP – Presidente Prudente, SP, Departamento de Fisioterapia.

2. Faculdade de Ciências Médicas – FCM/UNICAMP – Campinas, SP, Departamento de Traumatologia e Ortopedia.

Received in 9/9/05. Final version received in 2/2/06. Approved in 15/5/06.

Correspondence to: José Carlos Silva Camargo Filho, Faculdade de Ciências e Tecnologia – FCT/UNESP, Câmpus de Presidente Prudente – Departamento de Fisioterapia, Rua Roberto Simonsen, 305, Cidade Universitária – 19060-900 – Presidente Prudente, SP. Caixa Postal: 957. Tel.: (18) 229-5388 – ramal 5365. E-mail: camargo@prudente.unesp.br

trained). Two groups (sedentary and trained) received intramuscular injection of mineral oil two times a week (5 mg/Kg – Nujol – Schering-Plough), while the other two (sedentary and trained) received 5 mg/Kg nandrolone decanoate (Deca-Durabolin® Organon) two times a week⁽¹⁸⁾.

The animals in the trained groups were submitted to 42 swimming sessions for nine weeks (from Monday to Friday) in a tank measuring 100 cm x 50 cm x 60 cm and with depth of 40 cm, containing water at 30°C in quantity enough to avoid that the animals could touch the bottom of the tank with the tip of their tails.

The training program consisted of daily swimming sessions, five times per week^(13,19), between 8:00 and 11:00 h, with overload produced by the increase of the training time. On the first week, the animals swam 10, 20, 30, 40 and 50 minutes per day. On the second week, they swam 50 minutes (Monday and Tuesday) and 60 minutes (Wednesday to Friday). On the third week, this time was of 60 minutes (Monday and Tuesday) and 70 minutes (Wednesday to Friday). This time was kept until the sixth week, when it was increased to 90 minutes/day (Wednesday to Friday), on the seventh and eighth weeks there was an increase to 120 minutes (Thursday and Friday), being the same way on the ninth week.

Immediately after sacrifice by intraperitoneal injection of sodium pentobarbital⁽²⁰⁾, a central fragment of 2,0 cm by 0,8 cm of the soleum muscle of the left pelvic limb was removed. It was carefully handled in order to keep the muscular fibers longitudinally placed in the bigger axis of the fragment. These fragments were frozen by immersion in n-Hexane, cooled at -70°C in liquid nitrogen through the Non-Steady Tissue Freezing Method⁽²¹⁾ and stored in a nitrogen container.

22 mounts were made from the 22 fragments, with cuts of eight µm of thickness, and stained with Hematoxylin and Eosin⁽²²⁾ in order to evaluate the following characteristics: shape, size, nucleus position, sarcoplasm coloring and hyperplasia presence, according to methodology already described in the literature⁽²³⁻²⁵⁾. The method of measuring the smallest diameter in samples of 120 fibers per animal was used in order to evaluate the degree of hypertrophy of the muscular fibers, through the system of computerized image analysis of the Image Pro-Plus software, following the criteria by Dubowitz *et al.*⁽²⁶⁾.

In order to demonstrate the Nicotinamide Adenine Dinucleotide Tetrazolium Reductase activity (NADH-TR), which indicates the presence of the oxidative activity, the amount of formazan in the sarcoplasm of the fibers was evaluated through the technique by Pearse modified by Dubowitz and Broke⁽²⁷⁾.

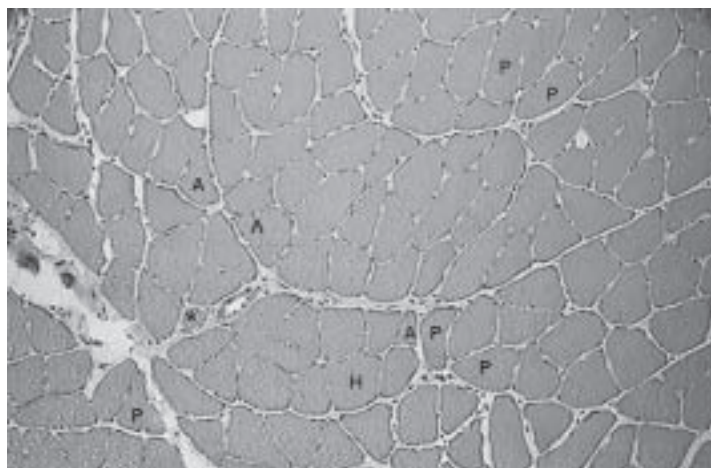


Figure 1 – Transversal section of the medium region of the soleum muscle of sedentary rat submitted to steroid administration. Polygonal fibers, peripheral nucleus and fascicular pattern were observed. Bigger extension of the morphological commitment: polymorphic fibers (P), small atrophic angular fibers (A) next to hypertrophic ones (H), fibers in splitting process (^) and phagocytosis process (*). HE 200X.

The indices of smallest diameter of the muscular fibers were compared through analysis of bifactor variance, with training status (sedentary and trained) and drug (anabolic steroid and mineral oil) as factors, followed by the T-LSD test for multiple comparisons of averages. P indices lower than 0,05 were indication of statistical significance.

RESULTS

In the mounts of the animals of the sedentary group that received mineral oil (NTO) the presence of muscular fibers with polygonal outlines, nucleus in peripheral position and normal fascicular pattern were observed. In the mounts of the animals of the sedentary group that received steroid (NTA) the presence of polymorphic, hyalinized and fagocytosed fibers was verified (figure 1). In the mounts of the animals of the trained group that received mineral oil (TO) regions with normal aspect and areas with muscular fibers in final phase of phagocytosis and angle fibers prone to rounding were observed (figures 2 and 3). In the mounts of the trained group that received steroid (TA) increase of the hypertrophic fibers, with central nucleus and of rounded fibers, even experiencing splitting was observed. It was also observed the presence of atrophic angle fibers in phagocytosis, besides hypertrophic and hyalinized fibers (figures 4 and 5).

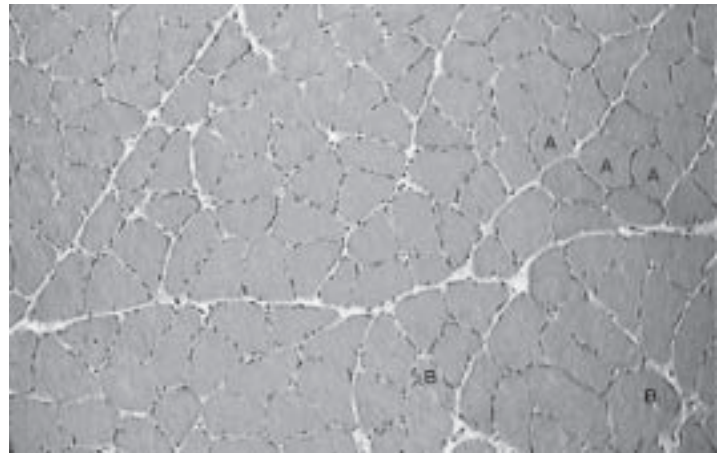


Figure 2 – Transversal section of the medium region of the soleum muscle of trained rat submitted to mineral oil administration. Fibers with normal aspect and areas with angle fibers with polymorphism (B), with tendency to rounding (A) and increased endomysium are observed. HE 200X.

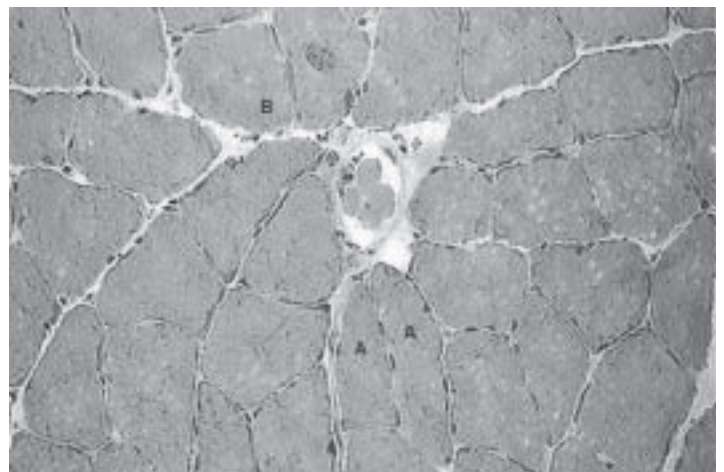


Figure 3 – Transversal section of the medium region of the soleum muscle of trained rat submitted to mineral oil administration. Phagocytosis process in initial phase (B) and presence of polymorphic fibers are observed (A). HE 500X.

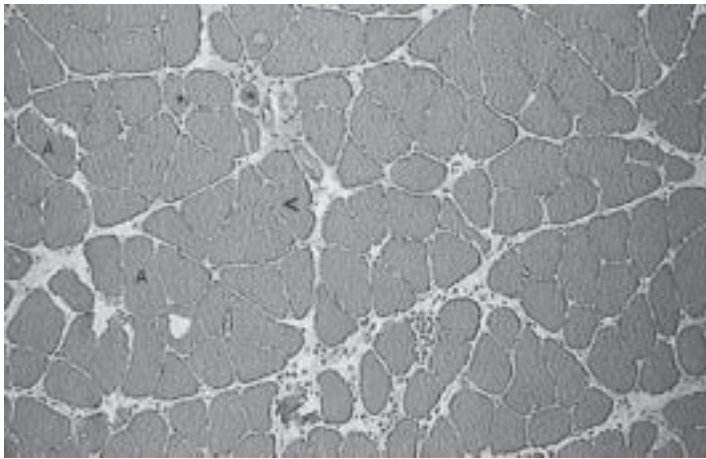


Figure 4 – Transversal section of the medium region of the soleum muscle of trained rat submitted to steroid administration. Spacing of muscular fibers, inflammatory reaction, increase of the nucleus number, phagocytosis with muscular fibers loss (*), splitting (<) and fibers polymorphism are observed (A). HE 200X.

In the evaluation of the oxidative activity of the NTO group, it was observed that the majority of the fibers presented normal pattern for the reaction. In the animals of the other groups (NTA, TO and TA), increase of the enzymatic activity was observed, being more intense in the TA group, characterized by the presence of grains stained in blue (formazan), which set in the places where the mitochondria were, usually in the cells periphery (figure 6).

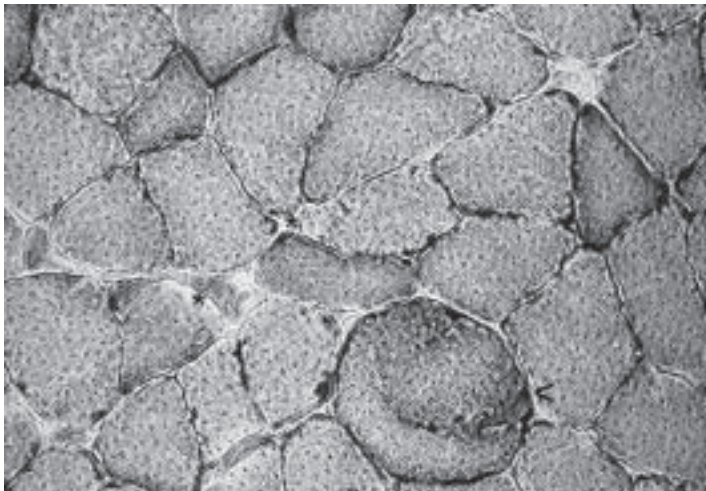


Figure 6 – Transversal section of the medium region of the soleum muscle of trained rat submitted to steroid administration. Irregular distribution of the reaction product, fibers with enzymatic activity loss (*) and presence of amorphous aggregation groups in the fibers interior (<) are observed. NADH-TR – 500X.

The analyses of the measure of the muscular fibers diameter showed significant differences for the training status factor ($F = 14,23$; $p = 0,0014$), while no differences between the drug factor ($F = 0,01$; $p = 0,9391$) and the training status x drug interaction ($F = 0,57$; $p = 0,4606$) were observed. The T-LSD test showed that the measure of the smallest diameter of the muscular fibers of the animals in the TA and TO groups was significantly different when compared to their respective controls (table 1).

In all studied groups the diameter of the muscular fibers varied from 30 to 50 mm. In the non-trained groups this range varied from 30 to 40 mm, while in the trained ones (with or without the use of steroids) varied from 40 to 50 mm (figure 7).

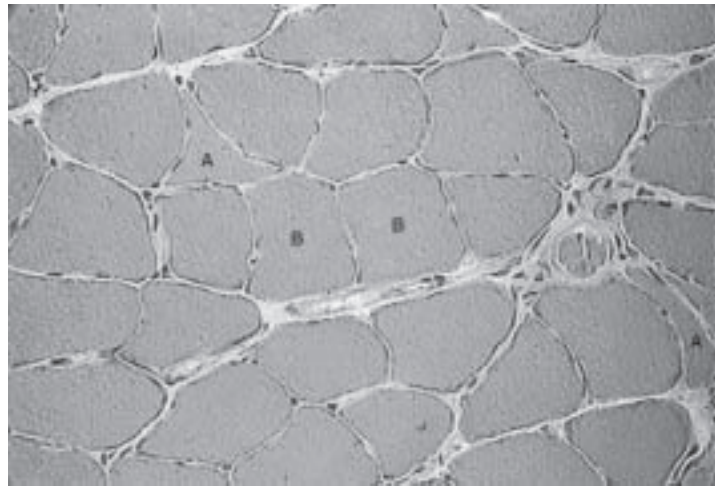


Figure 5 – Transversal section of the medium region of the soleum muscle of trained rat submitted to steroid administration. Atrophic angle fibers (A) and hypertrophic ones are observed (B). HE 500X.

TABLE 1

Average values, accompanied by the respective standard deviations, measured in micrometers of the smallest diameter of the fibers of the soleum muscle of the animals of the experimental and control groups

Animal	Average value	Standard deviation
NTA	38.98	2.08
NTO	38.40	1.22
TA	41.94*	2.33
TO	42.83*	3.34

NTA = non-trained anabolic, NTO = non-trained oil; TA = trained anabolic, TO = trained oil. *Average values statistically significant comparing to their respective controls ($p < 0,05$; ANOVA Bifactor + T-LSD test).

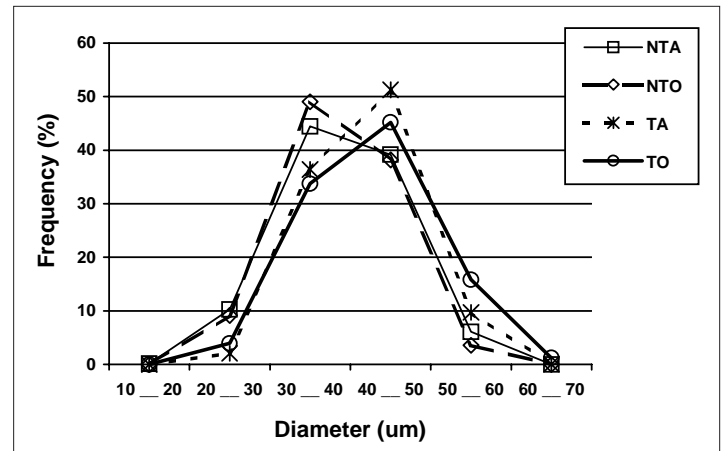


Figure 7 – Percentage distribution of the muscular fibers quantity in the several fibers diameters between the experimental and control groups

DISCUSSION

The histological findings showed that the steroid administration produced muscular lesion in the sedentary group, while the mineral oil administration did not cause lesion in this group. In the trained groups, muscular lesions were observed in both groups, being more evident in the animals submitted to the steroid administration. These lesions were mainly characterized by the presence of rounded cells with splitting and phagocytosed cells.

On the other hand, the analysis of the mounts prepared by the enzymatic reaction (NADH-TR) demonstrated increase of the cellular metabolic activity not only in the trained groups, but also in the sedentary group in which the steroid had been administered,

showing hence, that this substance may accelerate the cellular metabolism.

In the animals of the sedentary group with anabolic steroid administration, severe loss of NADH-TR activity and atrophic fibers with weak reactive activity were observed, which is related to lower oxidation in the NADH₂ system. Such low fiber oxidative activity may be related to muscular lesion. Formazan amorphous aggregation groups were also observed in central position in relation to the fiber, showing the dislocation of mitochondria.

In both trained groups loss of enzymatic activity and irregular distribution of the reaction product were also observed. Moreover, in the trained animals with the steroid there was presence of amorphous aggregation groups and angle and atrophic fibers with more intense reaction.

Intense physical exercises produce lesions in the skeletal muscles, accompanied by pain, edema and fatigue, especially during activities in which exocentric forces and high peaks of contractions are demanded⁽²⁸⁻³¹⁾. In the present study, some of these characteristics seem to have appeared, especially in the more extensive exercise when the animals demonstrated tendency to touch the bottom of the tank with the pelvic limb in order to push the body up.

Therefore, the animals of the present research showed mechanical stress situation which is one of the main factors that can cause muscular damage during exercise⁽³⁰⁾.

Concerning the morphometry of the fibers, the results showed that significant differences did not occur in the diameters of the soleum muscle of the sedentary animals submitted to steroid administration when compared to the sedentary animals that received mineral oil, which differs from the fact observed in the gastrocnemius muscle of sedentary rats where the anabolic steroids administration, with dose eight times of the therapeutic ones, produced hypertrophy of Type IIb fibers of this muscle⁽³²⁾.

In this study the smallest diameter of the muscular fibers was measured in mounts stained with HE, therefore, the diameter of the several types of fibers was not measured. Once the soleum muscle presents predominance of type I fiber⁽³³⁾, which has oxidative metabolism and smaller diameter, the hypertrophy could occur in higher degree in the type II fibers, which seems to explain the non-significant averages increase of the diameters of the evaluated fibers.

In the animals that were submitted to physical training with and without anabolic steroid administration, significant increase of the muscular fibers diameter was observed comparing to the animals that were not submitted to swimming, without significant differences between them. Such evidence demonstrates that this increase was induced by the physical training and not by the steroid administration.

The increase of muscular strength and, consequently, hypertrophy of the fibers by the use of steroids, occurs when its administration is associated to an intense physical training and a hypercaloric and hyper proteinic diet⁽¹¹⁾. Such fact seems to have been neglected in this work, since the applied diet has a balanced chemical composition (Probioterium Food – Primus brand) and the used exercise was not of high intensity.

Another factor that may be also related to the presented results in this article is the dose of the drug used, since the muscular fibers present different reactions depending on the applied dose. As an example, the daily administration of nandrolone decanoate, for five weeks, in two groups of treated rats with low doses (1,5 mg/Kg) and high doses (7,5 mg/Kg), produced increase of the type I fibers only in the animals treated with low doses and hypertrophy of the type IIb fibers in the animals treated with high doses⁽³⁴⁾. In our experiments, a 5 mg/Kg dose was used, which is close to the dose used by the author in order to produce hypertrophy of the type IIb fibers⁽³⁴⁾.

Associated to these factors, the anabolic steroid action seems to be selective, inducing bigger alteration in the diameter of certain types of muscular fibers, as reported by Furumura⁽³⁵⁾ and Callis⁽³²⁾, who showed that the use of steroid (Stanozoeol) associated to the swimming physical training caused hypertrophy of the Type II muscular fibers, while the Type I fibers presented only moderate hypertrophy.

Considering these findings, the increase in the diameter may have happened more intensely in the type II fibers. However, in the soleum muscle there is more predominance of type I fibers⁽³³⁾, and because of that, the hypertrophy induced by the drug would not be so evident in order to produce alteration in the diameter average of the muscular fibers of this muscle.

Another factor that may have contributed to the small anabolic steroid action in the fibers of the soleum muscle in the trained animals, may be related to the predominance of steroids receptors in specific regions of the body, and the existing difference between the animals species⁽³⁶⁻³⁷⁾.

In this article, the load increase during the training was produced by the increase of the training time and not by external overload, as used in other articles⁽³⁸⁻³⁹⁾. We believe that the increase of external load during the training could increment the changes observed, due to bigger overload that these animals would be submitted to. Increase of muscular lesions during exercise is dependent on the training duration and intensity⁽⁴⁰⁾.

CONCLUSION

The presented results suggest that the morphological alterations characteristic of lesion processes and loss of enzymatic activity of the fibers in the muscular tissue, occurred more intensely in the animals of the groups in which the drug was administered, when compared to their respective controls. Concerning the measure of the diameter of the soleum muscular fibers, both trained groups presented diameters equivalent and bigger than the ones observed in the sedentary animals, suggesting that the increase of diameter of the muscular fibers in these animals occurred due to physical exercise and not due to the anabolic steroid administration.

All the authors declared there is not any potential conflict of interests regarding this article.

REFERENCES

1. Pope HG Jr, Katz DL. Affective and psychotic syndromes associated with use of anabolic steroids. *Am J Psychiatry* 1988;145:487-90.
2. Hall RCW, Hall RCW. Abuse of supraphysiologic doses of anabolic steroids. *South Med J* 2005;98(5):550-5.
3. Moores J. Anabolic steroids. *Best Pract Res Clin Endocrinol Metab* 2000;14:55-69.
4. Lichtenbelt VM, Wouter D, Hartgens F, Vollaard NBJ, Ebbing S, Kuipers H. Body-builders' body composition: effect of nandrolone decanoate. *Med Sci Sports Exerc* 2004;36(3):484-9.
5. Wagner JC. Abuse of drugs used to enhance athletic performance. *Am J Hospital Pharmacy* 1989;46:2059-67.
6. Yesalis CE, Bahrke MS. Anabolic-androgenic steroids. *Sports Med* 1995;19:326-40.
7. Payne JR, Kotwinski PJ, Montgomery HE. Cardiac effects of anabolic steroids. *Heart* 2004;90:473-5.
8. McGinnis MY. Anabolic androgenic steroids and aggression: studies using animal models. *Ann N Y Acad Sci* 2004;1036:399-415.
9. Gruber AJ, Pope Jr HG. Psychiatric and medical effects of anabolic-androgenic steroid use in women. *Psychother Psychosom* 2000;69:19-26.
10. American College of Sports Medicine. The use anabolic-androgenic steroids in sports. *Med Sci Sports Exerc* 1987;19(5):534-9.
11. Haupt HA, Rovere GD. Anabolic steroids: a review of the literature. *Am J Sports Med* 1984;12:469-84.

12. Taylor DC, Brooks DE, Ryan JB. Anabolic-androgenic steroid administration causes hypertrophy of immobilized and nonimmobilized skeletal muscle in a sedentary rabbit model. *Am J Sports Med* 1999;27:718-26.
13. Östman-Smith I. Adaptative changes in the sympathetic nervous system and some effectors organs of the rat following long-term exercise or cold acclimation and the role of cardiac sympathetic nerves in the genesis of compensatory cardiac hypertrophy. *Acta Physiol Scand* 1979;111:1-118.
14. Garcia-Marquez C, Armario A. Chronic stress depresses exploratory activity and behavioral performance in the forced swimming test without altering ACTH response to a novel acute stressor. *Physiol Behav* 1987;40:33-8.
15. Skinner A, Thompson A. Duffield: exercícios na água. 3ª ed. Manole: São Paulo, 1988.
16. Edlich RF, Towler MA, Goitz RJ, Wilder RP, Buschbacher LP, Morgan RF, et al. Bioengineering principles of hydrotherapy. *J Burn Care Rehabil* 1987;8(6):580-4.
17. Campion MR. Adult hydrotherapy: a practical approach. Oxford: Heinemann Medical Books, 1990.
18. Norton GR, Trifunovic B, Woodiwiss AJ. Attenuated beta-adrenoceptor-mediated cardiac contractile responses following androgenic steroid administration to sedentary rats. *Eur J Appl Physiol* 2000;81:310-6.
19. Linard M. Estudo da sensibilidade aos efeitos cronotrópico e inotrópico das catecolaminas em átrios isolados de ratos submetidos a treinamento físico [Dissertação]. Instituto de Biologia: Universidade Estadual de Campinas, 1992.
20. Marshall S, Milligan A, Yates R. Experimental techniques and anesthesia in the rat and mouse. *Anzccart Facts Sheet Anzccart News* 1994;7:4.
21. Dal Pai V. Histoenzimologia: teoria e prática. Instituto de Biociências – Unesp, Botucatu, 1995.
22. McManus JFA, Mowry RW. Staining methods: histologic and histochemical medical division. New York: Harper & Brother, 1960;283-310.
23. Fridén J, Liber RL. Structural and mechanical basis of exercise-induced muscle injury. *Med Sci Sports Exerc* 1992;24(5):521-30.
24. Antonio J, Gonyea WJ. Skeletal muscle fiber hyperplasia. *Med Sci Sports Exerc* 1993;25(12):1333-45.
25. Sartori JR, Gonzales E, Macari M, Dal Pai V, Oliveira HN. Tipos de fibras no músculo flexor longo do hálux de frangos de corte submetidos ao estresse pelo calor e frio e alimentados em "pair-feeding". *Rev Brasil Zootecnia* 2003;32(4): 918-25.
26. Dubowitz V, Brooke MH, Neville H. Muscle biopsy: a modern approach. London: Saunders Co. Ltd., 1972;471.
27. Dubowitz V, Brooke MH. Muscle biopsy: a practical approach. 2nd ed. London: Bailliere Tindall, 1985.
28. Clarkson PM, Nosaka K, Braun B. Muscle function after exercise-induced muscle damage and rapid adaptation. *Med Sci Sports Exerc* 1992;24(5):512-20.
29. Jones DA, Newham DJ, Round JM, Tolfree SE. Experimental human muscle damage: morphological changes in relation to other indices of damage. *J Physiol* 1986;375:435-48.
30. Kuipers, H. Exercise-induced muscle damage. *Int J Sports Med* 1994;15:132-5.
31. Armstrong RB, Warren GL, Warren JA. Mechanisms of exercise-induced muscle fibre injury. *Sports Med* 1991;12:184-207.
32. Calis JFF. Medidas da área de fibras musculares do músculo gastrocnêmio de ratos submetidos ao exercício de natação e administração de esteróide anabólico para quantificar a hipertrofia em fibras tipo I e tipo II [Monografia]. Instituto de Biociências: Universidade Estadual Paulista, 1995.
33. Guyton AC. Fisiologia humana. 6ª ed. Rio de Janeiro: Guanabara Koogan, 1988.
34. Bisschop A, Gayan-Ramirez G, Rollier H, Dekhuijzen PN, Dom R, De Bock V, et al. Effects of nandrolone decanoate on respiratory and peripheral muscles in male and female rats. *J Appl Physiol* 1997;82(4):1112-8.
35. Furumura MT. Quantificação de hipertrofia muscular em fibras tipo I e II do músculo gastrocnêmio de ratos submetidos a um exercício físico de natação e a um esteróide anabólico [Monografia]. Instituto de Biociências: Universidade Estadual Paulista, 1994.
36. Mooradian AD, Morley JE, Korenman SG. Biological actions of androgens. *Endocr Rev* 1987;8:1-28.
37. Celotti F, Cesi PN. Anabolic steroids: a review of their effects on the muscles, of their possible mechanisms of action and of their use in athletics. *J Steroid Biochem Mol Biol* 1992;43:469-77.
38. Saad PCB, Guimarães A, Dal Pai V, Kroll LB. Análise histológica e histoquímica das fibras dos músculos reto do abdome e intercostal paraesternal de ratos submetidos ao exercício de natação. *Rev Bras Med Esporte* 2002;8(4):144-50.
39. Medeiros A, Oliveira EM, Gianolla R, Casarini DE, Negrão CE, Brum PC. Swimming training increases cardiac vagal activity and induces hypertrophy in rats. *Braz J Med Biol Res* 2004;37(12):1909-17.
40. Dal Pai V. Esporte e lesão muscular. *Rev Brasil Neurol* 1994;30(2):45-8.