

Original Article

Antibiotic resistance pattern and pathological features of avian pathogenic *Escherichia coli* O78:K80 in chickens

Padrão de resistência a antibióticos e características patológicas de *Escherichia coli* patogênica aviária O78:K80 em galinhas

S. Usman^{a*} , A. Anjum^b , M. Usman^c , M. S. Imran^a , M. Ali^d , M. Moustafa^{e,f} , M. S. Rehman^g , T. Hussain^h , F. Sarwarⁱ , A. Azadⁱ , I. Hussain^j , J. Naseer^h , U. Tiwana^k  and S. Hafeez^l 

^aUniversity of Veterinary and Animal Sciences, Faculty of Veterinary and Animal Sciences, Department of Pathology, Lahore, Pakistan

^bMuhammad Nawaz Shareef University of Agriculture Multan, Faculty of Veterinary and Animal Sciences, Department of Pathobiology, Multan, Pakistan

^cUniversity of Veterinary and Animal Sciences, Faculty of Veterinary and Animal Sciences, Department of Veterinary Medicine, Lahore, Pakistan

^dBZU Bahadur sub campus Layyah, College of Veterinary Sciences, Layyah, Pakistan

^eKing Khalid University, Faculty of Science, Department of Biology, Abha, Saudi Arabia

^fSouth Valley University, Faculty of Science, Department of Botany and Microbiology, Qena, Egypt

^gPoultry Research Institute, Livestock and Dairy Development Department, Rawalpindi, Pakistan

^hThe Islamia University of Bahawalpur, Department of Forestry Range and Wildlife Management, Bahawalpur, Pakistan

ⁱPoultry Research Institute, Rawalpindi, Pakistan

^jBahauddin Zakariya University, Department of Pathobiology, Multan, Pakistan

^kNational Agricultural Research Centre, Range Land Research Institute, Islamabad, Pakistan

^lUniversity of Agriculture Faisalabad, Department of Forestry and Range Management, Faisalabad, Pakistan

Abstract

Avian pathogenic *Escherichia coli* (APEC) induces colibacillosis, an acute and systemic disease, resulting in substantial economic losses in the poultry sector. This study aimed to investigate the antibiotic resistance pattern associated with frequent virulence gene distribution in APEC O78:K80 that may cause pathological alterations in chickens. The antibiogram profile showed high resistance to erythromycin, chloramphenicol, tetracycline, ampicillin, and co-trimoxazole, followed by intermediate resistance to ciprofloxacin, levofloxacin, enrofloxacin, norfloxacin, nitrofurantoin, and doxycycline hydrochloride, and sensitive to amikacin, streptomycin, gentamicin, and colistin. Virulence gene distribution identifies eight (*irp-2*, *iutA*, *ompT*, *iss*, *iucD*, *astA*, *hlyF*, *iroN*) genes through a conventional polymerase chain reaction. APEC O78:K80 caused significantly high liver enzyme concentrations, serum interleukin-6 and tumor necrosis factor-alpha levels in experimental birds. Also, infected birds have hypoproteinemia, hypoalbuminemia, and hyperglobulinemia. Necropsy examination revealed fibrinous perihepatitis and pericarditis, congested lungs, intestinal ecchymotic hemorrhages and necrotizing granulomatosis of the spleen. Histopathological examination depicted hepatocellular degeneration, myocardial necrosis, interstitial nephritis, intestinal hemorrhages and lymphopenia in the spleen. This study is the first evidence to assess the antibiotic resistance profile linked with virulence genes and clinicopathological potential of APEC O78:K80 in chickens in Pakistan, which could be a useful and rapid approach to prevent and control the disease by developing the control strategies.

Keywords: *Escherichia coli*, antibiotic resistance, virulence genes, pathology, chickens.

Resumo

A *Escherichia coli* patogênica aviária (APEC) induz a colibacilose, uma doença aguda e sistêmica, resultando em perdas econômicas substanciais no setor avícola. Este estudo teve como objetivo investigar o padrão de resistência a antibióticos associado à frequente distribuição de genes de virulência em APEC O78:K80 que podem causar alterações patológicas em galinhas. O perfil do antibiograma mostrou alta resistência à eritromicina, cloranfenicol, tetraciclina, ampicilina e cotrimoxazol; resistência intermediária à ciprofloxacina, levofloxacina, enrofloxacina, norfloxacina, nitrofurantoína e cloridrato de doxiciclina; e sensível à amicacina, estreptomicina, gentamicina e colistina. A distribuição de genes de virulência identificou oito genes (*irp-2*, *iutA*, *ompT*, *iss*, *iucD*, *astA*, *hlyF* e *iroN*) por meio de uma reação em cadeia da polimerase convencional. A APEC O78:K80 causou concentrações significativamente altas de enzimas hepáticas, níveis séricos de interleucina-6 e fator de necrose tumoral alfa em aves experimentais. Além disso, aves infectadas apresentaram hipoproteinemia, hipoalbuminemia e hiperglobulinemia. O exame de

*e-mail: sabausman993@gmail.com; ahsan.anjum@mnsuam.edu.pk

Received: October 11, 2021 – Accepted: May 6, 2022



This is an Open Access article distributed under the terms of the Creative Commons Attribution License, which permits unrestricted use, distribution, and reproduction in any medium, provided the original work is properly cited.

necropsia revelou peri-hepatite e pericardite fibrinosa, pulmões congestos, hemorragias equimóticas do intestino e granulomatose necrosante do baço. O exame histopatológico mostrou degeneração hepatocelular, necrose miocárdica, nefrite intersticial, hemorragias intestinais e linfopenia no baço. Este estudo é a primeira evidência para avaliar o perfil de resistência a antibióticos associado a genes de virulência e potencial clínico-patológico de APEC O78:K80 em galinhas no Paquistão, o que pode ser uma abordagem útil e rápida para prevenir e controlar a doença por meio do desenvolvimento de estratégias de controle.

Palavras-chave: *Escherichia coli*, resistência a antibióticos, genes de virulência, patologia, galinhas.

1. Introduction

Avian pathogenic *Escherichia coli* (APEC) causes colibacillosis in chickens. The organism can invade multiple organs resulting in systemic diseases such as coligranuloma, colisepticemia, omphalitis, synovitis, swollen head syndrome, airsacculitis, and cellulitis (Giovannardi et al., 2005). Colibacillosis causes considerable economic losses to the poultry industry due to high morbidity and mortality (Koutsianos et al., 2021). *Escherichia coli* (*E. coli*) is considered the natural inhabitant of avian gut microflora. Several virulence factors, including adhesins, aerobactin, yersiniabactin, hemolysins, outer membrane protein A, lipopolysaccharide, K1-capsule, and heat-stable toxin, have been reported in the propagation of various extraintestinal diseases in avian species (Parreira and Gyles, 2003; Ewers et al., 2004). Unlike other intestinal *E. coli* serotypes, APEC can be diagnosed by typical clinical signs, gross pathology and microscopic lesions; however, the general mechanism of APEC pathogenesis needs further explanations (Ewers et al., 2003). Although the term APEC is frequently used for *E. coli* isolates obtained from avian colibacillosis; however, accurate and comprehensive classification of serogroups and specific virulence genes is still required (Sarowska et al., 2019). Even though several serotypes have been isolated from chicken samples, the most common are O1:K1, O2:K1, and O78:K80 (Dziva and Stevens, 2008). However, as the number of serogroups increases, isolates within the same O group can also become genetically heterogeneous; in contrast, closely related strains can represent different serogroups (Ge et al., 2014).

Antibiotic resistance is a severe threat to worldwide public health, with substantial repercussions for animal health and food safety (Aarestrup, 2004). Antibiotics are excessively used in the poultry sector as growth promoters and for therapeutic purposes in many countries, including Pakistan (Azam et al., 2019). On the other hand, the use of antimicrobials in food-producing animals has some negative consequences, such as changes in intestinal microflora, antibiotic residues in meat and impact on public health interventions (Miles et al., 2006). Multiple antibiotic-resistant bacteria have been a challenge in treating zoonotic infections, and their transmission from animal to human has put the health sector at risk (Spellberg, 2014).

Furthermore, the emergence of drug-resistant strains due to irrational chemotherapeutic treatment may substantially impact the clinicopathological manifestations of colibacillosis (Alonso et al., 2017). The virulence features of APEC in poultry have previously been reported in Nepal, Algeria, Brazil, United Kingdom, and Korea (Jeong et al., 2012; Kemmett et al., 2014; Barbieri et al., 2015; Mohamed et al., 2018; Subedi et al., 2018). However, there is a paucity of literature addressing APEC pathogenicity,

heterogeneity of serogroups, and virulence gene distribution in Pakistan (Hussain et al., 2017; Azam et al., 2020). Therefore, this study aimed (1) to determine the antibiotic resistance pattern of APEC O78:K80 (2) to evaluate the virulence gene distribution and (3) to assess the pathological potential of APEC O78:K80 by examining the serum biochemical, immunological biomarkers, and histopathological alterations in colisepticemic chickens.

2. Materials and Methods

2.1. Ethical approval

The work was approved by the ethical review committee for the use of laboratory animals (ERCULA) of the University of Veterinary and Animal Sciences, Lahore, Pakistan (Permit Number: ORIC/DR-992).

2.2. Isolation and identification of *Escherichia coli*

A septicemic dead bird was received at Postmortem Block, Department of Pathology, University of Veterinary and Animal Sciences, Lahore, Pakistan. Tissue samples (liver and heart) were collected, triturated, and centrifuged at 6,000 g for 10 min. The obtained supernatant was cultured on eosin methylene blue (EMB) agar and incubated (37°C, 24 h). The green metallic sheen colonies of *E. coli* (Figure 1) were subjected to biochemical and pathogenicity tests (Ali et al., 2019). The plates were incubated for another 24 h before declaring negative. A single colony was enriched in lysogeny broth (LB) media for further processing.

2.3. DNA extraction and amplification of universal stress protein A gene

The extracted genome from broth culture was subjected to a conventional polymerase chain reaction (PCR), employing the previously reported primer sequences of universal stress protein A (*uspA*) gene; forward (5'- CCGATACGCTGCCAATCAGT-3') and reverse (5'- ACGCAGACCGTAGGCCAGAT-3') (Chen and Griffiths, 1998). A reaction mixture of 25 µL containing 2 µL template DNA, 1.25 µL (10 pmol each primer), 12.5 µL of 2X Master Mix (Thermo Scientific, United States) and 8 µL of nuclease-free water was prepared. The PCR reaction was conducted in Veriti™ 96-Well Thermal Cycler (Applied Biosystems™, USA) with the following conditions: initial denaturation (95°C, 5 min), and 30 cycles of each [denaturation (94°C, 30 s), annealing (56.5°C, 30 s) and extension (72°C, 90 s)] a final extension (72°C, 7 min). The PCR product was separated on agarose gel (1.5% w/v) stained with 0.5 µg/mL ethidium bromide, run in gel electrophoresis (110V, 230mA, 30 min), and visualized in a gel documentation system. The

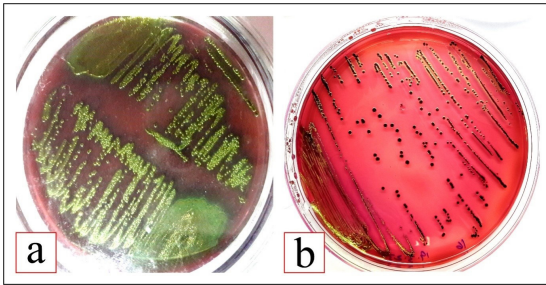


Figure 1. *Escherichia coli* colonies with green metallic sheen (a, b).

PCR product was submitted for DNA sequencing to Comate Bioscience Co., Ltd., China. The obtained sequence was trimmed and aligned using BioEdit Sequence Alignment Editor (version 7.2.5.0) Software. The assembled sequence was compared with the available sequences of *E. coli* in the NCBI GenBank Database. After processing with MAST serotyping kit (Ebrahimi-Nik et al., 2018), the obtained isolate was detected as *E. coli* O78:K80.

2.4. Antibiotic susceptibility test

The antibiotic susceptibility pattern of *E. coli* O78:K80 was determined following the modified Kirby-Bauer disk diffusion method and categorized as sensitive, intermediate, or resistant as recommended by the Clinical and Laboratory Standards Institute (CLSI) (Subedi et al., 2018). The isolate was tested against 20 antibiotics; amikacin (AK), amoxicillin (AMC), ampicillin (AMP), cefazolin (KZ), cefepime (FEP), ceftazidime (CAZ), chloramphenicol (C), ciprofloxacin (CIP), colistin (CL), co-trimoxazole (COT), doxycycline hydrochloride (DO), enrofloxacin (ENR), gentamicin (GEN), kanamycin (K), levofloxacin (LE), meropenem (MEM), nitrofurantoin (NIT) and streptomycin (S). These antibiotics are frequently employed in poultry feeds and in treating colibacillosis and other avian disorders (Subedi et al., 2018; Levy et al., 2020).

2.5. Virulence genes detection

The isolated *E. coli* genome was subjected to conventional PCR to detect the 11 virulence genes (*iutA*, *iss*, *papC*, *iucD*, *tsh*, *irp-2*, *ompT*, *hlyF*, *iroN*, *cva/cvi*, *astA*) associated with colibacillosis. The virulence genes were amplified using previously reported primer sets (Table 1) (Subedi et al., 2018). A reaction mixture of 25 μ L containing 2 μ L template DNA, 1.25 μ L (10 pmol each primer), 12.5 μ L of 2X Master Mix (Thermo Scientific, United States) and 8 μ L of nuclease-free water was prepared. The PCR conditions were set to; initial denaturation (95°C, 5 min) and 35 cycles of each [denaturation (94°C, 45 s), annealing (60°C, 1 min), extension (72°C, 90 s), followed by a final extension (72°C, 7 min). Following gel electrophoresis, amplified PCR products were photographed through a gel documentation system to determine positive virulence genes.

2.6. Experimental design

Broiler chicks (N=70) were randomly divided into two groups (n=35/group). On day 14, the positive control (PC)

Table 1. Primer sets for detection of target virulence genes from avian pathogenic *Escherichia coli* (APEC) isolate (Subedi et al., 2018).

x	Primer Sequence (5'-3')	Amplicon Size (bp)
<i>iutA</i>	F: GGCTGGACATCATGGGAAGCTGG	302
	R: CGTCGGGAACGGGTAGAATCG	
<i>iss</i>	F: CAGCAACCCGAACCACTTGATG	323
	R: AGCATTGCCAGAGCGGCAGAA	
<i>papC</i>	F: TGATATCACGCAGTCACTAGC	501
	R: CCGCCATATTACATAA	
<i>iucD</i>	F: ACAAAAAGTTCTATCGCTTCC	714
	R: CCTGATCCAGATGATGCTC	
<i>tsh</i>	F: ACTATTCTCTGCAGGAAGTC	824
	R: CTTCGGATGTTCTGAACGT	
<i>irp-2</i>	F: AAGGATTCGCTGTACCGGAC	413
	R: AACTCCTGATACAGGTGGC	
<i>ompT</i>	F: TCATCCGGGAAGCCTCCCTCACTACTAT	496
	R: TAGCGTTTGCTGCACTGGCTTCTGATAC	
<i>hlyF</i>	F: GGCCACAGTCGTTTAGGGTGCTTACC	450
	R: GGCGGTTTAGGCATTCCGATACTCAG	
<i>iroN</i>	F: AATCCGGCAAAGAGACGAACCGCCT	553
	R: GTTCGGGCAACCCCTGCTTTGACTTT	
<i>cva/cvi</i>	F: TGGTAGAATGTGCCAGAGCAAG	1181
	R: GAGCTGTTGTAGCGAAGCC	
<i>astA</i>	F: TGCCATCAACACAGTATATCC	116
	R: TCAGGTCCGGAGTGACGGC	

group was infected with 0.5 mL of 10^8 CFU/mL of *E. coli* O78:K80 through the intranasal route (Zhang et al., 2016). The negative control group (NC) remained un-inoculated.

2.7. Serum biochemistry profile

At 3, 7, and 14-days post-infection (DPI), blood samples (n=10/group) were collected to harvest the serum. The liver enzymes [alanine aminotransferase (ALT), aspartate aminotransferase (AST), alkaline phosphatase (ALP)], total protein (TP), albumin, and globulin concentrations, were analyzed using the specific kits (Roche Diagnostica, Switzerland) in clinical chemistry analyzer (Labcompare, USA) (Sultan et al., 2017; Jayaweera et al., 2018).

2.8. Serum cytokines

The serum interleukin-6 (IL-6) and tumor necrosis factor- α (TNF- α) concentrations were determined through the chicken IL-6 (Catalog Number: MBS268769) and TNF- α (Catalog Number: MBS260419) ELISA kits (MyBioSource, USA) using PR 4100 absorbance microplate reader (Bio-Rad Laboratories, United States) (Sultan et al., 2017).

2.9. Clinical symptoms, necropsy findings, and histopathological examination

Clinical signs were recorded along the course of the experiment. At 3, 7, and 14 DPI, birds (n=10/group) were slaughtered to observe the gross pathological changes. The liver, heart, lungs, intestine, kidney and spleen tissue samples were collected for microscopic examinations. The tissue samples were preserved in 10% neutral buffered formalin (NBF), dehydrated in descending order of alcohol, paraffin-embedded, sliced with a microtome (4 µm), and stained with hematoxylin and eosin (H & E) dye to observe the histopathological alterations (Sharaf et al., 2021).

2.10. Statistical analysis

A paired sample t-test was applied for data evaluation. The statistical analysis was performed on IBM SPSS version 25 Software. The confidence interval for quantitative data was considered at 95% to indicate a statistically significant difference (P<0.05).

3. Results and Discussion

3.1. Antimicrobial sensitivity patterns

The isolated *E. coli* showed high resistance to erythromycin, chloramphenicol, tetracycline, ampicillin, and co-trimoxazole, with intermediate resistance to ciprofloxacin, levofloxacin, enrofloxacin, norfloxacin, nitrofurantoin, and doxycycline hydrochloride, and sensitive to amikacin, streptomycin, gentamicin, and colistin. These antibiotic resistance patterns against *E. coli* are similar to those found in previous investigations (Bakhshi et al., 2017; Matin et al., 2017). Previous studies revealed a substantial increase in veterinary antibiotic import in Pakistan due to inappropriate use in the poultry sector (Rahman and Mohsin, 2019; Rafique et al., 2020; Amir et al., 2021). Also,

irrational use of antibiotics induces selection pressure on microorganisms, resulting in new multidrug-resistant pathogens. The antibiotic resistance trend determined in this study depicts a potentially dangerous condition of antibiotic-resistant *E. coli* strains in commercial poultry in Pakistan.

3.2. Virulence genes detection

In this study, *E. coli* isolate contained eight (*irp-2*, *iutA*, *ompT*, *iss*, *iucD*, *astA*, *hlyF* and *iroN*) virulence genes (Figure 2), which are inconsistent with the findings of Kwon et al. (2008) who reported *Iss*, *tsh*, *vat*, *iucD*, *irp-2*, *astA*, *cva/cvi* and *papC* virulence genes among 18 APEC strains. Similarly, Carli et al. (2015) suggested *hlyF*, *iroN*, *ompT*, *iss* and *iutA* as frequently found virulence genes in APEC strains. Concerning pathogenicity, *astA*, *iucD*, and *iutA* are believed to be the most important virulence genes due to their high-frequency rate (80-90%) (Subedi et al., 2018). The genetic criteria for pathogenicity suggest that an isolate containing at least five virulence genes is categorized as an APEC strain. In contrast, non-APEC isolates have less than five virulence genes (Carli et al., 2015).

3.3. Serum biochemistry profile

Concerning the serum biochemistry analysis, the infected birds had significantly (P<0.05) high ALT, AST, ALP, and globulin values and comparatively low TP and albumin concentrations at 3, 7 and 14-DPI (Table 2). Various authors found comparable results in *E. coli*-challenged chickens (Müller et al., 2002; Choi et al., 2004; Cao et al., 2013). A high ALT level indicates the degenerative changes in the hepatocyte, whereas an elevated AST level indicates myocardial damage and hepatocellular necrosis (Sharma et al., 2015). Hypoproteinemia and hypo-albuminemia are due to necrosis and degenerative changes in the liver and kidneys (Abiodun et al., 2015). Liver cirrhosis, hepatitis, and Kupffer cell proliferation

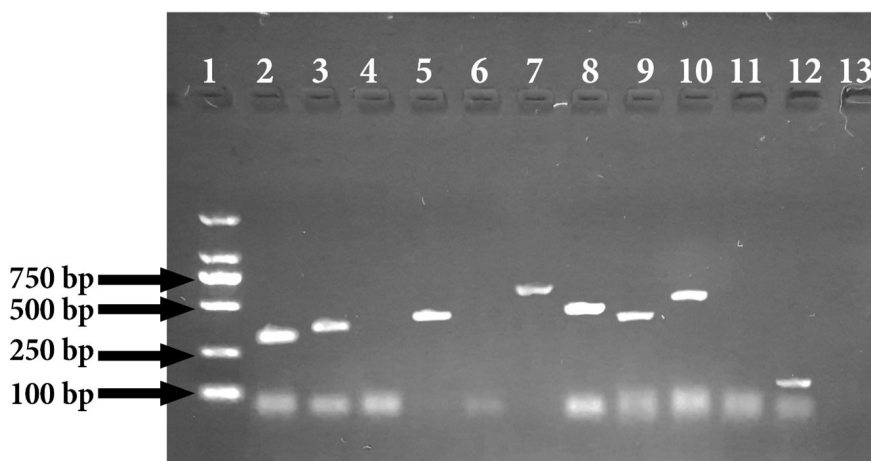


Figure 2. PCR results of virulence genes of *Escherichia coli* O78:K80. DNA Ladder (100-2000 bp, Catalogue number 3427A): Lane 1 positive virulence genes; Lane 2 (*iutA*, 302 bp); Lane 3 (*iss*, 323 bp); Lane 5 (*irp-2*, 714 bp); Lane 7 (*iucD*, 413 bp); Lane 8 (*ompT*, 496 bp); Lane 9 (*hlyF*, 450 bp) Lane 10 (*iroN*, 553 bp); Lane 12 (*cva/cvi*, 1181 bp). Negative virulence genes: Lane 4 (*papC*, 501 bp); Lane 6 (*tsh*, 824 bp); Lane 11 (*astA*, 116 bp). Negative control: Lane 13 (Distilled water).

may result in hyperglobulinemia (Sharma et al., 2015). In this study, the serum biochemistry profile of the infected birds indicates severe pathological stress on visceral and abdominal organs.

3.4. Serum cytokines level

The TNF- α and IL-6 levels were substantially high ($P < 0.05$) in infected birds compared to the non-infected group, which are in line with the findings of Choi et al. (2004), Cao et al. (2013) and Zhang et al. (2020). The maximum values were noticed at 3 DPI, followed by a subsequent decrease till the end of the trial (Table 3). Although IL-6 is considered to have an important role in the activation of immunological effector responses, however,

there is a scarcity of information about TNF- α in chickens (Awad et al., 2018). In another study, Zhang et al. (2020) described that homologous to mammalian, chickens' hepatocytes, mast cells, macrophages, endothelial cells, and connective tissue may secrete IL-6 and TNF- α with immunological activities. In agreement with our results, Gehad et al. (2002) observed a marked increase in IL-6 and TNF- α values following lipopolysaccharide (LPS) administration in chickens.

3.5. Clinical signs

Clinical features include anorexia, lethargy, dehydration, gasping, and brown diarrhea. Although, the severity of symptoms was gradually decreased with time, as endorsed

Table 2. Comparison of serum biochemistry profile of *Escherichia coli* O78:K80 infected and non-infected birds.

Parameters	Days post-infection	Groups		P-Value (P < 0.05)
		Infected	Non-infected	
ALT, IU/L	3	85.49 \pm 4.94 ^a	8.14 \pm 0.93 ^b	<0.0001
	7	81.07 \pm 4.33 ^a	9.36 \pm 0.82 ^b	<0.0001
	14	59.66 \pm 3.43 ^a	9.24 \pm 0.91 ^b	<0.0001
AST, IU/L	3	199.21 \pm 12.50 ^a	54.23 \pm 2.95 ^b	<0.0001
	7	150.43 \pm 3.62 ^a	50.28 \pm 3.09 ^b	<0.0001
	14	120.85 \pm 2.97 ^a	40.66 \pm 2.90 ^b	<0.0001
ALP, IU/L	3	197.258 \pm 7.67 ^a	91.20 \pm 2.53 ^b	<0.0001
	7	193.51 \pm 3.37 ^a	90.65 \pm 3.55 ^b	<0.0001
	14	168.75 \pm 8.37 ^a	90.71 \pm 2.77 ^b	<0.0001
TP, mg/dL	3	3.08 \pm 0.02	3.21 \pm 0.07	<0.0001
	7	3.12 \pm 0.05	3.22 \pm 0.03	0.06
	14	3.15 \pm 0.03	3.21 \pm 0.03	0.19
Albumin, mg/dL	3	1.62 \pm 0.02	1.74 \pm 0.03	<0.0001
	7	1.65 \pm 0.05	1.74 \pm 0.02	0.14
	14	1.67 \pm 0.03	1.76 \pm 0.02	0.41
Globulin, mg/dL	3	1.52 \pm 0.02	1.42 \pm 0.04	<0.0001
	7	1.51 \pm 0.03	1.42 \pm 0.02	<0.0001
	14	1.49 \pm 0.04	1.43 \pm 0.03	<0.0001

Superscripts "a-b" within a row represents significant different ($P < 0.05$) values between groups.

Table 3. Comparison of serum cytokines analysis of *Escherichia coli* O78:K80 infected and non-infected birds.

Parameters	Days post-infection	Groups		P-Value (P < 0.05)
		Infected	Non-infected	
IL-6, ng/L	3	137.59 \pm 3.19 ^a	38.48 \pm 0.39 ^b	<0.0001
	7	93.06 \pm 3.37 ^a	36.10 \pm 0.54 ^b	<0.0001
	14	66.71 \pm 3.41 ^a	35.32 \pm 0.71 ^b	<0.0001
TNF- α , ng/L	3	179.73 \pm 3.01 ^a	90.83 \pm 1.84 ^b	<0.0001
	7	148.05 \pm 2.52 ^a	87.62 \pm 1.65 ^b	<0.0001
	14	134.04 \pm 3.78 ^a	86.75 \pm 1.97 ^b	<0.0001

Superscripts "a-b" within a row represents significant different ($P < 0.05$) values between groups.

by Sharif et al. (2018) and Sonwane et al. (2019), who found a similar pattern of clinical signs in *E. coli* infected birds.

3.6. Gross pathology

On necropsy, hepatomegaly, fibrinous layer on the serous and parietal layers of liver and heart (Figure 3a), pulmonary congestion (Figure 3b), and necrotic lesions on splenic parenchyma (Figure 3c) were evident. Infected birds also had swollen kidneys (Figure 3d) and ecchymotic hemorrhages on intestinal mucosa (Figure 3e). These findings were in agreement with the observations of

Cătană et al. (2008), Sonwane et al. (2019) and Zhang et al. (2020) in *E. coli* infected chickens.

3.7. Histopathological examinations

Concerning the microscopic lesions, multifocal hepatocyte necrosis (Figure 4a), congested central veins (Figure 4b), and mononuclear cells (MNCs) infiltration in the perivascular area (Figure 4c) were observed in the liver section. Similarly, heart tissue had myocardial infarction (Figure 4d), cardiac hemorrhages (Figure 4e), and pericardial inflammatory

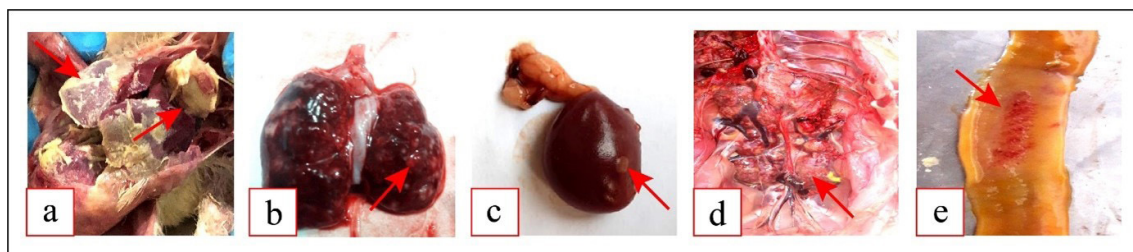


Figure 3. Gross pathological lesions of *E. coli* O78:K80 infected chickens (a). Fibrinous layer on the parenchyma of liver and heart (b). Congested lungs with necrotic lesions (c). Granulomatous necrotic spleen (d). Swollen and hemorrhagic kidneys (e). Ecchymotic hemorrhages on the mucosal surface of the intestine.

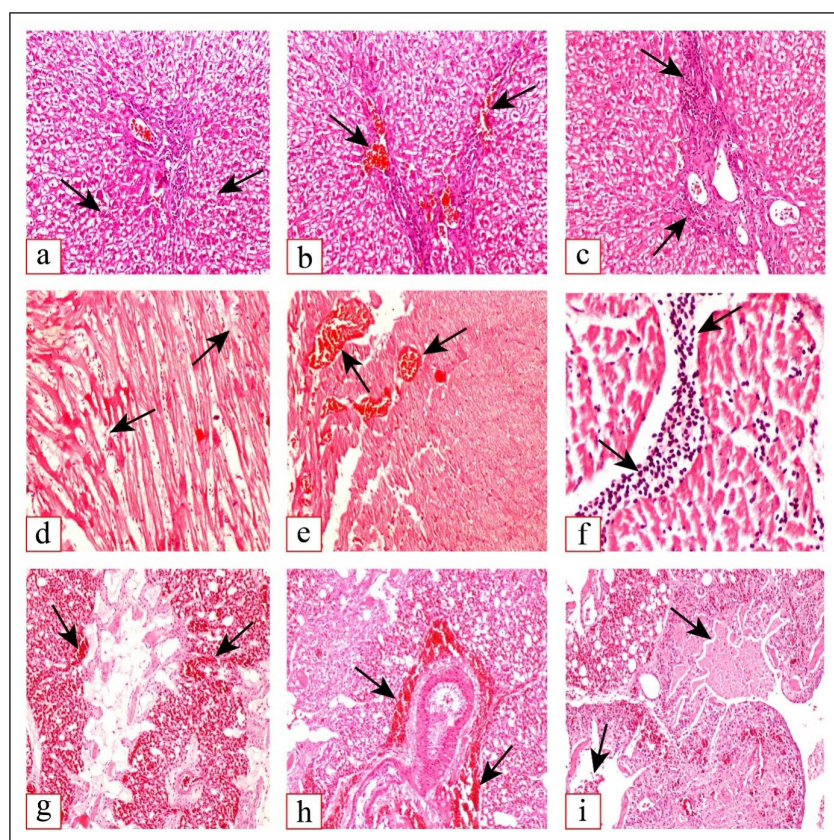


Figure 4. Microphotographs of *E. coli* O78:K80 infected chickens (hematoxylin and eosin stain, 10X) (a). Multifocal hepatocyte necrosis (b). Congested central veins in the liver (c). Mononuclear cells (MNCs) infiltration in perivascular area of the liver (d). Myocardium necrosis and loss of cardiac muscles striation (e). Myocardial hemorrhages (f). Inflammatory cells aggregation in pericardium (g). Congested pulmonary beds (h). Hemorrhages in the peribronchiolar area (i). Necrotic exudate in the lumen of pulmonary bronchioles.

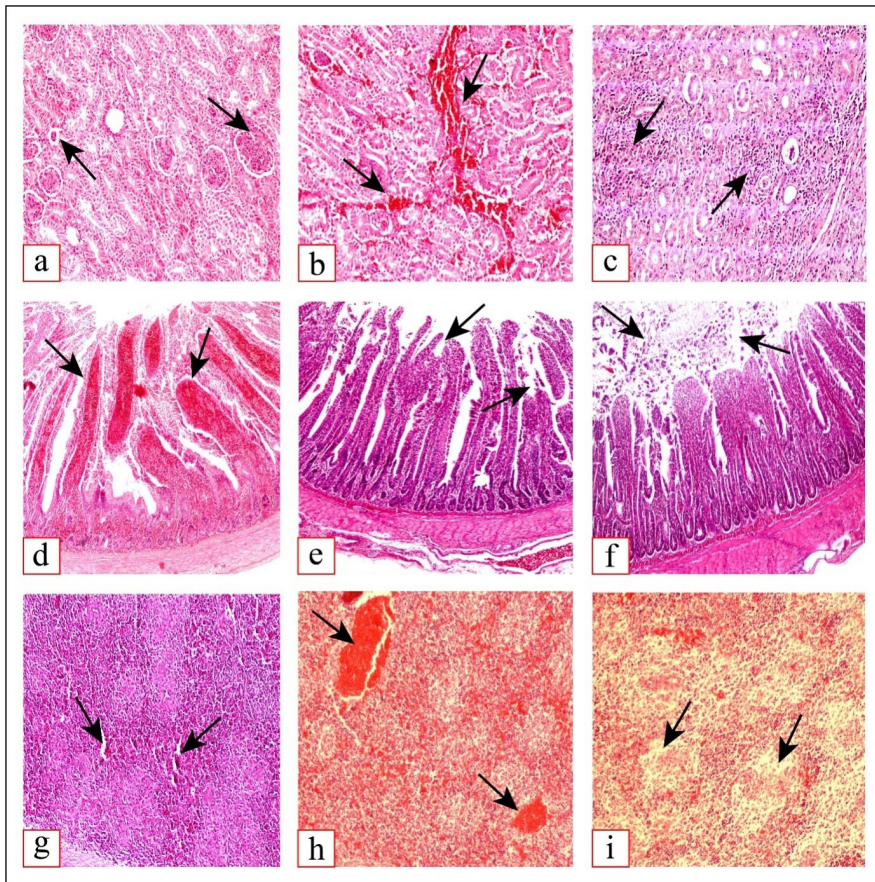


Figure 5. Microphotographs of *E. coli* O78:K80 infected chickens (hematoxylin and eosin stain, 10X) (a). Mild glomerulopathy (b). Renal hemorrhages and congestion (c). Interstitial nephritis (d). Extravasation of red blood cells in lamina propria of intestinal mucosa (e). Degenerative changes in epithelial cells of intestinal villi (f). Necrotic debris in the intestinal lumen (g). Focal necrosis in splenocytes (h). Hemorrhages in the spleen (i). Lymphopenia in the white pulp of the spleen.

cell aggregation (Figure 4f). The lungs sections contained congested pulmonary beds (Figure 4g), peribronchiolar pulmonary hemorrhages (Figure 4h), and necrotic exudate containing inflammatory cells in the pulmonary bronchiolar lumen (Figure 4i). In line with our results, Sharif et al. (2018) and Sonwane et al. (2019) reported degenerative changes in liver and heart sections of *E. coli* infected birds. Comparable to our results, Kumari et al. (2014) observed pulmonary congestion, hemorrhages, interstitial inflammatory cells infiltration and denuded bronchiolar epithelium in *E. coli* infected birds.

Kidney sections showed mild glomerulopathy (Figure 5a), renal hemorrhages (Figure 5b) and interstitial nephritis (Figure 5c). In the intestine, engorged blood vessels in lamina propria (Figure 5d), degenerative changes in epithelial cells (Figure 5e) and necrotic debris in the lumen (Figure 5f) were evident. Spleen sections showed focal splenocyte necrosis (Figure 5g), splenic hemorrhages (Figure 5h), and lymphopenia in white pulp (Figure 5i). Many authors have documented similar histological alterations in the kidney, intestine and spleen in *E. coli* infected broilers (Guabiraba and Schouler, 2015; Sharma et al., 2015; Mousa and Ali, 2018; Sonwane et al.,

2019). However, degenerative intestinal changes can be attributed to enterotoxin released by *E. coli* (Guabiraba and Schouler, 2015). Similarly, chick-lethal toxin (CLT) and immunosuppression induced by *E. coli* infection may cause lymphopenia and necrotic foci in immune organs (Wu et al., 2013; Kumari et al., 2014).

4. Conclusions

This study revealed the presence of multiple antibiotic-resistant (MAR) *E. coli* with virulence genes distribution in colibacillosis suspected chicken in Pakistan. In addition, the obtained *E. coli* O78:K80 isolate markedly altered the serum biochemistry profile and pro-inflammatory cytokines levels and induced severe macro and micro-pathological lesions. Therefore, rigorous screening and surveillance of MAR-APEC strains circulating in the field are required to mitigate colibacillosis risk. Hence, a holistic approach is necessary to prevent and control colibacillosis in Pakistan. This could be achieved by the active participation of veterinary professionals, poultry farmers, pharmaceutical stakeholders, and government regulatory agencies.

Acknowledgements

Authors thank the Deanship of Scientific Research at King Khalid University, Saudi Arabia, for funding this work under Grant no. (RGP-2/90/43).

References

- AARESTRUP, F.M., 2004. Monitoring of antimicrobial resistance among food animals: principles and limitations. *Journal of Veterinary Medicine, Series B*, vol. 51, no. 8-9, pp. 380-388. <http://dx.doi.org/10.1111/j.1439-0450.2004.00775.x>. PMID:15525370.
- ABIODUN, B.S., ADEDEJI, A.S., TAIWO, O. and GBENGA, A., 2015. Effects of Moringa oleifera root extract on the performance and serum biochemistry of *Escherichia coli* challenged broiler chicks. *Journal of Agricultural Sciences*, vol. 60, no. 4, pp. 505-513. <http://dx.doi.org/10.2298/JAS1504505A>.
- ALI, A., EL-MAWGOUD, A.I.A., DAHSHAN, A.H.M., EL-SAWAH, A.A., NASEF, S.A. and IBRAHIM, M., 2019. Virulence gene constellations associated with lethality in avian pathogenic *E. coli* recovered from broiler chickens. *Advances in Animal and Veterinary Sciences*, vol. 7, no. 12, pp. 1076-1082. <http://dx.doi.org/10.17582/journal.aavs/2019/7.12.1076.1082>.
- ALONSO, C.A., ZARAZAGA, M., SALLEM, R., JOUINI, A., SLAMA, K. and TORRES, C., 2017. Antibiotic resistance in *Escherichia coli* in husbandry animals: the African perspective. *Letters in Applied Microbiology*, vol. 64, no. 5, pp. 318-334. <http://dx.doi.org/10.1111/lam.12724>. PMID:28208218.
- AMIR, M., RIAZ, M., CHANG, Y.F., ISMAIL, A., HAMEED, A. and AHSIN, M., 2021. Antibiotic resistance in diarrheagenic *Escherichia coli* isolated from broiler chickens in Pakistan. *Journal of Food Quality and Hazards Control*, vol. 8, pp. 78-86. <http://dx.doi.org/10.18502/jfqhc.8.2.6472>.
- AWAD, A., ZAGLOOL, A.W. and KHALIL, S.R., 2018. Immunohaematological status and mRNA expression of the genes encoding interleukin-6, nuclear-factor kappa B, and tumor-necrosis factor- α in the spleen of broilers. *Animal Production Science*, vol. 59, no. 8, pp. 1454-1461. <http://dx.doi.org/10.1071/AN18102>.
- AZAM, M., MOHSIN, M., JOHNSON, T.J., SMITH, E.A., JOHNSON, A., UMAIR, M., SALEEMI, M.K. and SAJJAD-UR-RAHMAN, 2020. Genomic landscape of multi-drug resistant avian pathogenic *Escherichia coli* recovered from broilers. *Veterinary Microbiology*, vol. 247, p. 108766. <http://dx.doi.org/10.1016/j.vetmic.2020.108766>. PMID:32768218.
- AZAM, M., MOHSIN, M., RAHMAN, S. and SALEEMI, M.K., 2019. Virulence-associated genes and antimicrobial resistance among avian pathogenic *Escherichia coli* from colibacillosis affected broilers in Pakistan. *Tropical Animal Health and Production*, vol. 51, no. 5, pp. 1259-1265. <http://dx.doi.org/10.1007/s11250-019-01823-3>. PMID:30701453.
- BAKSHI, M., BAFGHI, M.F., ASTANI, A., RANJBAR, V.R., ZANDI, H. and VAKILI, M., 2017. Antimicrobial resistance pattern of *Escherichia coli* isolated from chickens with colibacillosis in Yazd, Iran. *Journal of Food Quality and Hazards Control*, vol. 4, no. 3, pp. 74-78.
- BARBIERI, N.L., OLIVEIRA, A.L.D., TEJKOWSKI, T.M., PAVANELO, D.B., MATTER, L.B., PINHEIRO, S.R.S., VAZ, T.M.I., NOLAN, L.K., LOGUE, C.M., BRITO, B.G.D. and HORN, F., 2015. Molecular characterization and clonal relationships among *Escherichia coli* strains isolated from broiler chickens with colisepticemia. *Foodborne Pathogens and Disease*, vol. 12, no. 1, pp. 74-83. <http://dx.doi.org/10.1089/fpd.2014.1815>. PMID: 25514382.
- CAO, G.T., ZENG, X.F., CHEN, A.G., ZHOU, L., ZHANG, L., XIAO, Y.P. and YANG, C.M., 2013. Effects of a probiotic, *Enterococcus faecium*, on growth performance, intestinal morphology, immune response, and cecal microflora in broiler chickens challenged with *Escherichia coli* K88. *Poultry Science*, vol. 92, no. 11, pp. 2949-2955. <http://dx.doi.org/10.3382/ps.2013-03366>. PMID:24135599.
- CARLI, S., IKUTA, N., LEHMANN, F.K.M., SILVEIRA, V.P., PREDEBON, G.M., FONSECA, A.S.K. and LUNGE, V.R., 2015. Virulence gene content in *Escherichia coli* isolates from poultry flocks with clinical signs of colibacillosis in Brazil. *Poultry Science*, vol. 94, no. 11, pp. 2635-2640. <http://dx.doi.org/10.3382/ps/pev256>. PMID:26371329.
- CĂTĂNĂ, N., POPA, V., HERMAN, V. and FODOR, I., 2008. Phenotypical and genotypical characteristics of *E. coli* strains isolated from avian colibacillosis outbreaks. *Lucrări Științifice Medicină Veterinară*, vol. 41, pp. 340-343.
- CHEN, J. and GRIFFITHS, M.W., 1998. PCR differentiation of *Escherichia coli* from other Gram-negative bacteria using primers derived from the nucleotide sequences flanking the gene encoding the universal stress protein. *Letters in Applied Microbiology*, vol. 27, no. 6, pp. 369-371. <http://dx.doi.org/10.1046/j.1472-765X.1998.00445.x>. PMID:9871356.
- CHOI, K.M., LEE, J., LEE, K.W., SEO, J.A., OH, J.H., KIM, S.G., KIM, N.H., CHOI, D.S. and BAIK, S.H., 2004. Comparison of serum concentrations of C-reactive protein, TNF- α , and interleukin 6 between elderly Korean women with normal and impaired glucose tolerance. *Diabetes Research and Clinical Practice*, vol. 64, no. 2, pp. 99-106. <http://dx.doi.org/10.1016/j.diabres.2003.10.007>. PMID:15063602.
- DZIVA, F. and STEVENS, M.P., 2008. Colibacillosis in poultry: unravelling the molecular basis of virulence of avian pathogenic *Escherichia coli* in their natural hosts. *Avian Pathology*, vol. 37, no. 4, pp. 355-366. <http://dx.doi.org/10.1080/03079450802216652>. PMID:18622850.
- EBRAHIMI-NIK, H., BASSAMI, M., MOHRI, M., RAD, M. and KHAN, M.I., 2018. Bacterial ghost of avian pathogenic *E. coli* (APEC) serotype O78: K80 as a homologous vaccine against avian colibacillosis. *PLoS One*, vol. 13, no. 3, p. e0194888. <http://dx.doi.org/10.1371/journal.pone.0194888>. PMID:29566080.
- EWERS, C., JANSSEN, T. and WIELER, L.H., 2003. Avian pathogenic *Escherichia coli* (APEC). *Berliner und Münchener tierärztliche Wochenschrift*, vol. 116, no. 9-10, pp. 381-395. PMID:14526468.
- EWERS, C., JANSSEN, T., KIESSLING, S., PHILIPP, H.C. and WIELER, L.H., 2004. Molecular epidemiology of avian pathogenic *Escherichia coli* (APEC) isolated from colisepticemia in poultry. *Veterinary Microbiology*, vol. 104, no. 1-2, pp. 91-101. <http://dx.doi.org/10.1016/j.vetmic.2004.09.008>. PMID:15530743.
- GE, X.Z., JIANG, J., PAN, Z., HU, L., WANG, S., WANG, H., LEUNG, F.C., DAI, J. and FAN, H., 2014. Comparative genomic analysis shows that avian pathogenic *Escherichia coli* isolate IMT5155 (O2: K1: H5; ST complex 95, ST140) shares close relationship with ST95 APEC O1: K1 and human ExPEC O18: K1 strains. *PLoS One*, vol. 9, no. 11, p. e112048. <http://dx.doi.org/10.1371/journal.pone.0112048>. PMID:25397580.
- GEHAD, A.E., LILLEHOJ, H.S., HENDRICKS III, G.L. and MASHALY, M.M., 2002. Initiation of humoral immunity. I. The role of cytokines and hormones in the initiation of humoral immunity using T-independent and T-dependent antigens. *Developmental and Comparative Immunology*, vol. 26, no. 8, pp. 751-759. [http://dx.doi.org/10.1016/S0145-305X\(02\)00020-4](http://dx.doi.org/10.1016/S0145-305X(02)00020-4). PMID:12206838.
- GIOVANARDI, D., CAMPAGNARI, E., RUFFONI, L.S., PESENTE, P., ORTALI, G. and FURLATTINI, V., 2005. Avian pathogenic *Escherichia coli* transmission from broiler breeders to

- their progeny in an integrated poultry production chain. *Avian Pathology*, vol. 34, no. 4, pp. 313-318. <http://dx.doi.org/10.1080/03079450500179046>. PMID:16147567.
- GUABIRABA, R. and SCHOUER, C., 2015. Avian colibacillosis: still many black holes. *FEMS Microbiology Letters*, vol. 362, no. 15, p. fnv118. <http://dx.doi.org/10.1093/femsle/fnv118>. PMID:26204893.
- HUSSAIN, H.I., IQBAL, Z., SELEEM, M.N., HUANG, D., SATTAR, A., HAO, H. and YUAN, Z., 2017. Virulence and transcriptome profile of multidrug-resistant *Escherichia coli* from chicken. *Scientific Reports*, vol. 7, no. 1, p. 8335. <http://dx.doi.org/10.1038/s41598-017-07798-1>. PMID:28827616.
- IEVY, S., ISLAM, M.S., SOBUR, M.A., TALUKDER, M., RAHMAN, M.B., KHAN, M.F.R. and RAHMAN, M.T., 2020. Molecular detection of avian pathogenic *Escherichia coli* (APEC) for the first time in layer farms in Bangladesh and their antibiotic resistance patterns. *Microorganisms*, vol. 8, no. 7, p. 1021. <http://dx.doi.org/10.3390/microorganisms8071021>. PMID:32660167.
- JAYAWEERA, T., GAMAGE, H., MAHANAMA, R., ELLEPOLA, W., YASAWATHIE, D. and RUWANDEEPIKA, H., 2018. A study on changes in gut microflora, blood glucose level and lipid profile of broiler chickens fed with *Murraya koenigii* supplemented diet. *Asian Journal of Research in Animal and Veterinary Sciences*, vol. 1, no. 3, pp. 1-9.
- JEONG, Y.W., KIM, T.E., KIM, J.H. and KWON, H.J., 2012. Pathotyping avian pathogenic *Escherichia coli* strains in Korea. *Journal of Veterinary Science*, vol. 13, no. 2, pp. 145-152. <http://dx.doi.org/10.4142/jvs.2012.13.2.145>. PMID: 22705736.<jrn>
- KEMMETT, K., WILLIAMS, N.J., CHALONER, G., HUMPHREY, S., WIGLEY, P. and HUMPHREY, T., 2014. The contribution of systemic *Escherichia coli* infection to the early mortalities of commercial broiler chickens. *Avian Pathology*, vol. 43, no. 1, pp. 37-42. <http://dx.doi.org/10.1080/03079457.2013.866213>. PMID: 24328462.<jrn>
- KOUTSIANOS, D., ATHANASIOU, L., MOSSIALOS, D. and KOUTOULIS, K., 2021. Colibacillosis in poultry: a disease overview and the new perspectives for its control and prevention. *Journal of the Hellenic Veterinary Medical Society*, vol. 71, no. 4, pp. 2425-2436. <http://dx.doi.org/10.12681/jhvms.25915>.
- KUMARI, M., GUPTA, R.P. and SHARMA, R., 2014. Biochemical and immunological response of *Ocimum sanctum* in chickens experimentally infected with *Escherichia coli*. *Indian Journal of Veterinary Pathology*, vol. 38, no. 2, pp. 98-102. <http://dx.doi.org/10.5958/0973-970X.2014.01147.X>.
- KWON, S.G., CHA, S.Y., CHOI, E.J., KIM, B., SONG, H.J. and JANG, H.K., 2008. Epidemiological prevalence of avian pathogenic *Escherichia coli* differentiated by multiplex PCR from commercial chickens and hatchery in Korea. *Journal of Bacteriology and Virology*, vol. 38, no. 4, pp. 179-188. <http://dx.doi.org/10.4167/jbv.2008.38.4.179>.
- MATIN, M.A., ISLAM, M.A. and KHATUN, M.M., 2017. Prevalence of colibacillosis in chickens in greater Mymensingh district of Bangladesh. *Veterinary World*, vol. 10, no. 1, pp. 29-33. <http://dx.doi.org/10.14202/vetworld.2017.29-33>. PMID:28246445.
- MILES, T.D., MCLAUGHLIN, W. and BROWN, P.D., 2006. Antimicrobial resistance of *Escherichia coli* isolates from broiler chickens and humans. *BMC Veterinary Research*, vol. 2, no. 1, p. 7. <http://dx.doi.org/10.1186/1746-6148-2-7>. PMID:16460561.
- MOHAMED, L., GE, Z., YUEHUA, L., YUBIN, G., RACHID, K., MUSTAPHA, O., JUNWEI, W. and KARINE, O., 2018. Virulence traits of avian pathogenic (APEC) and fecal (AFEC) *E. coli* isolated from broiler chickens in Algeria. *Tropical Animal Health and Production*, vol. 50, no. 3, pp. 547-553. <http://dx.doi.org/10.1007/s11250-017-1467-5>. PMID: 29164427.<jrn>
- MOUSA, M.D. and ALI, H.B., 2018. Impact of boron and nano-boron on the heterophil/lymphocyte ratio and histopathological changes of liver and kidney in broiler chickens infected with *Escherichia coli*. *Magallat al-Basrat Li-l-Abhat al-Baytariyyat*, vol. 17, no. 3, pp. 290-306.
- MÜLLER, S., MARTIN, S., KOENIG, W., HANIFI-MOGHADDAM, P., RATHMANN, W., HAASSTERT, B., GIANI, G., ILLIG, T., THORAND, B. and KOLB, H., 2002. Impaired glucose tolerance is associated with increased serum concentrations of interleukin 6 and co-regulated acute-phase proteins but not TNF-alpha or its receptors. *Diabetologia*, vol. 45, no. 6, pp. 805-812. <http://dx.doi.org/10.1007/s00125-002-0829-2>. PMID:12107724.
- PARREIRA, V.R. and GYLES, C.L., 2003. A novel pathogenicity island integrated adjacent to the thrW tRNA gene of avian pathogenic *Escherichia coli* encodes a vacuolating autotransporter toxin. *Infection and Immunity*, vol. 71, no. 9, pp. 5087-5096. <http://dx.doi.org/10.1128/IAI.71.9.5087-5096.2003>. PMID:12933851.
- RAFIQUE, M., POTTER, R.F., FERREIRO, A., WALLACE, M.A., RAHIM, A., MALIK, A.A., SIDDIQUE, N., ABBAS, M.A., D'SOUZA, A.W., BURNHAM, C.-A.D., ALI, N. and DANTAS, G., 2020. Genomic characterization of antibiotic resistant *Escherichia coli* isolated from domestic chickens in Pakistan. *Frontiers in Microbiology*, vol. 10, p. 3052. <http://dx.doi.org/10.3389/fmicb.2019.03052>. PMID:32010104.
- RAHMAN, S. and MOHSIN, M., 2019. The under reported issue of antibiotic-resistance in food-producing animals in Pakistan. *Pakistan Veterinary Journal*, vol. 39, no. 3, pp. 323-328. <http://dx.doi.org/10.29261/pakvetj/2019.037>.
- SAROWSKA, J., FUTOMA-KOLOCH, B., JAMA-KMIECIK, A., FREJ-MADRZAK, M., KSIAZCZYK, M., BUGLA-PLOSKONSKA, G. and CHOROSZY-KROL, I., 2019. Virulence factors, prevalence and potential transmission of extraintestinal pathogenic *Escherichia coli* isolated from different sources: recent reports. *Gut Pathogens*, vol. 11, no. 1, p. 10. <http://dx.doi.org/10.1186/s13099-019-0290-0>. PMID:30828388.
- SHARAF, S., KHAN, M.R., ASLAM, A., RABBANI, M., SHARF, A., IJAZ, M., ANJUM, A. and HUSSAIN, N., 2021. Toxicological effects of heavy metals from industrial drainage wastewater on vital organs of small ruminants in Lahore. *Environmental Science and Pollution Research International*, vol. 28, no. 3, pp. 3533-3543. <http://dx.doi.org/10.1007/s11356-020-10051-4>. PMID:32918689.
- SHARIF, H., JAVED, M.T., GHAFUOR, H., YOUNIS, M., KHAN, S.U., REHMAN, A., ASHFAQ, K., SALEEM, G., MANZOOR, F., TARIQ, N. and RAFIQUE, A., 2018. Association of pathogenicity genes (cvaC, iss, iutA, Stx1A, Stx2A and Vat) of *E. coli* with gross and histopathological lesions of colibacillosis in broilers. *Biomedical Letters*, vol. 4, no. 2, pp. 40-46.
- SHARMA, V., JAKHAR, K.K., NEHRA, V. and KUMAR, S., 2015. Biochemical studies in experimentally *Escherichia coli* infected broiler chicken supplemented with neem (*Azadirachta indica*) leaf extract. *Veterinary World*, vol. 8, no. 11, pp. 1340-1345. <http://dx.doi.org/10.14202/vetworld.2015.1340-1345>. PMID:27047040.
- SONWANE, S.R., INGOLE, R.S., HEDAU, M.S., HAJARE, S.W. and INGAWALE, M.V., 2019. The ameliorative effect of *Andrographis paniculata* on *E. coli*-induced pathology in broilers. *Veterinarski Arhiv*, vol. 89, no. 4, pp. 545-557. <http://dx.doi.org/10.24099/vet.arhiv.0266>.
- SPELLBERG, B., 2014. The future of antibiotics. *Critical Care*, vol. 18, no. 3, p. 228. <http://dx.doi.org/10.1186/cc13948>. PMID:25043962.

- SUBEDI, M., LUITEL, H., DEVKOTA, B., BHATTARAI, R.K., PHUYAL, S., PANTHI, P., SHRESTHA, A. and CHAUDHARY, D.K., 2018. Antibiotic resistance pattern and virulence genes content in avian pathogenic *Escherichia coli* (APEC) from broiler chickens in Chitwan, Nepal. *BMC Veterinary Research*, vol. 14, p. 113. <http://dx.doi.org/10.1186/s12917-018-1442-z>.
- SULTAN, R., ASLAM, A., SALEEM, G., ANJUM, A., KRULL, W., KUMOSANI, T. and BARBOUR, E.K., 2017. Studies on performance, immunity, and safety of broilers vaccinated with killed H9N2 vaccine and supplemented with essential oils of Mentofin® in drinking water. *International Journal of Applied Research in Veterinary Medicine*, vol. 15, no. 2, pp. 67-74.
- WU, Q.J., ZHOU, Y.M., WU, Y.N., ZHANG, L.L. and WANG, T., 2013. The effects of natural and modified clinoptilolite on intestinal barrier function and immune response to LPS in broiler chickens. *Veterinary Immunology and Immunopathology*, vol. 153, no. 1-2, pp. 70-76. <http://dx.doi.org/10.1016/j.vetimm.2013.02.006>. PMID:23453767.
- ZHANG, L., ZHANG, L., ZHAN, X., ZENG, X., ZHOU, L., CAO, G., CHEN, A. and YANG, C., 2016. Effects of dietary supplementation of probiotic, *Clostridium butyricum*, on growth performance, immune response, intestinal barrier function, and digestive enzyme activity in broiler chickens challenged with *Escherichia coli* K88. *Journal of Animal Science and Biotechnology*, vol. 7, no. 1, p. 3. <http://dx.doi.org/10.1186/s40104-016-0061-4>. PMID:26819705.
- ZHANG, M., KOU, J., WU, Y., WANG, M., ZHOU, X., YANG, Y. and WU, Z., 2020. Dietary genistein supplementation improves intestinal mucosal barrier function in *Escherichia coli* O78-challenged broilers. *The Journal of Nutritional Biochemistry*, vol. 77, no. 3, p. 108267. <http://dx.doi.org/10.1016/j.jnutbio.2019.108267>. PMID:32000135.