

Hyperfibrotic myelodysplasia: case report with response to steroid therapy

Recebido em 13/07/01
Aceito para publicação em 30/10/01

Mielodisplasia hiperfibrótica: relato de caso com resposta à terapia com corticosteróides

Maura Romeo¹

Maria de Lourdes Lopes Ferrari Chauffaille²

Daniella Marcia Maranhão Bahia¹

Maria Regina Regis Silva³

key words

Myelodysplastic syndromes

Hyperfibrotic

Steroid therapy

abstract

Context: Bone marrow fibrosis is observed in different clonal hematological disorders including myeloproliferative diseases, acute leukemias and myelodysplastic syndromes. In myelodysplastic syndrome a new clinical-pathological entity with significant increase in reticulin fibers has been suggested, and the term hyperfibrotic myelodysplasia was used to define it. Bone marrow biopsy shows increased reticulin fibers, megakaryocytic hyperplasia and dysplasia. Differential diagnosis with primary myelofibrosis may be difficult and hybrid cases may occur. Patients with hyperfibrotic myelodysplastic syndrome responding to treatment with steroids have been reported. In the majority of cases there was only hematological remission, although resolution of fibrosis occurred in one patient. Design: Case report. Case report: A 62-year old male presented in June 95 with a 6-month history of lethargy and dispnea. On examination he was pale without hepato-splenomegaly. Hemoglobin concentration was 3g/dL with marked anisocytosis without teardrop cells. Bone marrow aspirates resulted in dry tap. Bone marrow biopsy showed hypercellularity with increased fibrosis (grade IV) obliterating the normal marrow architecture. Megakaryocytes were increased in number, with abnormal morphology. Monoclonal antibodies against factor VIII and CD31 revealed that both were expressed in megakaryocytes. Prednisone (1mg/Kg) was introduced in June 1996, after what his symptoms lessened and hemoglobin increased. Bone marrow fibrosis decreased (grade IV to grade II). He has become transfusion independent till Jan/1999, when hemoglobin fell to 6g/dL and prednisone was reintroduced with a prompt rise in hemoglobin concentration.

resumo

Contexto: A fibrose de medula óssea é encontrada em algumas doenças hematológicas clonais, incluindo síndromes mieloproliferativas, leucemias agudas e síndromes mielodisplásicas. Nas síndromes mielodisplásicas, uma nova entidade clinicopatológica com acentuado aumento das fibras de reticulina tem sido sugerida, e o termo "síndrome mielodisplásica hiperfibrótica" é usado para sua definição. A biópsia de medula óssea mostra aumento das fibras de reticulina e hiperplasia megacariocítica com displasia. O diagnóstico diferencial com mielofibrose primária é difícil, e casos híbridos podem ocorrer. Pacientes com síndromes mielodisplásicas hiperfibróticas que respondem à terapia com corticosteróide têm sido descritos. Na maioria dos casos a remissão é apenas hematológica, mas resolução da fibrose de medula óssea já ocorreu em um paciente. Planejamento: Relato de caso. Relato: Paciente do sexo masculino, 62 anos de idade, apresentou-se, em junho de 1995, com história de seis meses de letargia e dispnéia. Ao exame, mostrou-se pálido, sem hepatoesplenomegalia. A concentração de hemoglobina foi de 3g/dl, com acentuada anisocitose, mas sem "células em lágrimas". Os aspirados de medula óssea mostraram-se "secos", enquanto a biópsia revelou hiper celularidade e fibrose grau IV, obliterando a arquitetura habitual. Os megacariócitos estavam em número aumentado, com morfologia anômala, reagindo com anticorpos antifator VIII e CD31. Com a introdução de prednisona 1mg/kg em junho de 1996, os sintomas reduziram, a hemoglobina elevou-se e a fibrose cedeu para grau II, tornando-se independente de transfusões até janeiro de 1999. Então, a hemoglobina caiu para 6g/dl e, com a introdução de prednisona, houve pronta elevação da hemoglobina.

unitermos

Síndromes mielodisplásicas

Hiperfibrótica

Corticoterapia

1. M.D. Disciplina de Hematologia e Hemoterapia da Universidade Federal de São Paulo/Escola Paulista de Medicina, São Paulo, Brasil.
2. M.D., Ph.D. Professora da Disciplina de Hematologia e Hemoterapia da Universidade Federal de São Paulo/Escola Paulista de Medicina, São Paulo, Brasil.
3. M.D. Professora do Departamento de Patologia Aplicada da Universidade Federal de São Paulo/Escola Paulista de Medicina, São Paulo, Brasil.

Introduction

Bone marrow fibrosis is observed in different clonal hematological disorders including myeloproliferative diseases, acute leukemias and myelodysplastic syndromes (MDS) (2). In the last one, an increase in reticulin fibers of varying degrees occurs in 50% of primary and in 80% of cases secondary to treatment with alkylating agents and radiotherapy. About 20% of MDS cases show significant increase in reticulin fibers with or without collagen formation (3).

In 1988, Pagliuca *et al.* (4) reported 10 cases of primary MDS with pronounced marrow fibrosis and used the term "hyperfibrotic myelodysplasia" to define them. Bone marrow biopsy showed increase in reticulin fibers, megakaryocytic hyperplasia and dysplasia. Bone marrow aspirates are generally hypocellular or dry and classification according to FAB is not possible. When adequate bone marrow aspirate is obtained it shows dysplasia of one, two or all three cell lines with characteristic morphological changes of MDS (2). On examination, hepatic or splenic enlargement is absent or discrete (4).

Watts *et al.* (5), in 1991, reported cases of hyperfibrotic MDS that responded to treatment with steroids. In the majority of the cases there was just hematological remission, but one patient has shown resolution of marrow fibrosis following steroid therapy.

Case report

A 62-year old male presented in June 1995 with a six-month history of lethargy and dyspnea on exertion. On clinical examination he was pale, without hepato or splenomegaly. Hemoglobin concentration was 3g/dL, white blood cell (WBC) count $4 \times 10^9/L$ and platelets $160 \times 10^9/L$. The differential WBC count was: neutrophils 65%, eosinophils 2%, basophils 0%, lymphocytes 28% and monocytes 5%. Dysmorphic erythrocytic changes included marked anisocytosis without teardrop cells. The neutrophils were agranular with many pseudo Pelger-Hüet forms. Bone marrow aspirates resulted in a dry tap. Bone marrow biopsy showed a hypercellular marrow with reduced erythroid elements. Megakaryocytes were increased in number, having abnormal morphology. Monoclonal antibodies against factor VIII and CD31 revealed expression of both in megakaryocytes. Micro-megakaryocytes were present. There was a great increase in reticulin fibers (Gomori's silver impregnation for reticulin

fibers) obliterating the normal marrow architecture (grade IV fibrosis) (3) (Figure 1). One year after the diagnosis he was transfusion dependent (04 packed red cells/month), without response to further treatment (B6, folic acid, and erythropoetin). In June 1996, prednisone (1mg/Kg) was started and maintained for 4 weeks. His symptoms lessened and hemoglobin concentration increased from 6g/dL to 13,2 g/dL. Bone marrow biopsy revealed reduction of marrow fibrosis (from grade IV to II) (3) (Figure 2). He became transfusion independent till Jan/1999 when hemoglobin fell to 6g/dL and packed red cell transfusions were necessary. At that moment there were no signal of infection or other cause for the anemia. Prednisone was restarted, maintained for 4 weeks and there was a prompt rise in hemoglobin concentration.

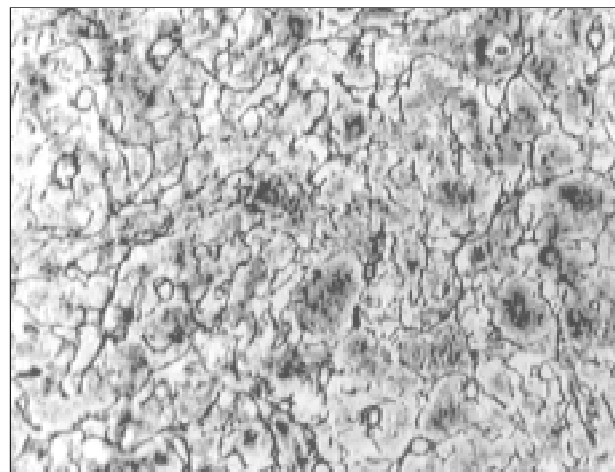


Figure 1 – Bone marrow biopsy showing a great increase in reticulin fibers by Gomori's silver impregnation (grade IV fibrosis)

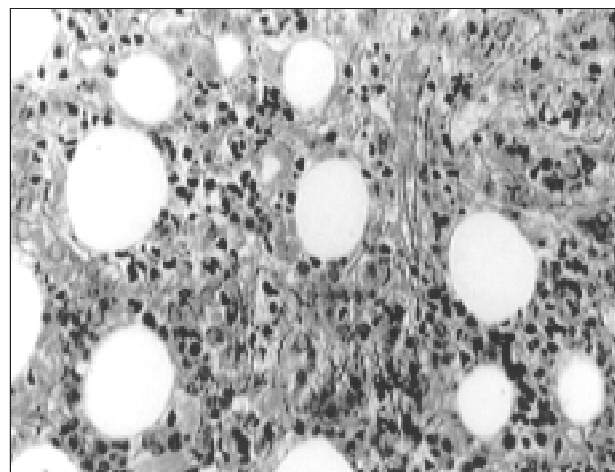


Figure 2 – Bone marrow biopsy showing reduction of marrow fibrosis (from grade IV to II)

Discussion

Hyperfibrotic MDS is a clinic-pathological entity and should be distinguished from the classical MDS subgroups defined by FAB cooperative group in 1982. Differential diagnosis between hyperfibrotic MDS and primary myelofibrosis is difficult (2) and some authors suggest that hybrid cases, called hyperfibrotic MDS-myelofibrosis, may occur. Megakaryocytic hyperplasia with dysplasia and increased marrow fibrosis are common to both. Presence of dysplasia of all three lineages and modest or absent hepatosplenomegaly, support the diagnosis of hyperfibrotic MDS. In equivocal cases ferrokinetic studies are recommended to exclude extramedullary haematopoiesis regarded as *sine qua non* of idiopathic myelofibrosis (2).

Fibrosis of the marrow as a consequence of clonal hematopoietic disorder with a prominent megakaryocytic component is possibly a result of stimulation by platelet-derived polypeptide factors. These factors include platelet-derived growth factor and transforming growth factor beta in addition to platelet factor-IV, which inhibits collagen breakdown. Maybe the action of steroids in this process could justify the response of these patients to steroid therapy (2, 5)

The patient presented in this paper is a typical case of hyperfibrotic MDS. Dysplasia observed in erythroid and granulocytes elements associated with absent hepatosplenomegaly support this diagnosis. Histopathology of marrow did not permit in the present case differentiation between hyperfibrotic-MDS and myelofibrosis, but erythroid hypoplasia observed had already been reported before in hyperfibrotic-MDS patients (4).

MDS treatment is divided into supportive care, appropriate for older patients and those with indolent disease; and aggressive chemotherapy and stem cell transplantation for selected patients. The International Prognostic Scoring System (1) can help identify patients who are likely to have an indolent course and are best treated with supportive measures.

Further studies correlating pathologic, cytogenetic and molecular data with clinical outcome are necessary to provide more information for proper classification and treatment of this disease.

Acknowledgements

We thank Prof. Maria Claudia Zerbini, M.D, Ph.D., for helpful comments and review.

References

1. Greenberg, P. et al. International Scoring System for evaluating prognosis in myelodysplastic syndrome. *Blood*, 89: 2079-88, 1997, erratum *Blood*, 91: 1100, 1998.
2. Lambertenghi-Deliliers, G. et al. Myelodysplastic syndrome with increase marrow fibrosis: a distinct clinical-pathological entity. *Br. J. Haematol.*, 78:161-6, 1991.
3. Manoharan, A.; Horsley, R. & Pitney, W.R. The reticulin content of bone marrow in acute leukemia in adults. *Br. J. Haematol.*, 43: 185-90, 1979.
4. Pagliuca, A. et al. Myelofibrosis in primary myelodysplastic syndrome: a clinic-morphological study of 10 cases. *Br. J. Haematol.*, 71: 499-504, 1989.
5. Watts, E.J. et al. Hyperfibrotic myelodysplasia: a report of three cases showing haematological remission following treatment with prednisolone. *Br. J. Haematol.*, 78: 120-4, 1991.

Endereço para correspondência

Maria de Lourdes Chauffaille
 Disciplina de Hematologia e Hemoterapia
 da Universidade Federal de São Paulo
 Escola Paulista de Medicina
 Rua Botucatu 740 – Prédio dos
 Ambulatórios – 3º andar
 CEP 04023-900 – São Paulo-SP
 Tel.: (55-11) 5576-4237
 Fax: (55-11) 5571-8806
 e-mail: chauffaille@hemato.epm.com.br