

Use of the fluid obtained by puncture of cystic hygroma: an alternative method for fetal karyotyping

Uso do fluido obtido por punção do higroma cístico: método alternativo para cariotipagem fetal

Maiara A. Floriani¹; Luiza E. Dorfman¹; Dayane B. Koshiyama¹; Tatiana D. Zen¹; Jorge Alberto B. Telles²; André C. Cunha²; Paulo Ricardo G. Zen^{1,3}; Rafael Fabiano M. Rosa^{1,3}

1. Universidade Federal de Ciências da Saúde de Porto Alegre (UFCSA), Rio Grande do Sul, Brazil. 2. Hospital Materno-Infantil Presidente Vargas (HMIPV), Rio Grande do Sul, Brazil. 3. Complexo Hospitalar Santa Casa de Porto Alegre (CHSCPA), Rio Grande do Sul, Brazil.

ABSTRACT

The aim of our study was to report the case of a fetus with Turner syndrome (TS) diagnosed by karyotype from cystic hygroma (CH) fluid, highlighting the applications and importance of this procedure. First-trimester screening revealed an increased nuchal translucency measurement, cervical cystic hygroma and head and trunk subcutaneous edema. The presence of oligohydramnios prevented the performance of amniocentesis. We performed puncture of the CH for fetal karyotyping, which revealed X-chromosome monosomy (45,X), compatible with TS. Therefore, the use of CH fluid as an alternative sample for fetal karyotyping may be considered when conventional invasive procedures can not be performed.

Key words: karyotype; cystic lymphangioma; Turner syndrome; chromosome abnormalities; genetic counseling.

CASE REPORT

The aim of our study was to report a fetus with Turner syndrome (TS) diagnosed by karyotype from cystic hygroma (CH) fluid, emphasizing the applications and importance of this procedure. A 38-year-old healthy pregnant woman was in her third pregnancy and had a history of two previous miscarriages (all occurred during the first trimester). There was no family history of birth defects or genetic disorders. First-trimester screening revealed an increased nuchal translucency measurement (7 mm), cervical cystic hygroma and head and trunk subcutaneous edema. Ascites was also noted later. There was oligohydramnios, which prevented the execution of amniocentesis. Therefore, at 18 weeks of pregnancy, a puncture of the CH was held for fetal karyotyping, following a long-term culture. Chromosomal analysis showed a X-chromosome monosomy - 45,X[21], consistent with TS. At 21 weeks, there was no fetal heartbeat and spontaneous elimination of the fetus occurred two days later.

TS is a multisystemic disorder characterized by partial or total X-chromosome monosomy, seen in 1:2,500-3,000

born alive females. It can be diagnosed at different life stages, including the intrauterine period. Ultrasound findings, such as CH and hydrops, may assist in its detection⁽¹⁾. Prenatal diagnosis is usually performed by karyotype analysis from amniotic fluid samples. However, as found in the present report, this type of sample or even fetal blood by cordocentesis becomes unable to obtain due to obstructions by large cysts or oligohydramnios⁽²⁾.

The use of CH fluid, obtained through direct hygroma puncture, can be used as an alternative procedure⁽²⁾. Fetal CH is characterized by single or multiple lymphatic congenital cysts and is often found associated with TS⁽³⁾. The procedure is similar to amniocentesis and has low complication rate. If the CH is multiloculated, it is possible to puncture and analyze different regions (especially due to the possibility of mosaicism)⁽⁴⁾. The karyotype is performed through lymphocyte culture from cystic cells that has a mitotic index and metaphases quality compatible with a blood lymphocyte culture. The karyotype test results using CH puncture are obtained in four days, while by amniocentesis they range from 14-24 days⁽⁵⁾ (**Figures 1 and 2**).

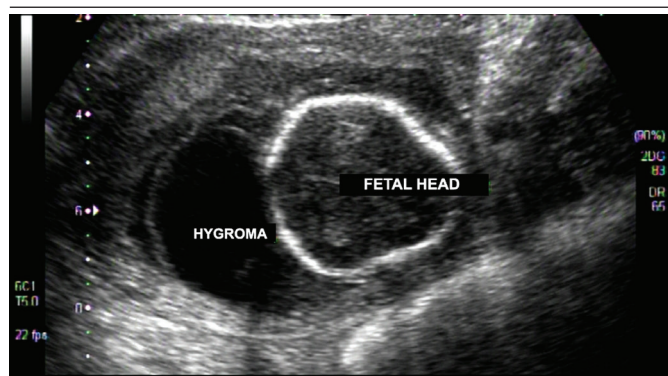


FIGURE 1 – Fetal ultrasound performed at 16 weeks of gestation showing the cystic hygroma

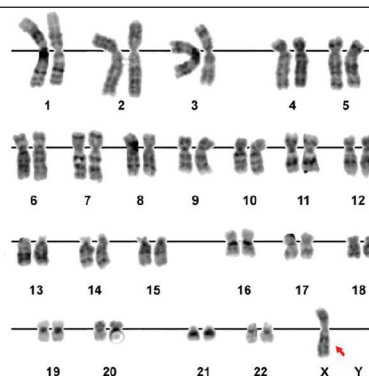


FIGURE 2 – Fetal karyotyping performed from cystic hygroma cells revealing a X-monosomy (45,X), consistent with Turner syndrome

In our study, the performance of the fetal karyotype by CH puncture allowed the correct diagnosis and genetic counseling. Despite the advanced maternal age, TS is not associated with it. Moreover, the diagnosis was important to assess the prognosis.

From all fetuses with TS, 99% progress to spontaneous abortion⁽¹⁾, as seen in this case. Thus, the use of alternative samples for fetal karyotyping, such as CH fluid, may be considered when conventional invasive procedures can not be performed.

RESUMO

Relatamos o caso de um feto com síndrome de Turner (TS), diagnosticado por cariótipo de fluido do bigroma cístico (CH), salientando as aplicações e a importância desse procedimento. Rastreamento de primeiro trimestre revelou aumento da medida da translucência nucal, bigroma cístico cervical e edema subcutâneo de cabeça e tronco. A presença de oligodrâmnio impediu a execução de amniocentese. Realizamos punção do CH para cariotipagem fetal, que revelou monossomia do cromossomo X (45,X), compatível com TS. Portanto, o uso de fluido do CH, como amostra alternativa para cariotipagem fetal, pode ser considerado quando procedimentos invasivos convencionais não podem ser realizados.

Unitermos: cariótipo; linfangioma cístico; síndrome de Turner; aberrações cromossômicas; aconselhamento genético.

REFERENCES

1. Pinsker JE. Clinical review: Turner syndrome: updating the paradigm of clinical care. *J Clin Endocrinol Metab.* 2012; 97: E994-1003.
2. Gole LA, Anandakumar C, Bongso A, Chua TM, Wong YC, Ratnam SS. Analysis of cystic hygroma, ascitic, and pleural fluids by conventional lymphocyte culture and fluorescent in situ hybridization. *Prenat Diagn.* 1997; 17: 1151-7.
3. Gallagher PG, Mahoney MJ, Gosche JR. Cystic hygroma in the fetus and newborn. *Semin Perinatol.* 1999; 23: 341-56.
4. Verschraegen-Spae A, De Paepe A. Why karyotype cystic hygroma cells? *Prenat Diagn.* 1994; 14(7): 649-50.
5. Costa D, Borrell A, Margarit E, et al. Rapid fetal karyotype from cystic hygroma and pleural effusions. *Prenat Diagn.* 1995; 15: 141-8.

CORRESPONDING AUTHOR

Rafael Fabiano Machado Rosa
 UFCSPA; Rua Sarmento Leite, 245, sala 403; Centro; CEP: 90050-170; Porto Alegre-RS, Brasil; Phone: +55 (51) 3303-8771; e-mail: rfmrosa@gmail.com.