

Thrombotic thrombocytopenic purpura: a case report

Púrpura trombocitopênica trombótica: relato de caso

João Paulo N. Drumond¹; Rima M. Abou-Arabi¹; Raissa P. C. Figueiredo¹; Vanessa N. Mourão¹; Juliana B. Aiziro¹; Décio N. Caly¹; Afonso José P. Cortez^{1,2}

1. Universidade de Santo Amaro, São Paulo, Brazil. 2. Hospital Geral do Grajaú, Clínica Médica, São Paulo, Brazil.

ABSTRACT

Thrombotic thrombocytopenic purpura (TTP) is a severe hemorrhagic syndrome characterized by thrombocytopenia, microangiopathic hemolytic anemia and microvascular occlusion, besides the associated symptoms that may or may not be present: fever, neurological and renal impairment. The pathophysiology involves the autoimmune or genetic deficiency of a metalloproteinases activity (*ADAMTS-13*), responsible for the von Willebrand Factor cleavage. The treatment is based on plasmapheresis; and in acute or recurrent cases, corticosteroids and immunosuppressants are associated. In this article, we will discuss a case report about this disease, initially treated in the Emergency Room and followed in the Intensive Care Unit of a public reference hospital in São Paulo city, Brazil. All clinical diagnostic criteria were completely filled, facilitating the therapeutic approach of the patient. The report evidences that rapid intervention when made early diagnosis evolves with a good prognosis, and this pathology must be present as a differential diagnosis in the medical routine.

Key words: purpura thrombotic thrombocytopenic; anemia hemolytic; plasmapheresis.

INTRODUCTION

A group of serious diseases known as microangiopathic hemolytic anemia, represented by hemolytic-uremic syndrome (HUS) and thrombotic thrombocytopenic purpura (TTP), is characterized by the triad: microangiopathic hemolytic anemia, microvascular occlusion and thrombocytopenia⁽¹⁾; and due to the similarity of the clinical manifestations, in the past, they were considered one single disease⁽²⁾. TTP is associated with fever and neurological signs, although both are clinically indistinguishable. The clinical suspicion in favor of TTP or HUS is due to the presence of neurological changes or acute kidney injury, respectively. Differential diagnosis should be performed with disseminated intravascular coagulation (DIC) and consumptive thrombohemorrhagic diseases⁽³⁾. Despite the great clinical and histological similarity between TTP and HUS, the diagnosis must be performed, since both present independent and differentiated treatment and evolution⁽⁴⁾.

The diagnostic criteria for previously defined microangiopathic hemolytic anemia were based on the presence of: 1) microangiopathic hemolytic anemia; 2) thrombocytopenia; and 3) organic disorders without signs of DIC⁽⁵⁾; these are detailed in the **Table**. In TTP, the intermittent formation of microthrombi and its deposition in the SNC are characterized by fluctuating neurological conditions, predominantly in adulthood⁽²⁾, incidence of 3.7 cases per 1,000,000 inhabitants⁽⁶⁾ and peak in the third decade of life with the female/male ratio of 3:2⁽²⁾.

TABLE – Diagnostic criteria

Diagnostic criteria	Confirmation
1. Microangiopathic hemolytic anemia	1.1. Hemoglobin < 12 g/dl + reticulocytosis
	1.2. Negative test
	1.3. Histology with two or more schistocytes per field
	1.4. Increase of LDH
2. Thrombocytopenia	2.1. Platelet count < 100 × 10 ⁹ /l
3. Variable organic dysfunction	3.1. Neurologic and renal changes with no signs of DIC

LDH: lactate dehydrogenase; DIC: disseminated intravascular coagulation.

The etiopathogenesis of TTP is mainly based on the deficiency or inhibition, congenital or acquired, of a metalloproteinase responsible for the degradation of the von Willebrand factor (vWF) polymers, called multimers. The acquired form can be explained by the presence of immunoglobulin class G (IgG) anti-metalloproteinase antibodies; the congenital form is a consequence of the mutation in the *ADAMTS-13* gene (a disintegrin and metalloproteinase with eight thrombospondin-1-like), leading to enzymatic deficiency⁽⁷⁾. Endothelial dysfunction is the key pathophysiological element for the occurrence of microangiopathy, resulting in microvascular thrombosis with formation of fibrin and inhibition of fibrinolysis⁽⁸⁾. Several etiologic agents may be involved, such as viruses, bacterial toxins and drugs, such as antiplatelet agents and cyclosporine⁽⁹⁾.

The laboratory profile shows hemolytic anemia with hemoglobin values between 7-9 g/dl, platelet count below 30,000/mm³, mildly elevated indirect hyperbilirubinemia and a significant increase in lactate dehydrogenase (LDH); clotting tests are usually within normal range. The identification of schistocytes in the peripheral blood smear associated with the compatible clinical-laboratory scenario is fundamental for the diagnosis of TTP, in addition to being strongly suggestive⁽¹⁰⁾.

TTP can be classified according to its forms of presentation in: primary – acute, chronic recurring, plasmapheresis-resistant, familial; and secondary – pregnancy-related, human immunodeficiency virus (HIV), autoimmune diseases, neoplasia or chemotherapy, immunosuppression or drug use. Among the primary forms, acute is classically manifested by microangiopathic hemolytic anemia, thrombocytopenia, with fever, neurological and renal and dysfunction and purpura in up to 90% of cases. The neurological condition may manifest at any time, such as confusional states, changes in the visual field, sensory and motor deficits, seizures, and lowered level of consciousness. Renal dysfunction manifests with proteinuria and microscopic hematuria and transient acute kidney injury^(2,4).

TTP treatment consists of plasmapheresis, favoring enzymatic action by removing pathogenic autoantibodies and cytokines with endothelial action⁽¹¹⁾, with a change in mortality from 90% to 10%-30%⁽¹²⁾. In severe acute or recurrent/resistant cases, the association of corticosteroids, immunosuppressants and splenectomy may be indicated. Recently, the monoclonal antibody rituximab has been reported as a therapeutic option for cases of TTP resistant to plasmapheresis^(13,14).

Plasmapheresis is essential for all patients diagnosed with TTP, but the number of sessions for clinical-laboratory remission varies⁽¹²⁾. The guidelines found in the literature for acute cases are

daily sessions until normalization of platelet count and LDH level, markers of the therapeutic response⁽¹⁵⁾.

CASE REPORT

Female patient L. B. S., 41 years old, without comorbidities, sought emergency room care referring to weakness and malaise for months, worsening within five days; at that time she presented generalized bone pain, headache, visual alteration and a convulsive episode. At physical examination, she was in a regular general state, lucid and oriented, pale, hydrated, anicteric, acyanotic and afebrile. Cardiac and pulmonary auscultation and abdominal examination with no abnormalities; well perfused extremities, with no edema and no signs of venous thrombosis.

Laboratory tests order entry results: hemoglobin 4.9 g/dl with schistocytes and dacrocytes (**Figures 1 and 2**), leukocytes 2,600/mm³, reticulocytes 0.7%, platelets 53,000/mm³, creatinine 0.7 mg/dl, urea 20 mg/dl, total bilirubin 1.63 mg/dl, indirect

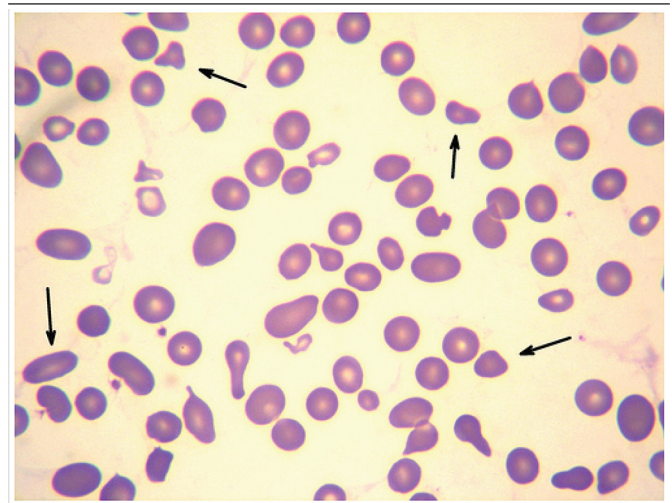


FIGURE 1 – Peripheral blood smear showing presence of schistocytes (400×)

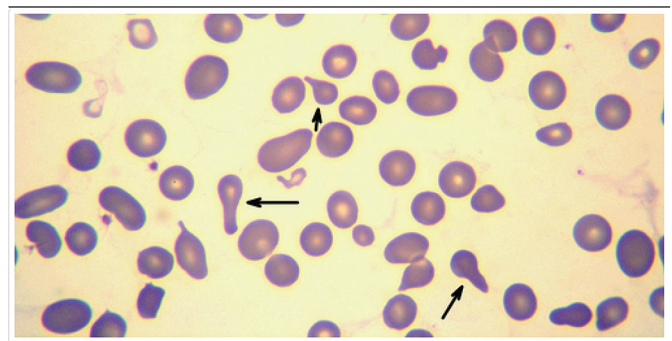


FIGURE 2 – Peripheral blood smear showing presence of dacrocytes (400×)

bilirubin 1.07 mg/dl, LDH 3,325 UI/l, antinuclear factor, direct Coombs, indirect Coombs and serology for HIV negative. The diagnosis in peripheral blood smear was analyzed and confirmed on slide under optical microscopy. The photomicrographs were performed in Zeiss® microscope, Primo Star model, trinocular, coupled to a Sony® digital camera model Cybershot DS1. The images were edited using the ImageJ® software.

In the presence of pancytopenia with etiology to clarify, the patient was hospitalized for investigation and clinical support. She initially received transfusion of two red blood cell concentrates (packed RBC). She performed complete ultrasound of the abdomen, magnetic resonance imaging (MRI) and intracranial magnetic resonance angiography with no abnormalities. The criteria for diagnosis of microangiopathic hemolytic anemia (TTP) were then fulfilled. The patient received every 8 hours 300 ml transfusion of fresh frozen plasma (FFP) and packed RBC as needed and 300 mg hydrocortisone. She was admitted to the intensive care unit (ICU) to perform therapeutic plasmapheresis, with the first session eight days after her arrival at the emergency room. During the fifth, sixth and seventh plasmapheresis sessions, she presented neuropsychiatric fluctuation with mood alteration, disorientation, psychomotor agitation and aggressive behavior, symptoms controlled with haloperidol 10 mg, quetiapine 25 mg and midazolam 3 mg.

Figures 3, 4 and 5 show the laboratory evolution of the patient regarding the respective values of hemoglobin, platelets and LDH during the 32 days of hospitalization. Point 9 in Figures 3 and 4 and point 2 in Figure 5, represent four days after the first plasmapheresis session. Nine packed RBC units, 185 FFP pockets and 13 plasmapheresis sessions were administered for assuming the disease (platelets 163,000/mm³, LDH 232 UI/l and hemoglobin 10.8 g/dl) and the hospital discharge planning. At this time, the patient was referred for follow-up at the hematology outpatient clinic with prescription of prednisone 60 mg and folic acid 5 mg daily.

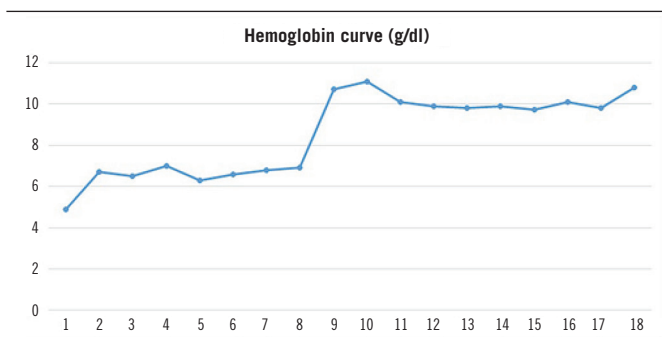


FIGURE 3 – Variation of hemoglobin concentration (g/dl) during hospital stay (g/dl)

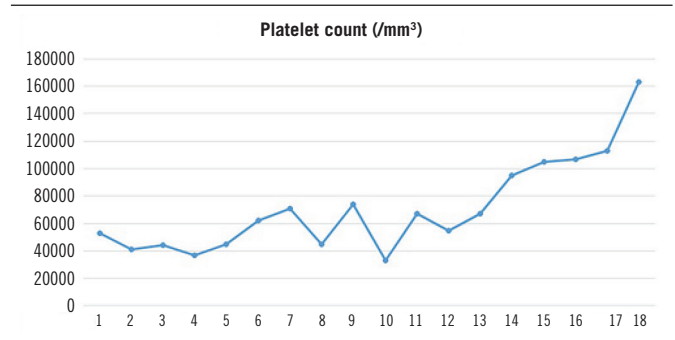


FIGURE 4 – Variation of platelet count during hospital stay

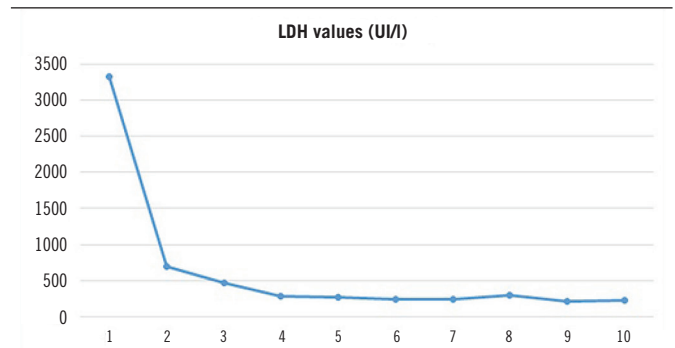


FIGURE 5 – Variation of LDH values (UI/l) during hospital stay

LDH: lactate dehydrogenase.

DISCUSSION

Microangiopathic hemolytic anemia (TTP and HUS) is a rare, serious and potentially fatal condition, but present a recognized effective treatment⁽¹⁶⁾. However, the therapeutic success is directly related to the rapid diagnosis enabled by the simplification of its criteria, without delay the specific therapy establishment^(12,16).

The recently considered diagnostic criteria are the presence of thrombocytopenia and microangiopathic hemolytic anemia confirmed by the identification of schistocytes in the peripheral blood^(12, 16), initially disregarding a probable etiology⁽¹²⁾ and the presence of organ dysfunction and fever, since the pentad classic is quite unusual⁽¹⁶⁾.

In this present case report, the clinical diagnostic criteria for TTP are completely fulfilled, including the neurological manifestation before and during the hospital stay. The specific therapy – plasmapheresis, FFP transfusion and immunosuppression with hydrocortisone – was initiated on the third day after diagnostic confirmation. Therapeutic plasma exchange is the association between plasmapheresis and FFP transfusion, since plasmapheresis

removes the vWF multimers, *ADAMTS-13* antimitalloproteinase antibodies^(4,12) and endothelial cytokines⁽¹¹⁾. FFP transfusion restores the *ADAMTS-13* deficiency with donor enzymes^(4,12).

According to several authors, the use of immunosuppressive agents offers additional action in the treatment of TTP, especially in severe acute or the plasmapheresis-resistant cases^(13, 14, 17) or when autoimmune disease is suspected⁽¹⁸⁾. In a prospective study, prednisone at a dose of 200 mg/day was shown to induce complete remission in 55% of cases of microangiopathic hemolytic anemia associated with mild neurological dysfunction⁽¹⁹⁾.

There is no defined treatment time in the literature, but the authors indicate that therapy should be sustained until the platelet count reaches 100,000/mm³ and the LDH levels are below 400 UI/l, and these are the most sensitive markers for evaluate the therapeutic response⁽²⁰⁾. In this case, hemoglobin and LDH values improved significantly after 72 hours from the start of Plasma Exchange (hemoglobin: 4.9 g/dl to 10.7 g/dl and LDH: 3,325 UI/l to 699 UI/l), but the platelet count only reached acceptable values after 12 days of treatment.

There is a consensual doubt in the literature about the complete remission of the disease in the long term⁽²¹⁾, but in this case, the patient was discharged from hospital with laboratory values within the parameters previously defined (platelets 163,000/mm³ and LDH 232 UI/l). Keeping corticosteroids administration can support complete remission of the disease and outpatient follow-up is essential to monitor remission or detect recurrent chronic form, with mortality rate around 15%⁽²²⁾.

CONCLUSION

This is a serious disease, which diagnosis and the early establishment of the therapy is capable of improving the prognosis, including the possibility of cure. Therefore, every physician who provides assistance in the emergency room units should be aware of it. The possibility of the wide differential diagnosis with conditions also serious, such as consumption coagulopathy and intravascular hemolysis, evidences the need for efficient daily clinical practice.

RESUMO

Púrpura trombocitopênica trombótica (PTT) é uma síndrome hemorrágica grave caracterizada por trombocitopenia, anemia hemolítica microangiopática e oclusão microvascular, bem como por sintomas associados que podem ou não estar presentes, como febre, comprometimento neurológico variável e comprometimento renal. A fisiopatologia implicada na doença envolve a deficiência, seja por inibição autoimune ou defeito genético, seja pela atividade de uma metaloproteínase (ADAMTS-13), responsável pela clivagem de multímeros do fator de von Willebrand (FvW). O tratamento consiste na plasmaférese e, em casos agudos graves ou recorrentes, associa-se a corticoterapia e imunossuppressores. Neste artigo, abordaremos um relato de caso sobre essa doença, cuja paciente foi atendida inicialmente em pronto-socorro, sendo em seguida internada em uma unidade de terapia intensiva (UTI) de um hospital público de referência da cidade de São Paulo, Brasil. Todos os critérios clínicos diagnósticos foram completamente preenchidos, facilitando a abordagem terapêutica da paciente. O relato evidencia que a rápida intervenção, quando se faz o diagnóstico precoce, evolui com bom prognóstico, devendo esta patologia estar presente como diagnóstico diferencial no cotidiano médico.

Unitermos: púrpura trombocitopênica trombótica; anemia hemolítica; plasmaférese.

REFERENCES

1. Moake JL. Thrombotic microangiopathies. *N Engl J Med.* 2002; 347: 589-600.
2. Neild GH. Haemolytic-uraemic syndrome in practice. *Lancet.* 1994; 343: 398-401.
3. George JN. Clinical practice. Thrombotic thrombocytopenic purpura. *N Engl J Med.* 2006; 354: 1927-35.
4. Moake JL. Haemolytic-uraemic syndrome: basic science. *Lancet.* 1994; 343: 393-7.
5. Wada H, Wakita Y, Nakase T, et al. Increased plasmasoluble fibrin monomer levels in patients with disseminated intravascular coagulation. *Am J Hematol.* 1996; 51: 255-60.
6. Torok TJ, Holman RC, Chorba TL. Increasing mortality from thrombotic thrombocytopenic purpura in the United States – analysis of national mortality data, 1968-1991. *Am J Hematol.* 1995; 50: 84-90.

7. Levy GG, Nichols WC, Lian EC, et al. Mutations in a member of the ADAMTS gene family cause thrombotic thrombocytopenic purpura. *Nature*. 2001; 413: 488.
8. Wayne L, Chandler WL, Jelacic S, Boster D. Prothrombotic coagulation abnormalities preceding the hemolytic uremic syndrome. *N Engl J Med*. 2002; 346: 23-32.
9. Tsai HM, Rice L, Sarode R, Chow TW, Moake JL. Antibody inhibitors to von Willebrand factor metalloproteinase and increased binding of von Willebrand factor to platelets in ticlopidine-associated thrombotic thrombocytopenic purpura. *Ann Intern Med*. 2000; 132: 794-9.
10. Hogg R, Watkins S, Tarr P. Molecular determinants in diarrhea-associated hemolytic uremic syndrome (D+HUS). A report of the southwest pediatric nephrology study group (SPNSG). *Nephrol Dial Transpl*. 2003; 18: 529.
11. Sadler JE, Moake JL, Miyata T, George JN. Recent advances in thrombotic thrombocytopenic purpura. *Hematology Am Soc Hematol Educ Program*. 2004; 407-23.
12. Rock GA, Shumak KH, Buskard NA, et al. Comparison of plasma exchange with plasma infusion in the treatment of thrombotic thrombocytopenic purpura. Canadian Apheresis Study Group. *N Engl J Med*. 1991; 325: 393-7.
13. Neto CA, Mendonça MC, Braga MC, et al. Púrpura trombocitopênica trombótica – remissão completa em paciente com mau prognóstico após tratamento com plasmáfêrese terapêutica e rituximabe. *Rev Bras Hematol Hemoter*. 2008; 30: 71-4.
14. George JN, Woodson RD, Kiss JE, Kojouri K, Vesely SK. Rituximab therapy for thrombotic thrombocytopenic purpura: a proposed study of the Transfusion Medicine/Hemostasis Clinical Trials Network with a systematic review of rituximab therapy for immunemediated disorders. *J Clin Apher*. 2006; 21: 49-56.
15. Thorpe CM, Hurley BP, Lincicome LL, et al. Shiga toxins stimulate secretion of interleukin-8 from intestinal epithelial cells. *Infect Immun*. 1999; 67: 5985-93.
16. Pessegueiro P, Pires C. Síndrome hemolítico urémico/púrpura trombocitopênica trombótica. *Med Int*. 2005; 12: 102-16.
17. Vesely SK, George JN, Lämmle B, et al. ADAMTS-13 activity in thrombotic thrombocytopenic purpura-hemolytic uremic syndrome: relation to presenting features and clinical outcomes in a prospective cohort of 142 patients. *Blood*. 2003; 101: 60-8.
18. Cataland SR, Jin M, Ferketich AK, et al. An evaluation of cyclosporine and corticosteroids individually as adjuncts to plasma exchange in the treatment of thrombotic thrombocytopenic purpura. *Br J Haematol*. 2007; 132: 146-9.
19. Bell WR, Braine HG, Ness PM, Kickler TS. Improved survival in thrombotic thrombocytopenic purpura-hemolytic uremic syndrome. Clinical experience in 108 patients. *N Engl J Med*. 1991; 325: 398-403.
20. Ismail N, Neyra R, Hakim RM. Plasmapheresis. In: Daugirdas JT, Blake PG, Ing TS, editors. *Handbook of Dialysis*. 3 ed. Philadelphia: Lippincott Williams & Wilkins; 2001. p. 231-62.
21. Patton JF, Manning KR, Case D, Owen J. Serum lactate dehydrogenase and platelet count predict survival in thrombotic thrombocytopenic purpura. *Am J Hematol*. 1994; 47: 94-9.
22. George JN. The thrombotic thrombocytopenic purpura and hemolytic uremic syndromes: evaluation, management, and long-term outcomes experience of the Oklahoma TTP-HUS Registry, 1989-2007. *Kidney Int*. 2009; 112: 52-4.

CORRESPONDING AUTHOR

João Paulo Nunes Drumond

Rua Professor Enéas de Siqueira Neto, 340; Jardim das Imbuías; CEP: 04829-300; São Paulo-SP, Brasil; Phone: +55 0800 171796; e-mail: jpn@uai.com.br



This is an open-access article distributed under the terms of the Creative Commons Attribution License.