

Case report of staghorn calculus in a pediatric patient

Relato de caso de cálculo coraliforme em paciente pediátrico

Isadora E. Silva¹; Gabriela C. Abreu¹; Wagner M. Moura¹; Débora C. Cerqueira^{1,2}; Cinthia A. C. Leandro¹

1. Centro Universitário de Belo Horizonte, Belo Horizonte, Minas Gerais, Brazil. 2. Hospital São Camilo, Belo Horizonte, Minas Gerais, Brazil.

ABSTRACT

This article reports a case of large volume asymptomatic staghorn calculus, and a brief revision of this rare pathology is done. A two-year-old male patient was diagnosed with staghorn calculus and hydronephrosis in the left kidney. The patient underwent surgical therapy with pyelolithotomy, pyeloplasty and placement of a double-J catheter, without complications. Staghorn calculi occupy the pelvis and renal calyces. Their incidence in children is lower than in adults. The average age at diagnosis is between 7 and 10 years. The etiology for calculi is diverse; in children under 4 years, it is especially related with infectious factors and hydronephrosis. The standard procedure for treatment is percutaneous nephrolithotomy.

Key words: hydronephrosis; urolithiasis; staghorn calculi.

RESUMO

Este relato ilustra um caso de cálculo do tipo coraliforme de grande volume, assintomático, acompanhado de uma revisão dessa grave patologia. Relatamos o caso de um paciente do sexo masculino, dois anos de idade, diagnosticado com cálculo coraliforme e hidronefrose em rim esquerdo. Instituiu-se terapêutica cirúrgica, com realização de pielolitotomia, pieloplastia e colocação de cateter duplo-J sem intercorrências. Cálculo renal coraliforme ocupa a pelve e os cálices renais. Sua incidência é menor em crianças, sendo a média de diagnóstico entre 7 e 10 anos. A etiologia é ampla; em menores de 4 anos, relaciona-se especialmente com fatores infecciosos e hidronefrose. O tratamento padrão é a nefrolitotomia percutânea.

Unitermos: hidronefrose; urolitíase; cálculos coraliformes.

RESUMEN

Presentamos un caso de cálculo del tipo coraliforme de gran volumen, asintomático, y una revisión de esa enfermedad grave. Reportamos el caso de un paciente masculino, de dos años de edad, diagnosticado con cálculo coraliforme e hidronefrosis en riñón izquierdo. Se realizó tratamiento quirúrgico, a base de pielolitotomía, pieloplastia y colocación de un catéter doble J, sin complicaciones. El cálculo coraliforme ocupa la pelvis y los cálices renales. Su incidencia es menor en niños, con media de 7-10 años en el diagnóstico. La etiología es diversa; en menores de 4 años, se refiere específicamente a factores infecciosos e hidronefrosis. El tratamiento estándar es la nefrolitotomía percutánea.

Palabras clave: hidronefrosis; urolitiasis; cálculos coraliformes.

INTRODUCTION

Staghorn calculi are a specific type of lithiasis in which the calculus occupies the pelvis and renal calyces, taking the form of a corals^(1,2). They present larger number of reports in women and are generally unilateral⁽³⁾. Worldwide, around 5%-10% will suffer with nephrolithiasis in any period of life; among those cases, 2%-2.7% will be children^(1,4).

Staghorn nephrolithiasis characterizes as a disease of rapid growth that, if not treated, will possibly evolve to destruction of the affected kidney and sepsis^(2,5). In the pediatric patient, the clinical picture of the disease can be non-specific, what requires much attention, because just a minority will clinically exteriorize the urinary calculus as a classical renal colic⁽⁶⁾.

Considering its significant morbidity and mortality, this disease demands early evaluation and treatment⁽⁷⁾. The gold standard treatment for staghorn calculi is surgery and aims at obtaining a stone-free collecting system, besides preserving renal function⁽⁸⁾. Percutaneous nephrolithotomy (PCNL) is the treatment of choice for staghorn calculi with the best treatment rates⁽⁸⁾.

REPORT OF THE CLINICAL CASE

A 2-year-old male pre-term infant (36 weeks), small for gestational age – labor induced due to maternal urinary infection, what led to a cesarean labor. The patient presented no symptoms at a routine visit. As a habitual medical conduct, a urine test was ordered, what revealed urinary infection caused by *Proteus mirabilis*. Because of that result, an ultrasonography (US) was ordered of kidneys and urinary tract, which revealed normally positioned kidneys with usual contours and preserved corticomedullary ratio. The left kidney was enlarged in its general size (70.4 × 38.5 × 28.7 mm) in comparison with the right kidney (67.8 × 29.3 × 23.8 mm) (**Figure 1**). In the distal mid third of the left kidney, we identified the presence of confluent hyperechogenic structures, which caused posterior acoustic shadowing, generating segmental dilatations of calyceal structures. Based on the alteration in the test, the patient was referred to a pediatric nephrologist. Tests were performed for assessment of metabolic disorders, such as hypercalciuria and hypocitraturia, with urine measurements: citrate/creatinine ratio = 1.11; and calcium/creatinine ratio = 0.39, both normal for the patient age group. Renal US and urodynamic tests were also conducted, with no evidence of alterations in the kidney and urinary tract in the

right side of the patient's body. On the other hand, the left kidney presented a hyperechogenic structure with posterior acoustic shadowing following part of the pelvis and calyces of the lower third, compatible with staghorn calculus, measuring 30 × 13 × 8.5 mm in the longest axes (**Figure 2**).

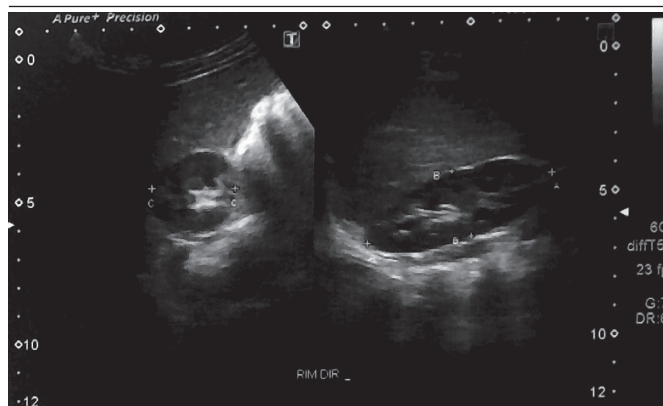


FIGURE 1 – Dynamic US of the right kidney showing kidney size

US: ultrasonography.

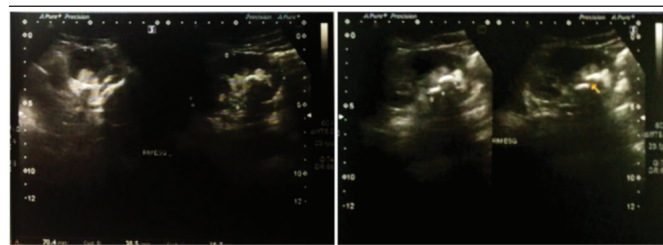


FIGURE 2 – Dynamic US of left kidney showing kidney size and staghorn calculus (yellow arrow) size

US: ultrasonography.

A mild dilatation of renal pelvis and the other calyces was noted, both majors and minors. The ipsilateral ureter presented normal caliber in the proximal portion and it was slightly increased in the distal, with absent calculi. The examination showed the right kidney with normal echography size and aspect, while the left kidney size revealed normal parenchyma and staghorn calculus, with mild dilatation of the pyelocalyceal system and distal ureter. The bladder contained debris, what could correspond to crystalluria, hematuria, or pyuria.

In order to complement the clinical propedeutics and treatment definition, a computed tomography (CT) was suggested of abdomen and pelvis. That exam revealed kidneys of usual shape, contours and size, as well as the presence of a staghorn calculus to the left with density of 1147 UH, measuring

26 × 19 mm in the pelvis and in the lower calyceal group. It also identified the presence of hydronephrosis on the left and the bilateral dilatation of the ureters, greater on the left, measuring about 7 mm in the anterior-posterior (AP) diameter, without signs of ureterolithiasis. The other abdominal and pelvic hollow organs evaluated presented with the usual characteristics (**Figure 3**). The dynamic renal scintigraphy revealed high obstruction to the left, with diagnosis of ureteropelvic junction stenosis (**Figure 4**).

The definitive conduct was pyelolithotomy, followed by pyeloplasty and surgical placement of a double-J catheter unilaterally. The patient evolved well postoperatively, remaining asymptomatic during chemoprophylaxis, with an isolated episode of hematuria.

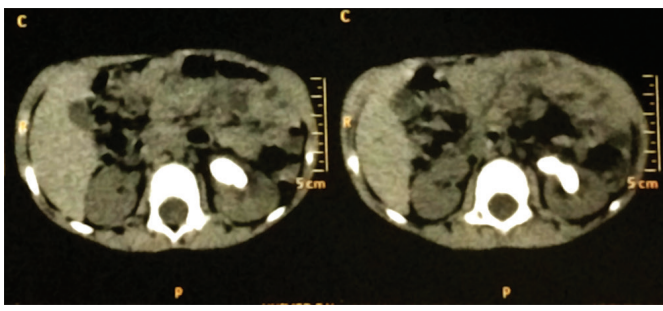


FIGURE 3 – CT scan of abdomen and pelvis showing hyperintense mass in the left kidney
CT: computed tomography.

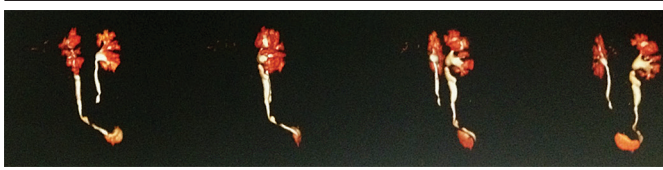


FIGURE 4 – Dynamic renal scintigraphy showing upper urinary tract obstruction to the left

DISCUSSION

Nephrolithiasis is a very prevalent affection whose incidence has been increasing lately⁽⁹⁾. Renal calculi can be staghorn-type or non-staghorn type. The former is that which occupies renal pelvis and extends, at least to two calyceal groups. Its constitution is variable: it can be formed of calcium oxalate, uric acid, cystine, and struvite⁽¹⁰⁾.

Struvite staghorn calculi are composed of magnesium, ammonium, and phosphate and are closely related to urinary tract infections (UTI)⁽¹¹⁾. The infections that mostly associate to the pathogenesis of staghorn calculi are those caused by organisms producing the urease enzyme, promoting the generation of ammonia and hydroxide from urea such as *Proteus*, *Klebsiella*, *Pseudomonas* and *Staphylococcus*⁽¹¹⁾. This relationship occurs because of the dependent coexistence of pH 7.2 and ammonia for the crystallization of struvite in urine⁽¹²⁾. There is another mechanism for which UTI can induce the formation of those calculi: association with increased adherence of crystals; yet, this thesis is still not fully clarified. Such a hypothesis justifies the fact that *Escherichia coli* is related to 13% of the struvite calculi⁽¹³⁾, although that bacterium causes 85%-90% of UTIs⁽¹⁴⁾.

Staghorn calculi are uncommon in the pediatric population and pose challenges and singular difficulties for surgical treatment⁽¹⁵⁾. This illness can occur in patients of any age, with the mean age at diagnosis among children being 7-10 years⁽⁴⁾. Those calculi represent a substantial concern, as the combination of infection and the increased potential obstruction can induce damage to renal parenchyma⁽¹⁵⁾.

Around 75%-85% of children with urolithiasis present risk factors, such as metabolic disorders, recurrent infections and/or congenital abnormalities of the urinary tract⁽¹¹⁾. Staghorn calculus, in its turn, is associated with delay in diagnosis and treatment of UTI. This happens because the recognition of these infections in the child can be difficult, as symptoms are non-specific or absent, especially in infants. In this group, fever is the main manifestation and many times the only sign⁽⁶⁾.

When diagnosis of urinary lithiasis is made due to a casual finding, the metabolic study of the patient must be conducted, because it is a risk factor for the development of urolithiasis. In the presence of this occasional finding in the reported patient, we continued with metabolic investigation, which did not show significant results. Besides, one must readily evaluate and treat nephrolithiasis⁽²⁾, especially due to the importance and the severity of staghorn calculus. Removal, eradication of infection, correction of eventual metabolic disorders and anatomical abnormalities causing urinary stasis are the bases for treatment. This can be clinical, interventional, or demand association of other therapies. The clinical approach must be considered in combination with surgery for those patients with prohibitive^(1,8) surgical risk, because conservative treatment presents a mortality rate of 28% in 10 years and 36% risk of developing severe kidney failure⁽⁸⁾.

The interventional treatment includes extracorporeal lithotripsy (ECL), endoscopic lithotripsy using US, open pyelolithotomy and PCNL. The conduct is chosen according to the calculus location and its effects upon the kidneys⁽⁶⁾. Moreover, decision must be individualized, considering aspects related to the age and health status of each patient⁽⁸⁾.

With the development of minimally invasive surgeries, the number of open surgeries decreased, especially in pediatric patients. At a large series, PCNL for treatment of staghorn calculus revealed rates of partial and complete removals of 98.5% and 71%, respectively⁽¹⁶⁾. In spite of the high popularity of this surgical technique, there are just two randomized clinical essays that assess its therapeutic value and prove the superiority of PCNL over ELC, so that the first is recommended as the preferential treatment for struvite staghorn calculi⁽⁸⁾.

Pyeloplasty is the indicated treatment for correction of ureteropelvic junction stenosis. Such stenosis is characterized as the ureter narrowing in its cranial portion, close to the renal pelvis, which, by causing urinary stasis, can develop to progressive hydronephrosis. Pictures of hydronephrosis are nor

rare in children and, in their majority, occur due to congenital uropathies⁽¹⁷⁾. Pyelolithotomy is the removal of calculus by means of an incision in the posterior face of the renal pelvis. This practice became obsolete after the appearance of ELC and PCNL. However, in the case of our patient, the adoption of these procedures was not possible.

Although nowadays open surgery is not frequently used, it is recommended for complex cases. Among its indications for the treatment of urinary lithiasis, the main recommendations are cases of large staghorn calculi in patients with complex collecting systems⁽¹⁸⁾, as the described clinical case. Its morbidity is related to the incision, surgical infection, and vascular and parenchymal lesions, which can cause renal atrophy⁽¹⁸⁾. Ureteral obstruction is a frequent complication in renal surgeries due to local inflammation that can occur with adherence of ureteral walls. For such, the insertion of a double-J catheter⁽¹⁹⁾ is indicated.

The adequate and early treatment is directly associated with the maintenance of renal function; therefore, the information presented here is very useful to avoid complications, such as kidney failure in children.

REFERENCES

- Horuz R, Sarica K. The management of staghorn calculi in children. *Arab J Urol*. 2012; 10(3): 330-5. PubMed PMID: 26558045.
- Preminger GM, Assimos DG, Lingeman JE, et al. AUA guideline on management of staghorn calculi: diagnosis and treatment recommendations. *J Urol*. 2005 Jun; 173(6): 1991-2000. PubMed PMID: 15879803.
- Buchholz NP, Abbas F, Afzal M, et al. The prevalence of silent kidney stones-an ultrasonographic screening study. *J Pak Med Assoc*. 2003; 53: 24-25. PubMed PMID: 12666848.
- Peres LAB, Langer SS, Schmidt RC, et al. Nephrolithiasis in pediatric patients: metabolic and anatomical investigation. *J Bras Nefrol*. 2011 Mar; 33(1): 50-4. PubMed PMID: 21541463.
- Marques JJ, Muresan C, Lúcio R, et al. Litíase coraliforme: caso clínico raro e complicado. *Acta Urológica*. 2011; 4: 58-61. Disponível em: <http://hdl.handle.net/10400.17/675>.
- Penido MGM. Litíase urinária na infância. In: Júnior DC, Burns DAR, Lopez FA. *Tratado de pediatria: Sociedade Brasileira de Pediatria*. 3 ed. Barueri, SP: Manuele; 2014. p. 1685-1696.
- Koga S, Arakaki Y, Matsuoka M, et al. Staghorn calculi-long-term results of management. *Br J Urol*. 1991; 68: 122-4. PubMed PMID: 1884136.
- Diri A, Diri B. Management of staghorn renal stones. *Ren Fail*. 2018; 40(1): 357-62. PubMed PMID: 29658394.
- Korkes F, Silva II JL, Heilberg IP. Costs for in hospital treatment of urinary lithiasis in the Brazilian Public Health System. *Einstein (São Paulo)*. 2011; 9(4): 518-22. PubMed PMID: 26761257.
- Herring LC. Observations of 10,000 urinary calculi. *J Urol*. 1962; 88: 545-7. PubMed PMID: 13954078.
- Krzemień G, Szmigielska A, Jankowska-Dziadk K, Pańczyk-Tomaszewska M. Renal staghorn calculi in small children – presentation of two cases. *Dev Period Med*. 2016; 20(1): 23-6. PubMed PMID: 27416622.
- Gleeson MJ, Griffith DP. Struvite calculi. *Br J Urol*. 1993; 71: 503-11.
- Holmgren K, Danielson BG, Fellström B, Ljunghall S, Niklasson F, Wikström B. The relation between urinary tract infections and stone composition in renal stone formers. *Scand J Urol Nephrol*. 1989; 23(2): 131-6. PubMed PMID: 2667113.
- Malheiros DMAC, Cavalcanti FBC, Testagrossa LA, David DSR. Sistema urinário. In: Brasileiro Filho G, editor. *Bogliolo Patologia*. 8. ed. Rio de Janeiro: Guanabara Koogan; 2011. p. 519-85.
- Schults AJ, Jia W, Ost MC, Oottamasathien S. Combination of extracorporeal shockwave lithotripsy and ureteroscopy for large staghorn calculi in a pediatric patient: case report. *J Endourol Case Rep*. 2017; 3(1): 64-6. PubMed PMID: 28616590.
- Chibber PJ. Percutaneous nephrolithotomy for large and staghorn calculi. *J Endourol*. 1993; 7(4): 293-5. PubMed PMID: 8252021.

17. Yiee J, Wilcox D. Management of fetal hydronephrosis. *Pediatr Nephrol.* 2008; 23(3): 347-53. Epub 2007 Aug 2. PubMed PMID: 17671800.

18. Assimos DG. Anatomic nephrolithotomy. *Urology.* 2001; 57(1): 161-5. PubMed PMID: 11164167.

19. Cavalli AC, Tambara Filho R, Slongo LE, Cavalli RC, Rocha LC. The use of double-J catheter decreases complications of retroperitoneoscopic ureterolithotomy. *Rev Col Bras Cir.* 2012; 39(2): 112-8. PubMed PMID: 22664517.

CORRESPONDING AUTHOR

Gabriela Carvalho Abreu  0000-0002-1331-4135
e-mail: gabrielac.abreu@hotmail.com



This is an open-access article distributed under the terms of the Creative Commons Attribution License.